Washington University School of Medicine
Digital Commons@Becker

Publications | Division of Adult Audiology

2012

Against the odds: Idiopathic sudden sensorineural hearing loss—Results from delayed treatment

Robert Mareing
Washington University School of Medicine in St. Louis

M. Allison Ogden
Washington University School of Medicine in St. Louis

Follow this and additional works at: http://digitalcommons.wustl.edu/audio_hapubs

Recommended Citation
Mareing, Robert and Ogden, M. Allison, "Against the odds: Idiopathic sudden sensorineural hearing loss—Results from delayed treatment" (2012). *Publications*. Paper 22.
http://digitalcommons.wustl.edu/audio_hapubs/22

This Article is brought to you for free and open access by the Division of Adult Audiology at Digital Commons@Becker. It has been accepted for inclusion in Publications by an authorized administrator of Digital Commons@Becker. For more information, please contact engeszer@wustl.edu.

J Am Acad Audiol 23:291–295 (2012)

Case Report

Against the Odds: Idiopathic Sudden Sensorineural Hearing Loss—Results from Delayed Treatment

DOI: 10.3766/jaaa.23.4.8

Robert Mareing*
M. Allison Ogden*

Abstract

A 79-yr-old male was evaluated by the authors 4–6 wk following a rapid decline in perceived hearing in the right ear. Initial treatment with self-administered external ear canal irrigations and topical antibiotic prescribed by the patient's primary care physician resulted in no apparent improvement. The initial hearing evaluation revealed a mild-to-severe sloping sensorineural loss above 1000 Hz in the left ear and a moderately severe to severe sensorineural loss with a "flat" configuration in the right ear. There was normal word recognition in the left ear, with no measurable word recognition in the right ear. Initial treatment with oral steroids suggested some subjective improvement, and an intratympanic dexamethasone injection was performed. A repeat audiogram obtained approximately 1 mo postinjection showed significant improvement in pure tone thresholds and significant improvement in the word recognition score in the right ear. One week later a second intratympanic injection was completed, again, with follow-up in 1 mo. This case report reviews treatment options for idiopathic sudden sensorineural hearing loss (ISSNHL), including usual time lines for treatment and expected outcomes and the specific treatments and evaluation results for this patient for whom delayed treatment was unusually effective.

Key Words: Dexamethasone, idiopathic sudden sensorineural hearing loss, intratympanic injection, steroid, sudden sensorineural hearing loss

Abbreviations: ISSNHL = idiopathic sudden sensorineural hearing loss; IT = intratympanic; MRI = magnetic resonance imaging; NIDCD = National Institute on Deafness and Communication Disorders; SRT = speech recognition threshold; SSNHL = sudden sensorineural hearing loss; WRS = word recognition score

The definition and treatment of sudden sensorineural hearing loss (SSNHL) is a topic of much discussion and of some controversy in audiology and otolaryngology. SSNHL is defined by the National Institute on Deafness and Communication Disorders (NIDCD) as a decline of at least 30 dB HL in three contiguous frequencies over a period of up to 3 days. NIDCD also reports that 90% of all SSNHL occurs unilaterally (NIDCD, 2003). The SSNHL could be a new hearing loss or it could represent an incremental deterioration in an ear with pre-existing hearing loss. In clinical practice, the degree of certainty about the hearing level at presentation compared to the "premorbid" hearing ranges from being very certain, when the patient has a full and documented audiological assessment, to uncertain, due to having only patient report of some pre-existing hearing loss, but with no documentation. SSNHL is characterized by a sudden decline in hearing of cochlear or retrocochlear origin. The cause of SSNHL is most often unknown; however, it can occur due to vestibular schwannoma (Sauvaget et al, 2005), acoustic trauma, Ménière's disease, cochlear hydrops, perilymph fistula, mumps, head injury, multiple sclerosis, meningitis, and other disorders (Mattox and Simmons, 1977). Sudden unilateral sensorineural hearing loss due to anterior inferior cerebellar artery infarction has been also been documented and described (Martines et al, 2011). Evaluation and assessment includes history, physical audiological examination, appropriate laboratory tests, and magnetic resonance imaging (MRI). Absent

*Department of Otolaryngology–Head and Neck Surgery, Washington University in St. Louis School of Medicine

Robert Mareing, Division of Adult Audiology, Department of Otolaryngology–Head and Neck Surgery, Washington University in St. Louis School of Medicine, Campus Box 8115, 660 S. Euclid Ave., St. Louis, MO 63110; Phone: 314-432-4110; Fax: 314-432-8208; E-mail: mareingr@ent.wustl.edu

Delivered by Ingenta to: Washington University School of Medicine Library
IP : 128.252.16.235 On: Mon, 22 Oct 2012 15:43:57

an identified cause, the SSNHL is referred to as idiopathic sudden sensorineural hearing loss (ISSNHL).

Various theories have been postulated to explain ISSNHL, and due to the abrupt onset, vascular interruption (Perlman et al, 1959; Belal, 1979) and viral infection (Cole and Jahrsdoerfer, 1988; Vasama and Linthicum, 2000) have been suggested. Additional theories of explanation of ISSNHL include ischemia of the cochlea (Lin et al, 2008), autoimmune disease, and rupture of Reissner's membrane (Yoon et al, 1990). Of these potential etiologies, those having a vascular basis and those with viral basis have gained popularity.

The incidence of ISSNHL has been estimated to be from 5 to 20 per 100,000 per year (Byl, 1984). More recently, a retrospective cross-sectional study from Taiwan (Wu et al, 2006) estimated the incidence at approximately eight per 100,000 per year. Considering that some number of ISSNHL are not reported due to spontaneous recovery over a short period of time or are simply not reported, the true incidence is likely underestimated in the literature. The rate of spontaneous recovery has been reported to be as high as 65% (Mattox and Simmons, 1977; Vasama and Linthicum, 2000). The majority of spontaneous recoveries occur within 2 wk, with many occurring in the first few days (Mattox and Simmons, 1977). The occurrence at such a relatively high rate of spontaneous recovery and the relatively low incidence of occurrence of ISSNHL presents challenges to researchers and clinicians investigating etiologies and the efficacies of treatments. Importantly, several factors have been reported to have a poor prognosis for hearing recovery, including delay of treatment (Mattox and Simmons, 1977; Byl, 1984; Haynes et al, 2007), age younger than 15 and older than 59 (Byl, 1984), severe vertigo, and severe-profound hearing loss (Mattox and Simmons, 1977; Byl, 1984).

Medical management of patients with ISSNHL is not straightforward, with dilemmas due to spontaneous recovery, heterogeneous pathophysiology of the ISSNHL, and undertreatment and/or delayed treatment. In addition, treatment modalities have varied widely in published studies, further complicating the critical appraisal of treatment efficacy. Several treatments have been used, including antiviral and hemodilution mineral agents, vitamin and herbal preparations, systemic steroids, niacin, histamine, and hyperbaric oxygen (Conlin and Parnes, 2007). More recently, intratympanic (IT) steroid injections have been used (Hu and Parnes, 2009). The most generally accepted treatment in North America is systemic steroids (Chandrasekhar, 2003; Haynes et al, 2007). The efficacy of systemic steroid therapy was established in several trials (Wilson, 1980; Moskowitz et al, 1984). However, other studies have questioned this finding (Cinamon, 2001; Conlin and Parnes, 2007), and a recent Cochrane review concluded that the effectiveness of steroids for treatment of ISSNHL is unclear based upon a critical appraisal of the currently available studies (Wei et al, 2006).

Due to the known risks associated with short- or long-term systemic steroid therapy, such as immune suppression, weight gain, osteoporosis, avascular necrosis of the hip, mood swings, and skin and endocrine changes, IT steroids are becoming increasingly used in the United States. Similar to other treatments, there is great variability between treatment regimens; however, use of IT steroids has evolved into three primary approaches for treatment of ISSNHL: initial or primary treatment for ISSNHL without systemic steroids; adjunctive treatment given concomitantly with systemic steroids for ISSNHL; and as "salvage therapy" after failure of systemic steroids for ISSNHL (Haynes et al, 2007). IT steroid injection offers many advantages relative to systemic steroid therapy, including ease of application, that it is well-tolerated, and avoidance of potential risks and side effects seen with systemic steroid therapy. The risks of IT injection are uncommon (tympanic membrane perforation, further hearing loss, acute otitis media) and/or transient (vertigo, pain) (Haynes et al, 2007; Seggas et al, 2011).

Haynes et al (2007) retrospectively reviewed 40 patients who underwent IT steroid injection for ISSNHL after failing to improve with initial systemic steroid therapy. Using 20 dB pure tone average (PTA) (three-frequency) or 20% word discrimination improvement as a successful result, 39% demonstrated improvement if treated within 6 wk of the start of the ISSNHL. No patient receiving dexamethasone injections after 36 days recovered hearing, using the 20 dB/20% criteria.

Tsai et al (2011) performed a retrospective study of 128 subjects who received IT steroid treatment. Patients who received IT therapy within 7 days of disease onset had a significantly higher response (76%) when compared to patients who received more delayed treatment (58%). The authors also found greater improvement in the low and midfrequencies (250, 500, and 1000 Hz) than at higher frequencies (2000 and 4000 Hz).

A recent prospective clinical trial (Fu et al, 2011) evaluated 66 subjects with sudden profound unilateral sensorineural loss of less than 2 weeks duration. All subjects received a 9 day course of intravenous steroids, a 7 day course of Prostaglandin E1 intravenous infusion, and 30 days of hyperbaric oxygen therapy. Following this therapy regimen, subjects were offered additional IT therapy. Twenty-two subjects elected IT steroid therapy, and 44 declined (control group). Audiograms obtained prior to treatment and 30 days post-treatment revealed a 30 dB or greater recovery rate of 77.27% for the IT group and 81.81% for the control group (nonsignificant); however, examination of data reported by the authors suggests 5–10 dB greater improvement in the IT group than the control group in the primary speech frequencies (500, 1000, and 2000 Hz).

A thorough review of literature regarding IT steroid treatment was undertaken by Hu and Parnes (2009).

Delivered by Ingenta to: Washington University School of Medicine Library
IP : 128.252.16.235 On: Mon, 22 Oct 2012 15:43:57

However, due to the heterogeneous nature of the studies, a meta-analysis was unable to be performed, and no conclusions could be made regarding the effectiveness of IT steroid injection therapy for ISSNHL. Recommendations were made for more rigorously designed studies. Another recent literature review remarked upon the same concerns of the quality and variability of available research (Seggas et al, 2011). This researcher, however, drew guarded conclusions, based on general results rather than rigorous methodological analysis, favoring the use of IT steroids in refractory ISSNHL and as an initial therapy, as well as in patients unable to use systemic steroids (Seggas et al, 2011).

CASE PRESENTATION

A 79-yr-old male presented to the Department of Otolaryngology–Head and Neck Surgery at Washington University in St. Louis School of Medicine with report of rapid unilateral hearing decline in his right ear approximately four to six weeks prior to presentation at this clinic, which he attributed to excess cerumen. Due to this assumption, he self-irrigated with warm water. When the hearing loss remained, the patient was evaluated by his primary care physician and placed on Ciprofloxacin Otic drops. There was no noticeable improvement in hearing. He did not experience pain, bleeding, or vertigo associated with the hearing loss, canal irrigations, or topical antibiotic treatment. He had intermittent bilateral tinnitus for many years; however, the tinnitus in the right ear became more pronounced with the onset of the hearing loss. The patient reported a history of significant noise exposure while growing up on a farm and lifelong exposure to noise with large machinery and equipment.

In the month prior to the decline in hearing, he developed pneumonia with chest pain and shortness of breath. He was treated with oral antibiotics, and his symptoms resolved completely prior to his appointment in our office. His past medical history includes hypertension, acid reflux, hypothyroidism, and coronary artery disease. His regular medications were esomeprazole, metroprotol, and levothyroxine. His family history is notable for coronary artery disease (father), deep vein thrombosis (DVT) (mother), and brain tumor (sister).

The initial audiogram at presentation revealed normal hearing 250–500 Hz and a mild-to-severe, moderately sloping sensorineural loss above 1000 Hz in the better, left ear. The right ear revealed a severe sensorineural loss with relatively "flat" configuration from 250 to 2000 Hz, with a sharply sloping profound loss above 2000 Hz (Fig. 1). Speech audiometry in the left ear revealed a speech recognition threshold (SRT) of 15 dB HL and a word recognition score (WRS) of 100%, obtained using recorded NU-6 materials, full-list, female talker. In the right ear an SRT could not be measured; however, a speech awareness threshold (SAT) of 65 dB HL was obtained and was in good agreement with the pure tone findings. Word recognition was not evaluated in the right ear. Immittance audiometry revealed normal tympanograms, tympanic membrane compliance, middle-ear pressures, and physical volume test (PVT), bilaterally. Ipsilateral acoustic reflex thresholds were present at normal levels in the left ear and absent in the right ear. Otologic examination was normal, bilaterally. The remainder of the patient's head and neck examination was unremarkable. The findings from a comprehensive metabolic panel (CMP) from the prior month and complete blood count (CBC) and basic metabolic panel (BMP) from the current month were all normal. An MRI study was obtained and reported small vessel disease and no retrocochlear pathology. The initial impression was of likely sudden sensorineural loss in the right ear occurring 4-6 wk prior to presentation that was superimposed upon prior high-frequency sensorineural loss consistent with his history of noise exposure and presbycusis.

The patient was placed on a course of oral steroid (prednisone) taper and, in a follow-up appointment 1 wk later, the patient reported improvement in hearing in the ear. The limited prognosis in regard to further improvement in hearing due to the degree of hearing loss and delay in treatment were discussed, as were the risks of dizziness, discomfort, and possible tympanic membrane perforation from the IT injections. A right IT steroid injection was then undertaken, using 0.3ml of 20mg/ml dexamethasone. For the injection, the patient was placed in a supine position, with the head turned to the left. Using a binocular microscope, Phenol was used to anesthetize the posterior aspect of the tympanic membrane, and a

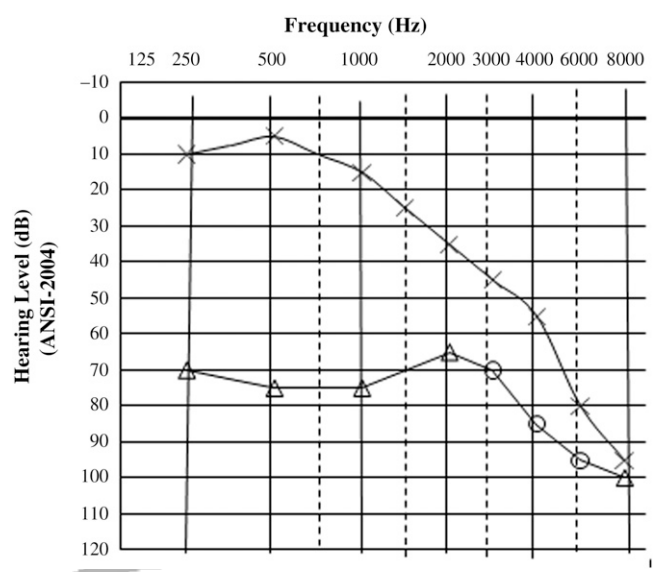

Figure 1. Patient's pretreatment right and left ear pure tone air conduction threshold findings at initial visit.

Delivered by Ingenta to: Washington University School of Medicine Library
IP : 128.252.16.235 On: Mon, 22 Oct 2012 15:43:57

27-gauge needle was used to make two small perforations in this posterior area. The dexamethasone was injected into the middle ear through these perforations, and the fluid was then visible through the tympanic membrane, filling the mesotympanum. The patient was left in the head-turned supine position for 30 min. He was then elevated to sitting, and then standing. There was no vertigo or other discomfort.

At 1 mo follow-up, the patient reported gradual improvement in hearing, to such a degree that he no longer noticed a difference in hearing between ears. The patient continued to have a slight "rushing" tinnitus in the right ear, but he reported that the tinnitus was no longer bothersome. Physical examination found that the right tympanic membrane was intact, with a heaped border surrounding the injection site.

Hearing evaluation revealed improvement in pure tone thresholds of 20 to 45 dB from 500 to 4000 Hz, with 10 and 15 dB improvement at 6000 and 8000 Hz, respectively, as reported in Figure 2.

Speech audiometry revealed an SRT of 40 dB and WRS of 90% in the right ear at 40 dB SL. The SRT was obtained using monitored live voice and a male talker. WRS on the right ear was obtained with a full-list recorded presentation of the NU-6 word lists, using the same female talker, using a different word list.

The patient subsequently underwent a second IT dexamethasone injection 1 wk later and tolerated the procedure well. At 1 mo follow-up, now 4 mo after suspected ISSNHL, the patient reported further subjective improvement in hearing and perceived tinnitus. Results of the hearing evaluation revealed 15 dB additional improvement at 500 and 1000 Hz relative to the second evaluation (Fig. 3), and the SRT in the treated ear was now essentially unchanged, at 40 dB HL. At 40 dB SL, word recognition remained relatively high at 86% using the same talker and a different word list.

CONCLUSIONS

While this patient has experienced a very significant improvement in hearing posttreatment, a hearing deficit remains, with a slight-to-mild sensorineural loss from 250 to 2000 Hz, and a moderate-to-severe sensorineural loss above 2000 Hz. The sensorineural loss at 2000 Hz and above is a likely result of his noise exposure in farming and other large equipment and machinery, and presbycusis. At present, however, he does not feel he has a sufficient communicative handicap with his current lifestyle to warrant consideration of amplification or other rehabilitation procedures. Thus, a recommendation for otolaryngology and audiology evaluation in 6 mo was made.

There were several factors suggesting that this patient would not have had such a positive outcome, including his age of 79 yr, the moderately severe to severe hearing loss, and the 4–6 wk treatment delay. Despite this, the authors and the patient felt that the oral steroid, and later the IT steroid injection, should be pursued. His significant improvement raises the question that his hearing loss, perhaps being particularly steroid responsive, may have an autoimmune etiology. Additionally, there is the possibility that the improvement in hearing may have been due to a spontaneous recovery, even though the review of literature suggests this to be unlikely.

Positive responses such as this to systemic and IT steroid injection treatments further complicate generalizations concerning treatment of ISSNHL that can be drawn

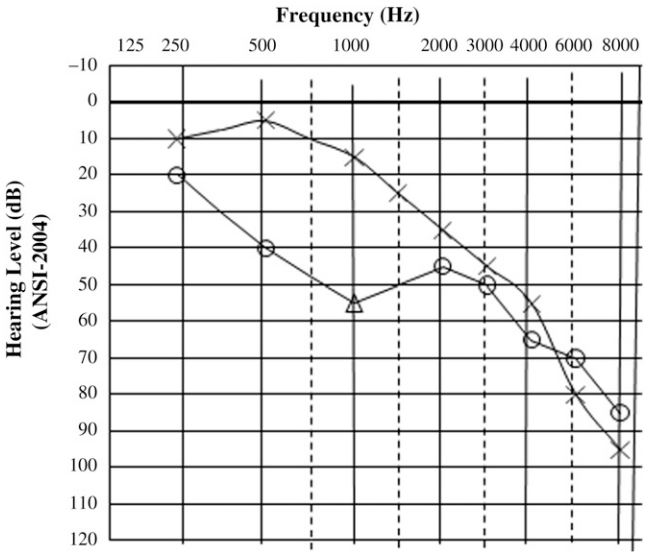

Figure 2. Patient's right and left ear pure tone air conduction threshold findings following initial oral systemic steroid treatment and first IT steroid injection.

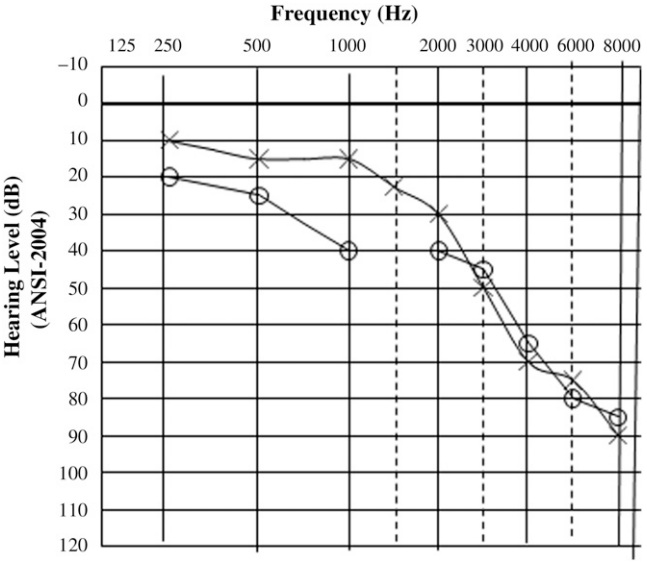

Figure 3. Patient's right and left ear pure tone air conduction threshold findings following initial oral systemic steroid treatment and second IT steroid injection.

Delivered by Ingenta to: Washington University School of Medicine Library
IP : 128.252.16.235 On: Mon, 22 Oct 2012 15:43:57

from the current body of literature. If an audiologist clinician had made the decision not to refer this patient for medical treatment and/or an otologist had decided not to treat this patient, due to the low probability of significant improvement in hearing, this patient may have been denied the possibility of improved hearing. Patients for whom short-term systemic steroids are not contraindicated may be candidates for such an approach, and the low-risk IT steroid treatment may be a possibility for many patients.

REFERENCES

Belal A, Jr. (1979) The effects of vascular occlusion on the human inner ear. *J Laryngol Otol* 93:955–968.

Byl FM, Jr. (1984) Sudden hearing loss: eight years experience and suggested prognostic table. *Laryngoscope* 94:647–661.

Chandrasekhar SS. (2003) Updates on methods to treat sudden hearing loss. *Oper Tech Otolaryngol Head Neck Surg* 14(4):288–292.

Cinamon U, Bendet E, Kronenberg J. (2001) Steroids, carbogen or placebo for sudden hearing loss. *Eur Arch Otorhinolaryngol* 258 (9):477–480.

Cole RR, Jahrsdoerfer RA. (1988) Sudden hearing loss: an update. *Am J Otol* 9(3):211–215.

Conlin AE, Parnes LS. (2007) Treatment of sudden sensorineural hearing loss. *Arch Otolaryngol Head Neck Surg* 133:573–581.

Fu Y, Zhao H, Zhang T, Chi F. (2011) Intratympanic dexamethasone as initial therapy for idiopathic sudden sensorineural hearing loss: clinical evaluation and a laboratory investigation. *Auris Nasus Larynx* 38:165–171.

Haynes DS, O'Malley M, Cohen S, Watford K, Labadie RF. (2007) Intratympanic dexamethasone for sudden sensorineural hearing loss after failure of systemic therapy. *Laryngoscope* 117:3–15.

Hu A, Parnes LS. (2009) Intratympanic steroids for inner ear disorders: a review. *Audiol Neurotol* 14:373–382.

Lin H, Chao P, Lee H. (2008) Sudden sensorineural hearing loss increases the risk of stroke: a 5-year follow-up study. *Stroke* 39: 2744–2748.

Martines F, Dispensa F, Galgardo C, Martines E, Bentivigna D. (2011) Sudden sensorineural loss as prodromal symptom of anterior inferior cerebellar artery infarction. *ORL J Otorhinolaryngol Relat Spec* 73:137–140.

Mattox DE, Simmons FB. (1977) Natural history of sudden sensorineural hearing loss. *Ann Otol Rhinol Laryngol* 86:463–480.

Moskowitz D, Lee KJ, Smith HW. (1984) Steroid use in idiopathic sudden sensorineural hearing loss. *Laryngoscope* 94:664–666.

National Institute on Deafness and Other Communication Disorders (NIDCD). (2003) Sudden deafness. NIH Pub. No. 00-4757.

Perlman HB, Kimura R, Fernandez C. (1959) Experiments on temporary obstruction of the internal auditory artery. *Laryngoscope* 69:591–613.

Sauvaget E, Kici S, Kania R, Herman P, Tran Ba Huy P. (2005) Sudden sensorineural hearing loss as a revealing symptom of vestibular schwannoma. *Acta Otolaryngol* 125:592–595.

Seggas I, Koltsidopoulos P, Biabas A, Tzonou A, Sismanis A. (2011) Intratympanic steroid therapy for sudden hearing loss: a review of the literature. *Otol Neurotol* 32:29–35.

Tsai YJ, Liang J-G, Wu W-B, Ding Y-F, Chiang RP-Y, Wu S-M. (2011) Intratympanic injection with dexamethasone for sudden sensorineural loss. *J Laryngol Otol* 125:133–137.

Vasama J, Linthicum FH. (2000) Idiopathic sudden sensorineural hearing loss: temporal bone histopathologic study. *Ann Otol Rhinol Laryngol* 109(6):527–532.

Wei BP, Mubiru S, O'Leary S. (2006) Steroids for idiopathic sudden sensorineural hearing loss. *Cochrane Database Syst Rev* Jan 25(1):CD003998.

Wilson WR, Byl FM, Laird N. (1980) The efficacy of steroids in the treatment of idiopathic sudden hearing loss. *Arch Otolaryngol Head Neck Surg* 106(12):772–776.

Wu S, Lin H, Chao P. (2006) Sudden sensorineural hearing loss: evidence from Taiwan. *Audiol Neurootol* 11:151–156.

Yoon TH, Paparella MM, Schachern PA, Alleva M. (1990) Histopathology of sudden hearing loss. *Laryngoscope* 100(7):707–715.

Delivered by Ingenta to: Washington University School of Medicine Library
IP : 128.252.16.235 On: Mon, 22 Oct 2012 15:43:57