

2017

PRDM1 expression levels in marginal zone lymphoma and lymphoplasmacytic lymphoma

Mohammad Hussaini
Moffitt Cancer Center

Cecilia Yeung
University of Washington

Xiaopei Zhu
Washington University School of Medicine in St. Louis

Abu-Sayeeff Mirza
University of South Florida

John Pfeifer
Washington University School of Medicine in St. Louis

See next page for additional authors

Follow this and additional works at: http://digitalcommons.wustl.edu/open_access_pubs

Recommended Citation

Hussaini, Mohammad; Yeung, Cecilia; Zhu, Xiaopei; Mirza, Abu-Sayeeff; Pfeifer, John; and Hassan, Anjum, "PRDM1 expression levels in marginal zone lymphoma and lymphoplasmacytic lymphoma." *International Journal of Clinical and Experimental Pathology*.10,8. . (2017).
http://digitalcommons.wustl.edu/open_access_pubs/6161

This Open Access Publication is brought to you for free and open access by Digital Commons@Becker. It has been accepted for inclusion in Open Access Publications by an authorized administrator of Digital Commons@Becker. For more information, please contact engeszer@wustl.edu.

Authors

Mohammad Hussaini, Cecilia Yeung, Xiaopei Zhu, Abu-Sayeed Mirza, John Pfeifer, and Anjum Hassan

Original Article

PRDM1 expression levels in marginal zone lymphoma and lymphoplasmacytic lymphoma

Mohammad Hussaini^{1*}, Cecilia Yeung^{2*}, Xiaopei Zhu³, Abu-Sayeeef Mirza⁴, John Pfeifer⁵, Anjum Hassan⁵

¹Department of Hematopathology and Laboratory Medicine, Moffitt Cancer Center, Tampa, FL, USA; ²Department of Pathology, University of Washington, Seattle, WA, USA; ³Departments of ³Laboratory Medicine, ⁵Pathology and Immunology, Washington University, St. Louis, MO, USA; ⁴Department of Internal Medicine, University of South Florida, Tampa, FL, USA. *Co-first authors.

Received February 22, 2017; Accepted March 23, 2017; Epub August 1, 2017; Published August 15, 2017

Abstract: PRDM1 (BLIMP1) is a transcription repressor protein shown to be involved in B-cell differentiation into plasma cells. Marginal zone lymphomas (MZL) and lymphoplasmacytic lymphomas (LPL) are B cell lymphomas that both show some degree of plasmacytic differentiation and thus can sometimes constitute a difficult differential diagnosis. In this study, we investigated if MZL and LPL have abnormalities in the expression of PRDM1 beta and if there are any differences in expression between these two entities. After interrogating 42 samples (15 marginal zone lymphomas, 9 lymphoplasmacytic lymphomas, 3 follicular lymphomas, and 13 normal/control samples), we have found that a significant percentage of MZL and LPL cases harbor abnormalities (67% and 44%, respectively) involving the PRDM1- β transcript (P=0.004). By immunohistochemistry, PRDM1 positive staining (>5%) was more common in MZL. We conclude that PRDM1- β may play a role in the pathogenesis of these low-grade lymphomas with plasmacytic differentiation.

Keywords: PRDM1, marginal zone lymphoma, lymphoplasmacytic lymphoma

Introduction

Positive regulatory domain containing 1 with zinc-finger domain (*PRDM1/BLIMP1*) located on chromosome 6q21-22.1 has been cited as the “master regulator” of B cell and plasma cell differentiation. *PRDM1* encodes a 98 kDa protein that represses beta-interferon gene expression via PRDI promoter binding. Alternative splicing leads to 2 variant isoforms: PRDM1 α , which is a tumor suppressor and PRDM1 β , which lacks the ability to repress transcription. Compared to PRDM1 α , PRDM1 β lacks exons 1-3 and the amino-terminal 101 amino acids. It also lacks the PR domain of PRDM1 α . Both α and β isoforms have shown to be involved in B cell differentiation into plasma cells [1]. More specifically, *PRDM1* has been shown to up-regulate syndecan-1 (CD138) in transfected B cell lymphoma cell lines [2]. Furthermore, PRDM1 β is expressed in germinal center B-cells that have committed to plasmacytic differentiation [3]. *PRDM1* expression is repressed by BCL-6 in

mature B cells and promotes plasmacytic differentiation by repressing PAX5 and allowing expression of XBP-1 [4, 5].

PRDM1 was first described in 1991 as a novel repressor of beta interferon [6]. It was formally described in 1994 as B lymphocyte induced maturation protein (*BLIMP1*), a transcription repressor protein. There have been a number of studies looking at the role *PRDM1* plays in various B-lineage lymphoid malignancies. Several papers have described the role of *PRDM1* mutations in the pathogenesis of diffuse large B-cell lymphomas (DLBCL) [7, 8]. Furthermore, *PRDM1* mutations are associated with increased chemotherapy resistance to regimens lacking Rituxan [9]. Previous publications also show a relationship between treatment response and PRDM1- β expression levels in mantle cell lymphoma (MCL) [10]. In multiple myeloma cases, *PRDM1* is reported to be functionally impaired [11]. *PRDM1* has also been shown to be downregulated in other lymphomas such as

Table 1. Demographic and sample characteristics

	Number of cases	Mean Age (Range)	Sex (F:M)	Mean Percent involvement by FC (Range)
FL	3	62 (57-69)	2:1	30% (<1%-51%)
LPL	9	62 (51-79)	2:7	10% (<1%-46%)
MZL	15	67 (50-87)	5:10	31.5% (1.2%-86%)
NL/Other	12	14-73	N/A	N/A

FC = Flow Cytometry; FL = Follicular Lymphoma, LPL = lymphoplasmacytic lymphoma, MZL = marginal zone lymphoma, NL = normal control.

NK/T cell lymphoma [12] and anaplastic large T cell lymphoma [13].

Marginal zone lymphoma (MZL) comprises three major classes of lymphoproliferative diseases, namely splenic MZL, nodal MZL, and extranodal MZL (MALT lymphomas) [14]. Together they constitute 5-17% of all non-Hodgkin lymphomas and are generally considered indolent neoplasms. However, when stratified by risk levels, 5-year overall survival ranges from 56-100% [15]. Lymphoplasmacytic lymphoma (LPL) is a relatively rare entity (incidence of 8 per 1 million; 1% of hematologic malignancies) comprising of small B-cells, plasmacytoid lymphocytes, and plasma cells and is, as such, a diagnosis of exclusion [14]. LPL is often accompanied by an IgM paraprotein and is indolent in behavior with a prognosis similar to nodal MZL but better than extranodal MZL. Since both lymphomas are those of small B cells of post-germinal center derivation with many cases of MZL showing plasmacytic differentiation, the distinction between these two entities can be challenging. More recently, mutations in MYD88 have been described in 90% of LPL, but these mutations have also been described in cases of MZL [16]. Even in the hands of experts, consensus is found in only about half of cases. In some cases, the distinction is so unclear as to generate a generic diagnosis of small B-cell lymphoma with plasmacytic differentiation despite adequate immunohistochemical, flow cytometric, and clinical work up [17, 18].

In this study, we evaluate the pattern and extent of *PRDM1* expression in lymphomas with plasmacytic differentiation, namely marginal zone lymphomas (MZL) and lymphoplasmacytic lymphoma (LPL).

Materials and methods

Patient's data

Permission for the study was granted by the Washington University Human Studies Committee. Sequentially archived snap frozen shed flow cytometric samples with the diagnosis of MZL or LPL were selected from the Barnes-Jewish Hospital flow cytometry archives from materials received between 2007-2010. All cases were reviewed by 2 hematopathologists to confirm the diagnosis. For the immunohistochemical portion of the study, cases of MZL and LPL from 2005-2008 were identified by searching the Copath database of the Division of Anatomic Pathology and BJH databases. Cases of nodal, extranodal, and splenic marginal zone lymphoma were included. Normal control cases included bone marrow samples which showed no involvement by B cell lymphoma, reactive lymph nodes, benign spleen, and benign tonsillar tissue.

Nucleic acid extraction and reverse transcriptase polymerase chain reaction

RNA extractions were performed by triazol reagent. A DNase treatment was performed on the RNA prior to reverse transcriptase-PCR (RT-PCR). RT-PCR was performed using previously published primers for *PRDM1-β* [9]. This generated cDNA that was run on a 4% agarose gel. A one step RT-PCR method was used according to manufacture protocol. The expected transcript length was 264 base pairs. Different length bands or absent bands are reported as abnormal. RT-PCR for beta-actin was performed on all cases to ensure sample RNA integrity.

PCR product purification and sequencing

PCR products from select abnormal cases with different length bands were purified and sequenced. PCR products from select cases with normal bands were also purified and sequenced to ensure target fidelity. This was performed with standard manufacture protocol for the Qiagen. Purified PCR products were sequenced by traditional Sanger method.

Immunohistochemistry

Immunohistochemical staining was optimized using an antibody directed to both *PRDM1α*

PRDM1 in MZL and LPL




Figure 1. A. Beta-actin control showing confirmed intact RNA for amplification in all samples. B. Abnormal bands are seen in select lanes of LPL and MZL along with one normal control. Complete loss of PRDM1 transcript is identified in several lanes representing cases of MZL on sample gel (Follicular lymphoma, LPL = lymphoplasmacytic lymphoma, MZL = marginal zone lymphoma, NL = normal control).

and PRDM1 β due to the lack of a PRDM1 specific antibody. A BLIMP1 antibody (3H2-E8 clone, Novus Biologics) was optimized and antigen retrieval was performed using a CC1 standard protocol (1 mM EDTA pH 8.0). Staining was performed on a BenchMark XT IHC/ISH Staining Module, and detection was performed with XT ultraView DAB v3. Slides were manually graded

for percentage nuclear staining in the lymphocytes. Staining was performed at 1:4 dilution (all cases). Cases with weaker or equivocal staining were rerun at a 1:2 dilution (13 cases). The higher of percentage staining between dilutions was adopted. In addition, two normal bone marrow core biopsies in patients with a history of plasma cell neoplasm and eight

PRDM1 in MZL and LPL

Table 2. Summary of RT-PCR results and cytogenetic data

	Number of cases	Wild-type (264 bp) band only	Extra/abnormal band	Complete loss	Cytogenetics (#of cases)
FL	3	3	0	0	t(14;18) (1)
LPL	9	5	3	1	Normal (2); Del11q21 and del 13 (1)
MZL	15	5	5	5	Normal (1)
NL	13	9	1	0	---
Other	2	0	2	0	Normal (1)

(FL = Follicular Lymphoma, LPL = lymphoplasmacytic lymphoma, MZL = marginal zone lymphoma, NL = normal control).

benign tonsil specimens were included as controls. Five percent or less tumor staining was considered negative.

Data analysis

The sequenced PCR product were aligned using Basic Local Alignment Search Tool (BLAST®) to interrogate for small deletions, insertions, substitutions, and transcripts of abnormal length. Statistical analysis was performed using a two-tailed Fischer t-test.

Results

Our search yielded 39 patient samples in total. The samples included 27 malignant cases comprising of 3 Follicular Lymphoma (FL), 9 LPL, 15 MZL (4 splenic MZL, 3 nodal MZL, 4 extra-nodal MZL, and 6 not further classified), 10 normal controls were initially evaluated, comprising of 3 reactive lymph nodes, 1 splenomegaly spleen sample, and 6 bone marrows; however two bone marrow cases were reclassified as indeterminate after review leaving 8 normal controls for comparison. In one case, a minute plasma cell clone of unknown significance was detected. In the other case, multiple lymphoid aggregates were noted in a patient with a history of MZL. Though initially favored to be benign, subsequent testing and involvement at various other sites was suggestive of bone marrow involvement. Demographic and specimen data is summarized in **Table 1**.

RT-PCR and sequencing

All follicular lymphomas showed a single 264 base pair band consistent with the wild-type *PRDM1* transcript (3/3). An extra abnormal band was seen in 4 LPL cases, 3 MZL, and 1 normal (NL) case. Complete loss of the *PRDM1* transcript (no band) was detected in 5 MZL

cases and 1 LPL case (**Figure 1**). PCR and cytogenetic results are summarized in **Table 2**.

Overall, 67% of MZL and 44% of LPL showed either loss or abnormal *PRDM1*- β transcript. All cases that were initially diagnosed as normal but subsequently reclassification showed abnormalities in *PRDM1*- β expression. *PRDM1*- β abnormalities were more common in MZL and LPL compared to normal cases (P=0.0043).

Sequencing of RT-PCR products from cases with only the wild-type 264 base pair band confirmed wild-type *PRDM1*- β sequence at the tested locus. Abnormal bands from a select LPL and MZL case were sequenced which both mapped to *PRDM1* region with greater than 90% homology. A single normal case showed an additional abnormal band. The forward read did not map to *PRDM1* and thus the product is presumed to be non-specific.

Recurrent abnormalities involving the same predicted splice site were also observed. A recurrent splice site variant at position -44 and -45 of the *PRDM1*- β transcript lying in the 5'UTR region was observed in 3 of the cases (2 MZL and 1 LPL). Predictions regarding splicing involving the promoter region were made based on interrogating the splice site mutation with two separate prediction software drosophila and SIFT. However, the splice site mutation does not appear to impact a change to the protein.

Cytogenetic data was available for 5 of the malignant cases. A t(14;18) was detected in one follicular lymphoma. Del11q21 and del 13 were reported by an outside institution in one case of LPL. Two other LPL cases and one MZL case showed normal karyotype. No cases showed a deletion involving 6q. Since the cohort for PCR and IHC studies were different,

PRDM1 in MZL and LPL

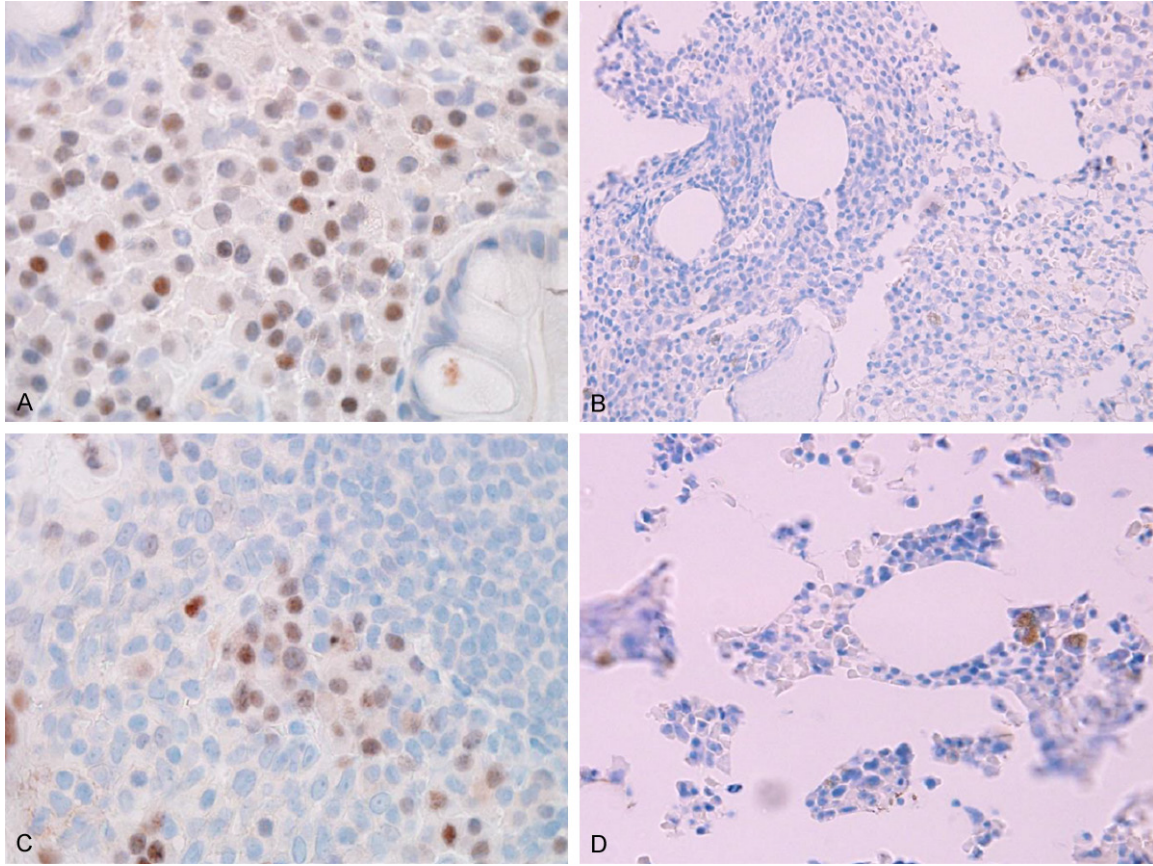


Figure 2. Immunohistochemical staining with PRDM1: A. Marginal zone lymphoma (100×, Olympus BX51); B. Lymphoplasmacytic lymphoma (40×); C. Lymph node positive control (100×); D. Normal bone marrow negative control (40×).

Table 3. Summary of demographics and immunohistochemical results for PRDM1 staining in marginal zone lymphoma and lymphoplasmacytic lymphoma

	Number of cases	Mean Age (range)	Sex (F:M)	Percentage PRDM1+ (≥ 5%)	Mean% lymphocyte staining in (+) cases
MZL	12	71 (52-87)	6:6	33% (4/12)	16% (range 10-25%)
LPL	8	61 (48-79)	6:2	0% (0/8)	0%
Normal BM	2	63 (62-63)	2:0	0% (0/2)	0%

analysis was limited in that correlative comparisons between PCR, cytogenetics, and immunostaining were not possible.

Immunohistochemistry

A total of 20 lymphoma cases were available for review comprising of 12 male and 8 female patients with a median age of 66 years (range 48-87 years). Twelve of the cases were MZL (60%) and 8 cases were LPL (40%). Four of 12

MZL cases (33%) but none of the LPL cases 0/8 showed positive staining for PRDM1 ($P=0.116$) (Figure 2). Though this was not statistically significant given the small sample size, a trend for increased immunostaining was seen. Both the bone marrow cores showed no staining (0/2). In the benign lymph nodes, the mantle zone lymphocytes were clearly negative while interfollicular plasma cells and a subset of germinal center cells showed positive staining. Demographics and staining results are summarized in Table 3.

Discussion

PRDM1 has previously been implicated in the pathogenesis and treatment response of B-cell lymphoid neoplasms such as Burkitt Lympho-

PRDM1 in MZL and LPL

ma (BL), DLBCL, MCL, and MM [19]. Furthermore *PRDM1* has been shown to function as a tumor suppressor in B cell lymphomas [18]. As a key regulator of plasma cell differentiation in B-cells, we sought to investigate the patterns of expression and role of PRDM1-beta in B-cell lymphomas associated with plasmacytic differentiation, namely MZL and LPL.

We found that in 67% and 44% of cases of MZL and LPL, respectively, there was some type of aberration of the PRDM1- β transcript. These aberrations consisted of either complete loss of the transcript seen in 33% and 11% of MZL and LPL cases, respectively, or an abnormally-sized transcript (33% for both). In these cases, complete transcript loss may be the result of deletions involving *PRDM1* (located on 6q21, Ensembl) or epigenetic mechanisms resulting in silencing of *PRDM1* expression. Though available cytogenetic data was limited, no loss of 6q was detected in any of the cases implying the presence of a microdeletion. Cryptic deletions of 6q21 have been previously reported in MZL (14%-16% of cases) and were associated with a switch to high grade histology (predominant large cell or blast component) [20]. In fact, del6q has been identified as one of the predominant aberrations in splenic MZL (11%) though an association with survival has not been described [21, 22]. With regards to lymphoplasmacytic lymphoma, del6q has been cited as the most frequent copy number alteration in Waldenstrom macroglobulinemia (WM) with rates of detection based on various methodologies (conventional cytogenetics, FISH, array CGH, SNP) ranging from 22% to 42% [23]. In WM, del6q may be a poor prognostic factor [24]. There is variability in the minimal deleted region due to involvement of large fragments of 6q. Putative tumor suppressor genes in this region include TNFAIP3 and PRDM1 [24, 25].

The frequency of PRDM1 loss in our study is lower than that cited in the literature for LPL, though this may be due to our small sample size. Furthermore, since primers targeted only the beta transcript (not alpha), it is possible that we are underestimating the loss *PRDM1* mRNA transcripts in this study. Based on frequent loss in MZL, *PRDM1* may serve as a rational candidate gene for disease pathogenesis in MZL as well as LPL. Functional and animal studies with knock-out models, are likely to aid in

clarifying *PRDM1*'s precise role in lymphomagenesis.

Deletion in 6q is a known common abnormality seen in lymphoid malignancies [26]. While the loss of *PRDM1* may be responsible for the pathogenesis in some of the cases with 6q deletion, other mechanisms are likely at play given that nearly half of cases will not demonstrate deletion of 6q. Whole genome survey for copy number alterations may have shed light in this regard, but remained a limitation for this study due to the lack of additional material. In ocular adnexal marginal zone B cell lymphoma, *TNFAIP3* was identified as the target gene in cases of loss at adjacent 6q23.3-q24.1 loci [27]. A negative regulator of nuclear factor-kappa B (NF-kappaB), *TNFAIP3* was deleted in other lymphoid malignancies such as DLBCL and MCL [28]. In DLBCL, deletions of either *PRDM1* or *TNFAIP3* were seen, but not both, would be deleted in a homozygous manner [29]. The possibility of functional synergism between *PRDM1* and the TNFAIP3 gene product may also be considered in MZL and LPL [5].

In many of the cases in our cohort, an abnormally sized band was identified rather than complete loss of the transcript. Sanger sequencing identified various mutations to account for the change in transcript size including single base pair deletions and single base pair substitutions. Interestingly, a recurrent splice site variant was identified affecting the promoter region in the 5'UTR of the PRDM1 transcript. The functional significance of these genetic alterations are unclear without in vitro studies, but one may postulate that alternative splicing may result in a qualitative defect of the translated protein providing a mechanism for 'functional deletion'. This proposes a possible mechanism leading to down regulation of PRDM1 in these B cell lymphomas.

In this study, PRDM1 staining (>5%) was more frequently positive in MZL than LPL. While absent staining was seen in LPL, loss by immunohistochemistry did not correlate with loss of the *PRDM1* transcript in our PCR experiments. This may be the result of non-specificity of the PRDM1 antibody derived from the 3H2-E8 cell line which was raised using murine PRDM-1 residues 199-409. The antibody did not demonstrate specificity for the beta transcript like the primer used for RT-PCR. The use of an

aptamer with specificity for the beta variant may circumvent this limitation. Furthermore, despite titration of antibody at various dilutions, most cases showed only a light blush of staining in positive cells in order to obtain low background, making grading of staining in the lymphoma cases subjective. Higher concentration of antibody may have demonstrated positivity in LPL cases, but at the cost of increasing non-specific background staining making reliable grading infeasible. Other studies, which have used immunohistochemistry, have shown *PRDM1* expression in LPL plasma cells appeared to be lower in comparison to marginal zone lymphoma and myeloma, however they were not able to achieve statistical significance [30].

Overall, this study implicates altered *PRDM1* expression in the pathogenesis of lymphomas with plasmacytic differentiation, namely LPL and MZL. This is congruent with gene expression studies, which have shown lower *PRDM1* expression in lymphoplasmacytic lymphoma [31]. Alterations in *PRDM1* are biologically rational in this regard, considering that loss of a factor driving B-cell differentiation to plasma cells could well account for absence of full plasmacytic differentiation in the B-cells that comprise these neoplasms. FISH or sequencing of cases with total *PRDM1* loss may help differentiate between epigenetic mechanisms versus deletions in these cases. Importantly, it will be useful to analyze clinical outcomes in patients with *PRDM1* aberrations as well as investigate propensity to progress to DLBCL so as to determine the clinical significance of our findings. Finally, in-vitro and murine models may provide clarification with regards to the true biologic role of *PRDM1* in low-grade lymphomas with plasmacytic differentiation.

Disclosure of conflict of interest

None.

Address correspondence to: Dr. Abu-Sayef Mirza, Department of Internal Medicine, University of South Florida, 12901 Bruce B. Downs Blvd. Tampa, FL 33612, USA. Tel: 813-777-9256; E-mail: smirza1@health.usf.edu

References

[1] Tam W, Gomez M, Chadburn A, Lee JW, Chan WC, Knowles DM. Mutational analysis of

PRDM1 indicates a tumor-suppressor role in diffuse large B-cell lymphomas. *Blood* 2006; 107: 4090-100.

[2] Turner CA Jr, Mack DH and Davis MM. Blimp-1, a novel zinc finger-containing protein that can drive the maturation of B lymphocytes into immunoglobulin-secreting cells. *Cell* 1994; 77: 297-306.

[3] Cattoretti G, Angelin-Duclos C, Shaknovich R, Zhou H, Wang D and Alobeid B. *PRDM1/Blimp-1* is expressed in human B-lymphocytes committed to the plasma cell lineage. *J Pathol* 2005; 206: 76-86.

[4] Boi M, Zucca E, Inghirami G, Bertoni F. *PRDM1/BLIMP1*: a tumor suppressor gene in B and T cell lymphomas. *Leuk Lymphoma* 2015; 56: 1223-8.

[5] Hangaishi A and Kurokawa M. *Blimp-1* is a tumor suppressor gene in lymphoid malignancies. *Int J Hematol* 2010; 91: 46-53.

[6] Keller AD and Maniatis T. Identification and characterization of a novel repressor of beta-interferon gene expression. *Genes Dev* 1991; 5: 868-879.

[7] Mandelbaum J, Bhagat G, Tang H, Mo T, Brahmachary M, Shen Q, Chadburn A, Rajewsky K, Tarakhovsky A, Pasqualucci L and Dalla-Favera R. *BLIMP1* is a tumor suppressor gene frequently disrupted in activated B cell-like diffuse large B cell lymphoma. *Cancer Cell* 2010; 18: 568-579.

[8] Wagner SD, Ahearne M and Ko Ferrigno P. The role of *BCL6* in lymphomas and routes to therapy. *Br J Haematol* 2011; 152: 3-12.

[9] Liu YY, Leboeuf C, Shi JY, Li JM, Wang L, Shen Y, Garcia JF, Shen ZX, Chen Z, Janin A, Chen SJ and Zhao WL. Rituximab plus CHOP (R-CHOP) overcomes *PRDM1*-associated resistance to chemotherapy in patients with diffuse large B-cell lymphoma. *Blood* 2007; 110: 339-344.

[10] Desai S, Maurin M, Smith MA, Bolick SC, Desureault S, Tao J, Sotomayor E and Wright KL. *PRDM1* is required for mantle cell lymphoma response to bortezomib. *Mol Cancer Res* 2010; 8: 907-918.

[11] Ocana E, Gonzalez-Garcia I, Gutierrez NC, Mora-Lopez F, Brieva JA and Campos-Caro A. The expression of *PRDI-BF1* beta isoform in multiple myeloma plasma cells. *Haematologica* 2006; 91: 1579-1580.

[12] Liang L, Nong L, Zhang S, Zhao J, Ti H, Dong Y, Zhang B and Li T. The downregulation of *PRDM1/Blimp-1* is associated with aberrant expression of miR-223 in extranodal NK/T-cell lymphoma, nasal type. *J Exp Clin Cancer Res* 2014; 33: 7.

[13] Boi M, Rinaldi A, Kwee I, Bonetti P, Todaro M, Tabbo F, Piva R, Rancoita PM, Matolcsy A, Timar B, Tousseyn T, Rodriguez-Pinilla SM, Piris

- MA, Bea S, Campo E, Bhagat G, Swerdlow SH, Rosenwald A, Ponzoni M, Young KH, Piccaluga PP, Dummer R, Pileri S, Zucca E, Inghirami G and Bertoni F. PRDM1/BLIMP1 is commonly inactivated in anaplastic large T-cell lymphoma. *Blood* 2013; 122: 2683-2693.
- [14] Swerdlow SH; International Agency for Research on Cancer, World Health Organization. WHO classification of tumours of haematopoietic and lymphoid tissues. Lyon, France: International Agency for Research on Cancer; 2008.
- [15] Federico M, Molica S, Bellei M and Luminari S. Prognostic factors in low-grade non-Hodgkin lymphomas. *Curr Hematol Malig Rep* 2009; 4: 202-210.
- [16] Martinez-Lopez A, Curiel-Olmo S, Mollejo M, Cereceda L, Martinez N, Montes-Moreno S, Almaraz C, Revert JB and Piris MA. MYD88 (L265P) somatic mutation in marginal zone B-cell lymphoma. *Am J Surg Pathol* 2015; 39: 644-651.
- [17] Lin P, Molina TJ, Cook JR and Swerdlow SH. Lymphoplasmacytic lymphoma and other non-marginal zone lymphomas with plasmacytic differentiation. *Am J Clin Pathol* 2011; 136: 195-210.
- [18] Molina TJ, Lin P, Swerdlow SH and Cook JR. Marginal zone lymphomas with plasmacytic differentiation and related disorders. *Am J Clin Pathol* 2011; 136: 211-225.
- [19] Zhang T, Ma J, Nie K, Yan J, Liu Y, Bacchi CE, Queiroga EM, Gualco G, Sample JT, Orazi A, Knowles DM and Tam W. Hypermethylation of the tumor suppressor gene PRDM1/Blimp-1 supports a pathogenetic role in EBV-positive Burkitt lymphoma. *Blood Cancer J* 2014; 4: e261.
- [20] Cuneo A, Bigoni R, Roberti MG, Milani R, Agostini P, Cavazzini F, Minotto C, De Angeli C, Bardi A, Tammiso E, Negrini M, Cavazzini P and Castoldi G. Molecular cytogenetic characterization of marginal zone B-cell lymphoma: correlation with clinicopathologic findings in 14 cases. *Haematologica* 2001; 86: 64-70.
- [21] Watkins AJ, Huang Y, Ye H, Chanudet E, Johnson N, Hamoudi R, Liu H, Dong G, Attygalle A, McPhail ED, Law ME, Isaacson PG, de Leval L, Wotherspoon A and Du MQ. Splenic marginal zone lymphoma: characterization of 7q deletion and its value in diagnosis. *J Pathol* 2010; 220: 461-474.
- [22] Salido M, Baro C, Oscier D, Stamatopoulos K, Dierlamm J, Matutes E, Traverse-Glehen A, Berger F, Felman P, Thieblemont C, Gesk S, Athanasiadou A, Davis Z, Gardiner A, Milla F, Ferrer A, Mollejo M, Calasanz MJ, Florensa L, Espinet B, Luno E, Wlodarska I, Verhoef G, Garcia-Granero M, Salar A, Papadaki T, Serrano S, Piris MA and Sole F. Cytogenetic aberrations and their prognostic value in a series of 330 splenic marginal zone B-cell lymphomas: a multicenter study of the splenic B-cell lymphoma group. *Blood* 2010; 116: 1479-1488.
- [23] Poulain S, Roumier C, Galiegue-Zouitina S, Daudignon A, Herbaux C, Aijjou R, Lainelle A, Broucqsaout N, Bertrand E, Manier S, Renneville A, Soenen V, Tricot S, Roche-Lestienne C, Duthilleul P, Preudhomme C, Quesnel B, Morel P and Leleu X. Genome wide SNP array identified multiple mechanisms of genetic changes in waldenstrom macroglobulinemia. *Am J Hematol* 2013; 88: 948-954.
- [24] Nguyen-Khac F, Lambert J, Chapiro E, Grelier A, Mould S, Barin C, Daudignon A, Gachard N, Struski S, Henry C, Penther D, Mossafa H, Andrieux J, Eclache V, Bilhou-Nabera C, Luquet I, Terre C, Baranger L, Mugneret F, Chiesa J, Mozziconacci MJ, Callet-Bauchu E, Veronese L, Blons H, Owen R, Lejeune J, Chevret S, Merle-Beral H, Leblondon V; Groupe Français d'Etude de la Leucémie Lymphoïde Chronique et Maladie de Waldenström (GFCLL/MW); Groupe Ouest-Est d'étude des Leucémie Aiguës et Autres Maladies du Sang (GOELAMS); Groupe d'Etude des Lymphomes de l'Adulte (GELA). Chromosomal aberrations and their prognostic value in a series of 174 untreated patients with waldenstrom's macroglobulinemia. *Haematologica* 2013; 98: 649-654.
- [25] Braggìo E, Keats JJ, Leleu X, Van Wier S, Jimenez-Zepeda VH, Valdez R, Schop RF, Price-Troska T, Henderson K, Sacco A, Azab F, Greipp P, Gertz M, Hayman S, Rajkumar SV, Carpten J, Chesi M, Barrett M, Stewart AK, Dogan A, Bergsagel PL, Ghobrial IM and Fonseca R. Identification of copy number abnormalities and inactivating mutations in two negative regulators of nuclear factor-kappaB signaling pathways in waldenstrom's macroglobulinemia. *Cancer Res* 2009; 69: 3579-3588.
- [26] Taborelli M, Tibiletti MG, Martin V, Pozzi B, Bertoni F and Capella C. Chromosome band 6q deletion pattern in malignant lymphomas. *Cancer Genet Cytogenet* 2006; 165: 106-113.
- [27] Honma K, Tsuzuki S, Nakagawa M, Karnan S, Aizawa Y, Kim WS, Kim YD, Ko YH and Seto M. TNFAIP3 is the target gene of chromosome band 6q23.3-q24.1 loss in ocular adnexal marginal zone B cell lymphoma. *Genes Chromosomes Cancer* 2008; 47: 1-7.
- [28] Honma K, Tsuzuki S, Nakagawa M, Tagawa H, Nakamura S, Morishima Y and Seto M. TNFAIP3/A20 functions as a novel tumor suppressor gene in several subtypes of non-Hodgkin lymphomas. *Blood* 2009; 114: 2467-2475.
- [29] Thelander EF, Ichimura K, Corcoran M, Barbany G, Nordgren A, Heyman M, Berglund M,

PRDM1 in MZL and LPL

- Mungall A, Rosenquist R, Collins VP, Grander D, Larsson C and Lagercrantz S. Characterization of 6q deletions in mature B cell lymphomas and childhood acute lymphoblastic leukemia. *Leuk Lymphoma* 2008; 49: 477-487.
- [30] Roberts MJ, Chadburn A, Ma S, Hyjek E and Peterson LC. Nuclear protein dysregulation in lymphoplasmacytic lymphoma/waldenstrom macroglobulinemia. *Am J Clin Pathol* 2013; 139: 210-219.
- [31] Gutierrez NC, Ocio EM, de Las Rivas J, Maiso P, Delgado M, Ferminan E, Arcos MJ, Sanchez ML, Hernandez JM and San Miguel JF. Gene expression profiling of B lymphocytes and plasma cells from waldenstrom's macroglobulinemia: comparison with expression patterns of the same cell counterparts from chronic lymphocytic leukemia, multiple myeloma and normal individuals. *Leukemia* 2007; 21: 541-549.