

Washington University School of Medicine

Digital Commons@Becker

Presentations

Center for History Of Medicine

2015

The history of Stevens-Johnson Syndrome and a case study

George M. Bohigian

Washington University School of Medicine in St. Louis

Center for History of Medicine at Washington University School of Medicine in St. Louis

Follow this and additional works at: https://digitalcommons.wustl.edu/historyofmedicine_presentations

Recommended Citation

Bohigian, George M. and Center for History of Medicine at Washington University School of Medicine in St. Louis, "The history of Stevens-Johnson Syndrome and a case study" (2015). *Presentations*. Paper 1. https://digitalcommons.wustl.edu/historyofmedicine_presentations/1

This Presentation is brought to you for free and open access by the Center for History Of Medicine at Digital Commons@Becker. It has been accepted for inclusion in Presentations by an authorized administrator of Digital Commons@Becker. For more information, please contact vanam@wustl.edu.

THE HISTORY OF STEVENS-JOHNSON SYNDROME
AND A CASE STUDY

COGAN OPHTHALMIC HISTORY SOCIETY
NEW YORK, NY 2015

GEORGE M. BOHIGIAN, M.D.
PROFESSOR OF CLINICAL OPHTHALMOLOGY
DEPARTMENT OF OPHTHALMOLOGY AND VISUAL SCIENCES
WASHINGTON UNIVERSITY SCHOOL OF MEDICINE
ST. LOUIS, MO

AND

THE CENTER FOR THE HISTORY OF MEDICINE
AT WASHINGTON UNIVERSITY MEDICAL SCHOOL
ST. LOUIS, MO

INTRODUCTION:

Definition:

Stevens-Johnson syndrome and toxic epidermal necrolysis are two forms of a life-threatening skin conditions, in which cell death causes the epidermis to separate from the dermis. This syndrome is thought to be a hypersensitivity complex that affects the skin and the mucous membranes. The exact etiology and treatment at this time is not well understood. The most common causes for initiation of the syndrome are the use of certain antibiotics such as sulfa drugs. Stevens-Johnson syndrome (SJS) is a moderate form of toxic epidermal necrolysis (TEN).

History:

The history of Albert Stevens (Surgeon) and Frank Johnson (Pediatrician):

Albert Stevens was born in 1884 in Rangoon, India, the son of a Baptist missionary. He moved to the United States at age ten and received a Bachelor of Arts degree from Yale University in 1905. He went to Oxford on a Rhodes scholarship in 1908 and received his MD from Columbia University, College of Physicians and Surgeons in 1915. He was awarded a \$125 (equal to \$4000 in today's dollars) scholarship for the first year of medical school. The following year he wrote a letter expressing appreciation for the scholarship but said that he had obtained summer employment during his vacation. He no longer needed the financial help. He asked the committee to give the money and scholarship to another needy student. He served in World War I as an assistant surgeon. He was captured by the Germans and repatriated to the US after the war ended. He joined the staff at Bellevue Hospital, New York City. He retired to Honolulu Hawaii and taught in the Hawaiian school system and started a small plantation growing tropical fruit. He died August 6, 1945 at the end of World War II. (Ref 1) (Fig 1)




Figure 1


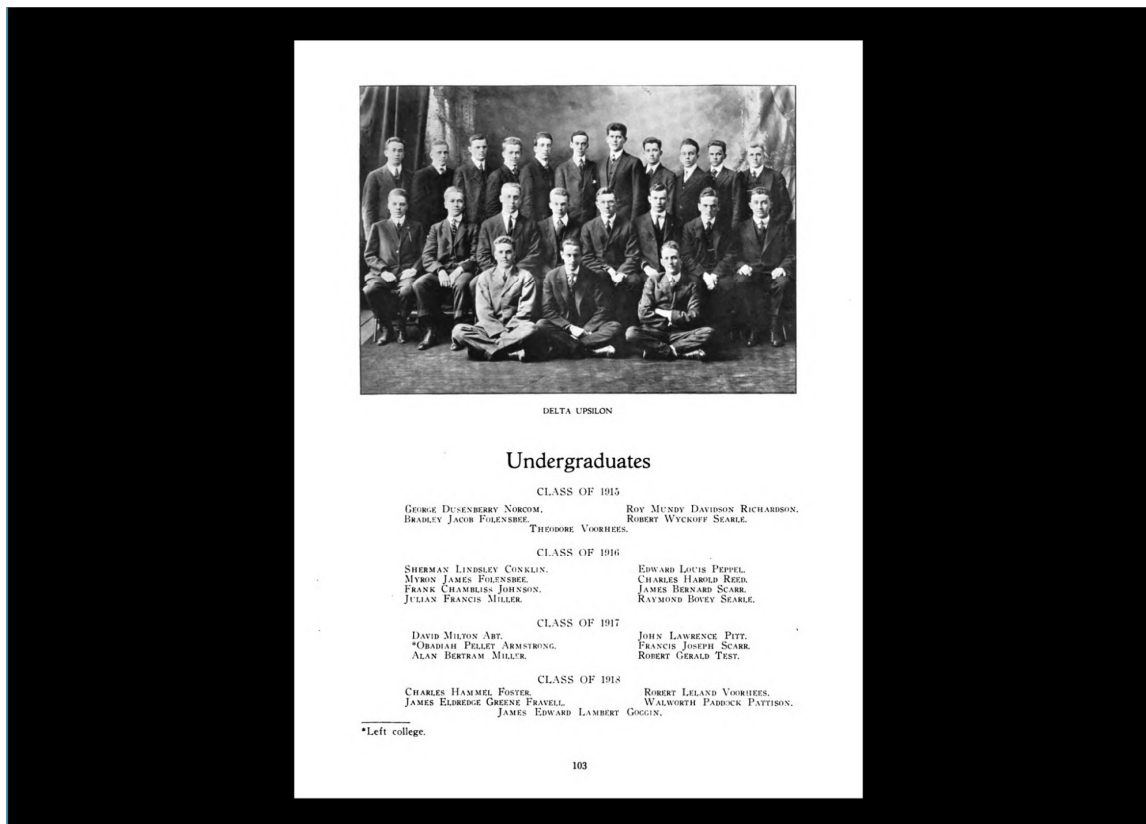


Figure 2



Year Book Photo

Rutgers College

Figure 3

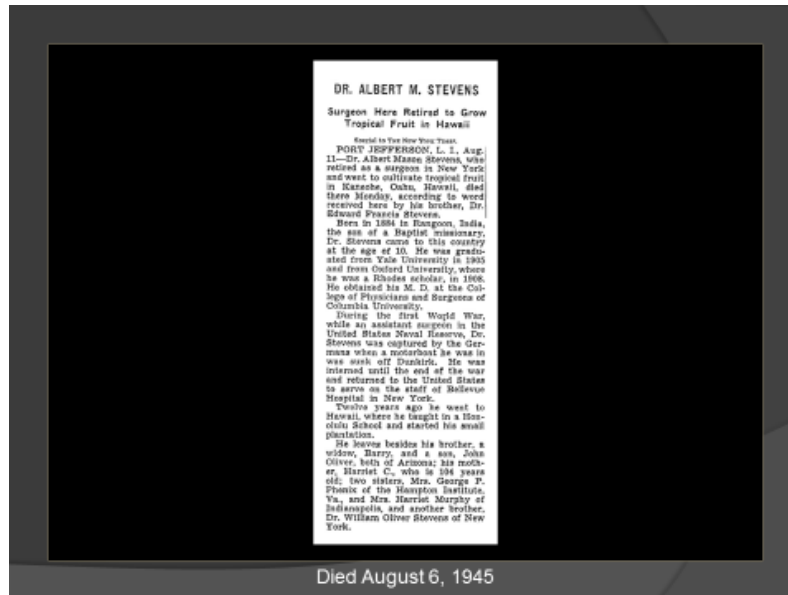

Figure 4

Frank Johnson graduated from Rutgers College in 1916 and went to Columbia University Physicians and Surgeons and graduated in 1920. (Fig 2&3) He started a practice in pediatrics in New Brunswick New Jersey. Unfortunately he died in a quarry fall while studying geological formations and plant specimens on January 1, 1934. See obituaries on both Stevens and Johnson. (Ref 2) (Fig 4 & 5)

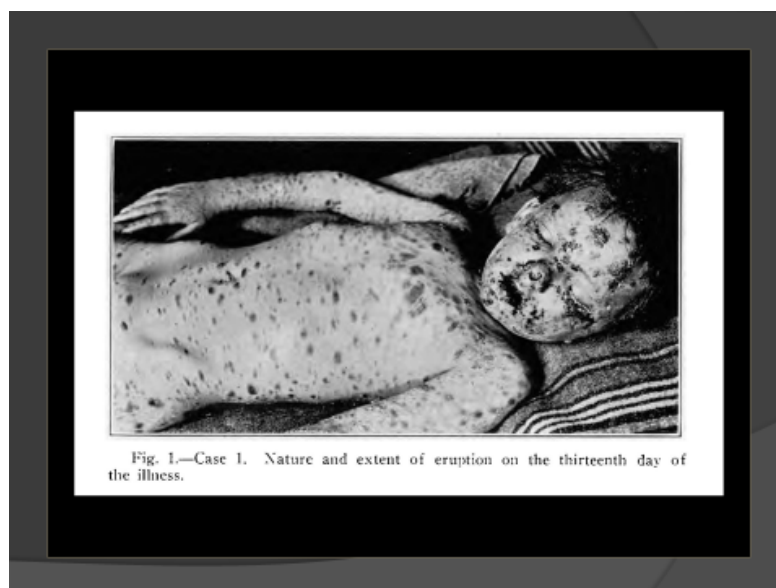

Figure 5

How Albert Stevens and Frank Johnson collaborated and met is unknown but probably both knew each other from the Columbia University Physicians & Surgeons and both were on the staff of Bellevue Hospital. Neither one was an ophthalmologist.

They jointly collaborated on a publication entitled “A New Eruptive Fever Associated with Stomatitis and Ophthalmia” in the *American Journal of Diseases of Children* in December of 1922. (Ref 3). That was the name of the journal from 1911 to the 1990's. The name was then changed to the Archives of Pediatrics and Adolescent Medicine. The name of the journal was recently changed, and it is now called JAMA Pediatrics.

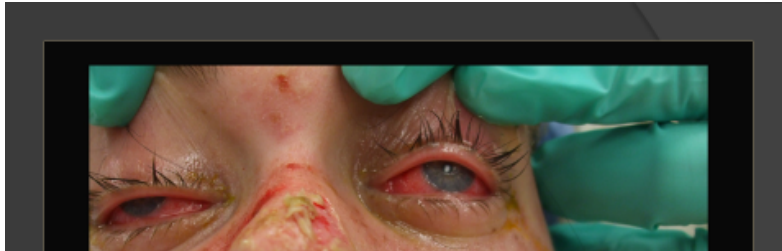
Two young boys had been admitted to Bellevue in New York City with skin eruptions of oval, dark red to purplish spots separated by normal tissue (Fig 6). The appearance looking like a “bull's-eye.” There was fever, conjunctivitis, inflamed mucus membranes, and one of the young boys had a total loss of vision. They had never seen this condition before and they had multiple consultants evaluate these patients. Their report was the first description of what later became Stevens-Johnson syndrome. The Lancet noted this article and described it as a new eruptive fever. (Ref 4) When it became “Stevens-Johnson syndrome” is unclear. (Ref 5)



One of the patients in the original publication. Figure 6

Clinical Features:

Stevens-Johnson syndrome is an immune hypersensitivity complex that typically involves the skin and mucus membranes. (Ref 6) (Fig 7) SJS is minor form of toxic epidermal necrolysis with less than 10% body surface area of detachment of the epidermis. Overlapping SJS is TEN with the detachment of 10 to 30 percent of the body surface area. Clinical features include inflammation, blistering of the mouth and eyes, and it attacks the deepest layer of the skin and mucous membrane. There is sloughing of the top layer of skin like a severe burn.



Acute Stage

Figure 7

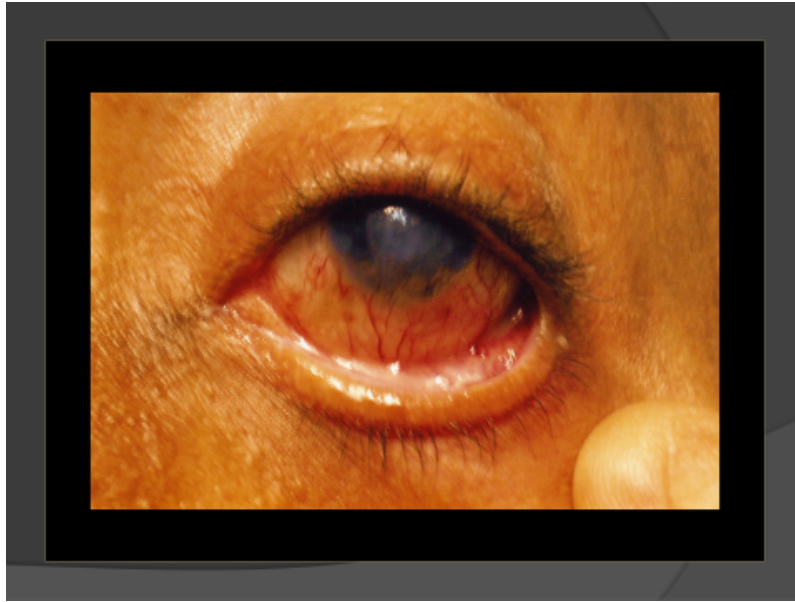
SJS usually begins with a fever, sore throat, and fatigue. It is commonly misdiagnosed and therefore treated with antibiotics. Ulcers and other lesions begin to appear in mucous membranes and almost always in the mouth, and lips, but also in the genital area. Conjunctivitis of the eyes occurs in about 30% of the children. The common offending drugs are antibiotics especially sulfa and certain non-steroidal anti-inflammatory medication like ibuprofen (Advil) .25% of the time no drug can be identified. SJS is thought to arise from a disorder of the immune system. Genetic factors may play a role in SJS and TEN. SJS a rare condition with a reported incidence of two to six cases per million per year. In the United States there are about three hundred new cases diagnosed yearly. Mortality of SJS is about 5%; however, the mortality of toxic epidermal necrolysis TEN is 30 to 40%.

Ocular Signs:

- 1. Eye Lid:** trichiasis, Meibomian gland dysfunction, and blepharitis.
- 2. Conjunctiva:** papillae, follicles, keratinization, conjunctival shrinkage, foreshortening of fornices, symblepharon, and ankyloblepharon.
- 3. Cornea:** superficial punctate keratitis, epithelial defect, stromal ulcer, keratinization and stromal opacity.

Case Study:

This is a patient of mine, a 63-year-old African-American male was originally seen at age 21 in 1973 as a referral. He had an acute bout of Stevens-Johnson syndrome at age 14 secondary to oral sulfonamide antibiotic. His right eye perforated and which resulted in prosthesis. This patient has best-corrected vision of 20/400 in his left eye. He gradually went from 20/30 over the years to 20/400. Presently considering Boston K Pro (Fig 8).



Current photo of patient

Figure 8

Management:

An article in the February 2015 issue of *Ophthalmology* demonstrates the role of comparing systemic and immuno suppressive therapy in chronic SJS. (Ref 7) Systemic the use of steroids, immune and combinations was no better than supportive therapy alone. The role of an artificial clear plastic cornea, Boston K-Pro is gaining popularity. In a large case study in *Ophthalmology* November 2014. (Ref 8) Approximately 65% did well; however, patients with Stevens-Johnson syndrome do not have a good prognosis.

Summary:

Stevens - Johnson syndrome is a rare disease which includes ocular and systemic manifestations, The exact etiology is unknown and the best management is still being investigated. (Ref 9)

References:

- 1) Obituary of Albert Stevens MD, New York Times August 11, 1945
- 2) Obituary of Frank Johnson MD, New York Times January 2, 1934
- 3) Stevens, A. and Johnson, F. A new eruptive fever associated with stomatitis and ophthalmia: report of two cases in children. *American Journal of Children* 1922; 24: 526–533
- 4) A New Eruptive Fever, *Lancet*, Dec 30, 1922 p 1396
- 5) Thomas B The So-Called Stevens -Johnson Syndrome. *British Medical Journal* June 1950 p 1393
- 6) Bastuji-Garin, S., Rzany, B., Stern, R.S. et al. Clinical classification of cases of toxic epidermal necrolysis, Stevens-Johnson syndrome, and erythema multiforme. *Arch Dermatol.* 1993; 129: 92–96
- 7) The Role of Systemic Immunomodulatory Treatment and Prognostic Factors on Chronic Ocular Complications in Stevens–Johnson Syndrome *Ophthalmology* Dong Hyun Kim, Kyung Chul Yoon, Kyoung Yul Seo, Hyo Seok Lee, Sang Chul Yoon, Chie Sotozono, Mayumi Ueta, Mee Kum Kim vol 122, 2 Feb 2015 Pages 254-264
- 8) Srikumaran D, Munoz B, Aldave AJ, Aquavella JV, Hannush SB, Schultze R, Belin M, Akpek EK. Long-term outcomes of Boston type 1 keratoprosthesis implantation: a retrospective multicenter cohort. *Ophthalmology*. 2014 Nov;121(11):2159-64.
- 9) Mockenhaupt M (2011). "The current understanding of Stevens–Johnson syndrome and toxic epidermal necrolysis". *Expert Review of Clinical Immunology* 2013, 7 (6): 803–15. doi: 10.1586/eci.11.66. PMID 22014021

Figures:

1. Stevens at Oxford
2. Rutgers Year Book Photo of Johnson
3. Group Photo from Year Book of Johnson
4. Stevens Obituary
5. Johnson Obituary
6. Picture of one of the patients in the 1922 article
7. Clinical photo of the face in the acute stage
8. Current photo of patient.