

1995

## Four cases of acoustic neuromas with normal hearing

Michael Valente

*Washington University School of Medicine in St. Louis*

Judy Peterin

*Washington University School of Medicine in St. Louis*

Joel Goebel

*Washington University School of Medicine in St. Louis*

J. Gail Neely

*Washington University School of Medicine in St. Louis*

Follow this and additional works at: [https://digitalcommons.wustl.edu/audio\\_hapubs](https://digitalcommons.wustl.edu/audio_hapubs)

---

### Recommended Citation

Valente, Michael; Peterin, Judy; Goebel, Joel; and Neely, J. Gail, "Four cases of acoustic neuromas with normal hearing" (1995). *Publications*. Paper 14.

[https://digitalcommons.wustl.edu/audio\\_hapubs/14](https://digitalcommons.wustl.edu/audio_hapubs/14)

This Article is brought to you for free and open access by the Division of Adult Audiology at Digital Commons@Becker. It has been accepted for inclusion in Publications by an authorized administrator of Digital Commons@Becker. For more information, please contact [vanam@wustl.edu](mailto:vanam@wustl.edu).

# Four Cases of Acoustic Neuromas with Normal Hearing

Michael Valente\*  
Judy Peterein\*  
Joel Goebel\*  
J. Gail Neely\*

## Abstract

In 95 percent of the cases, patients with acoustic neuromas will have some magnitude of hearing loss in the affected ear. This paper reports on four patients who had acoustic neuromas and normal hearing. Results from the case history, audiometric evaluation, auditory brainstem response (ABR), electroneurography (ENOG), and vestibular evaluation are reported for each patient. For all patients, the presence of unilateral tinnitus was the most common complaint. Audiologically, elevated or absent acoustic reflex thresholds and abnormal ABR findings were the most powerful diagnostic tools.

**Key Words:** Acoustic neuroma, acoustic reflex threshold, auditory brainstem response (ABR), electroneurography (ENOG), electronystagmography (ENG), posturography, reflex decay

**A**coustic neuromas, better referred to as solitary vestibular schwannomas, are benign tumors of the Schwann cell sheath around nerve fibers in the vestibular division of the eighth cranial nerve. They usually originate within the internal auditory canal and may extend into the cerebellopontine angle (CPA). The incidence is between 0.8 to 1.0 persons per 100,000 population per year (Monsell and Rock, 1990). Between 2000 and 3000 clinical cases of vestibular schwannomas are diagnosed annually (Brackmann and Arriaga, 1993), and an unknown number of additional cases are found annually during autopsies. Approximately 92 percent are vestibular schwannomas, 3 percent are meningiomas, 2.5 percent are primary cholesteatomas, and 1 percent are facial nerve schwannomas. The remaining 1.5 percent are a variety of malignant or benign tumors near the acoustic or facial nerve (Dickins and Graham, 1991; Brackmann and Arriaga, 1993). If untreated, vestibular schwannomas are eventually fatal in most cases (Monsell and Rock, 1990).

Symptomatology varies greatly, depending upon the size, site, and nature of the tumor. Johnson (1977), reporting on 500 cases of acoustic neuromas, found that 95 percent of the cases revealed unilateral sensorineural hearing loss where 66 percent had a high-frequency hearing loss, 13 percent had a flat hearing loss, 12 percent had a trough configuration, and 9 percent had a low-frequency hearing loss. Similar findings were reported by Nager (1993) and Brackmann and Arriaga (1993). Although unusual, a patient with acoustic schwannoma may reveal normal hearing (Clemis and Masticola, 1976; Musiek et al, 1986). Other symptoms may include tinnitus, disequilibrium without rotary vertigo, facial numbness, aural fullness or pain, and headaches (Jerger and Jerger, 1981; Hart et al, 1983; Weaver and Staller, 1984; Traguina et al, 1989; Monsell and Rock, 1990; Dickins and Graham, 1991; Brackmann and Arriaga, 1993; Nager, 1993).

Tests to determine the presence of an acoustic neuroma may include (a) a comprehensive audiologic evaluation including air, bone, and spondee thresholds, word recognition scores at more than one presentation level, acoustic reflex thresholds, and reflex decay; (b) auditory brainstem response (ABR); (c) electroneurography (ENOG); and (d) evaluation of vestibular function.

\*Department of Otolaryngology, Washington University School of Medicine, St. Louis, Missouri

Reprint requests: Michael Valente, Washington University School of Medicine, 517 South Euclid Ave., St. Louis, MO 63110

The ABR is considered the most powerful audiologic tool for detecting eighth nerve or low brainstem lesions. The sensitivity/specificity of ABRs in detecting acoustic/cerebellopontine angle tumors is between 93 percent and 98 percent (Glasscock et al, 1979; Selters and Brackmann, 1979; Bauch et al, 1982), while the false positive rate has been reported to vary between 8 percent (Selters and Brackmann, 1979) and 23 percent (Bauch et al, 1982) and as high as 30 percent (Clemis and McGee, 1979). Interpreting an ABR includes calculating the (a) absolute latency (in msec) for waveforms I through V; (b) interwave intervals (I-III, III-V, and I-V); (c) interaural latency difference (ILD) for wave V; (d) wave I/V amplitude ratio; and (e) determining the wave V latency shift with increased stimulus repetition rate. Common findings include delay in absolute latency of waveforms, prolongation of the wave I-III, III-V, and I-V interwave intervals, and a significant ILD of wave V. The cases reported in this paper demonstrate the importance of the ILD in detecting acoustic tumors. At our facility, an ILD greater than 0.3 msec is considered a positive indicator of retrocochlear involvement. In some patients, complete absence of ABR waveforms may occur along with the exclusive presence of wave I.

ENOG, as described by Gantz et al (1984), has become an important clinical tool for diagnosis and prognosis of patients with acute idiopathic facial paralysis. ENOG involves supra-maximal peripheral stimulation of the facial nerve with recording of the compound muscle action potential and comparing the response amplitude of the affected to the nonaffected side. From these measures, a percentage of amplitude reduction is calculated. Average interside difference has been reported from 3 percent (Esslen, 1977) to 50 percent, with an average of 20 percent (May et al, 1983). Based on this data, an interside amplitude difference of 20 percent or greater is considered significant.

Vestibular and balance testing may include evaluating (a) the vestibulo-ocular reflex (VOR); (b) the vestibulo-spinal reflex (VRS); (c) visual tracking (i.e., smooth pursuit, gaze, and saccadic); (d) positional (static position) and positioning (Hallpike) nystagmus; and (e) the somatosensory system. In addition, caloric stimulation examines the low-frequency sensitivity of the lateral semicircular canal VOR. Further evaluation of the visual and VOR function can be performed during broad frequency (0.01-1.0 Hz) rotary chair testing with and without visual targets.

Positional evaluation with dynamic platform posturography (EquiTest) includes the Sensory Organization Test, which comprises six conditions that contain combinations of visual surround and support surface movement. In general, patients with acute unilateral or bilateral vestibular disease have significant difficulty with Condition 5 (eyes closed, platform in motion) and/or Condition 6 (eyes open, platform and visual surround in motion). Furthermore, patients with chronic compensated unilateral vestibular disease (including slow growing tumors) usually have normal platform test results.

Unfortunately, no vestibular test is specific for acoustic neuromas. Studies have shown the existence of normal caloric responses in MRI proven acoustic tumors (Guyot et al, 1992; Olson et al, 1992; Thomsen et al, 1992). Others have reported positional nystagmus as a possible clue for the presence of a neuroma (Haid et al, 1992). In addition, large tumors with cerebellar and/or brainstem compression can cause a variety of oculomotor dysfunctions, which include gaze nystagmus, Brun's nystagmus, saccadic dysmetria, and abnormal smooth pursuit/optokinetic tracking. None of these findings, however, is specific for neuromas and, conversely, the absence of caloric or oculomotor dysfunction does not rule out a tumor.

The major role of vestibular testing in patients with acoustic tumors is the status of the opposite ear and the flexibility of the central nervous system in producing compensation of the lesion. Following surgical removal of the tumor, the patient's recovery depends upon the accurate utilization of residual contralateral vestibular cues. Vestibular testing, therefore, is critical to define the status of the central nervous system and the contralateral labyrinth for designing rehabilitative strategies in the postoperative period.

As mentioned earlier, some magnitude of unilateral hearing loss is present in 95 percent of patients with acoustic neuromas. However, this report will illustrate four patients evaluated at our clinic in whom hearing was within normal limits bilaterally, but who had a variety of complaints that served as "red flags" to pursue whether or not an acoustic tumor was present.

## CASE REPORTS

### Case 1

Five years ago, this 30-year-old female reported acute onset of vertigo, nausea, and

intermi  
fled hea  
pressur  
symptom  
loud sou  
cian rep  
films re  
left sid  
"vestib  
URIL,

-20-  
0-  
20-  
40-  
60-  
80-  
100-  
120-

-20  
0  
20  
40  
60  
80  
100  
120

Hearing Level (dB)  
Hearing Level (dB)  
Figur  
the fo

intermittent vomiting. She also reported "muffled hearing" when she experienced fullness, pressure, and tinnitus in the left ear. These symptoms appeared after prolonged exposure to loud sounds (i.e., Tullio phenomenon). Her physician reported that "the internal auditory canal films revealed questionable enlargement on the left side" and determined that the patient had "vestibular neurinitis" and prescribed HydroDIURIL, Antivert, and Pavabid.

Her symptoms continued and she was evaluated at this institution. She reported tinnitus ("hum") in the left ear and occasional vertigo. The audiometric results (Fig. 1A) revealed normal hearing bilaterally. However, hearing was 5 to 15 dB poorer in the left ear. Spondee thresholds, word recognition scores, and tympanograms were normal. Contralateral acoustic reflex thresholds for the left ear were elevated or absent at 500 to 4000 Hz. Reflex decay was normal.

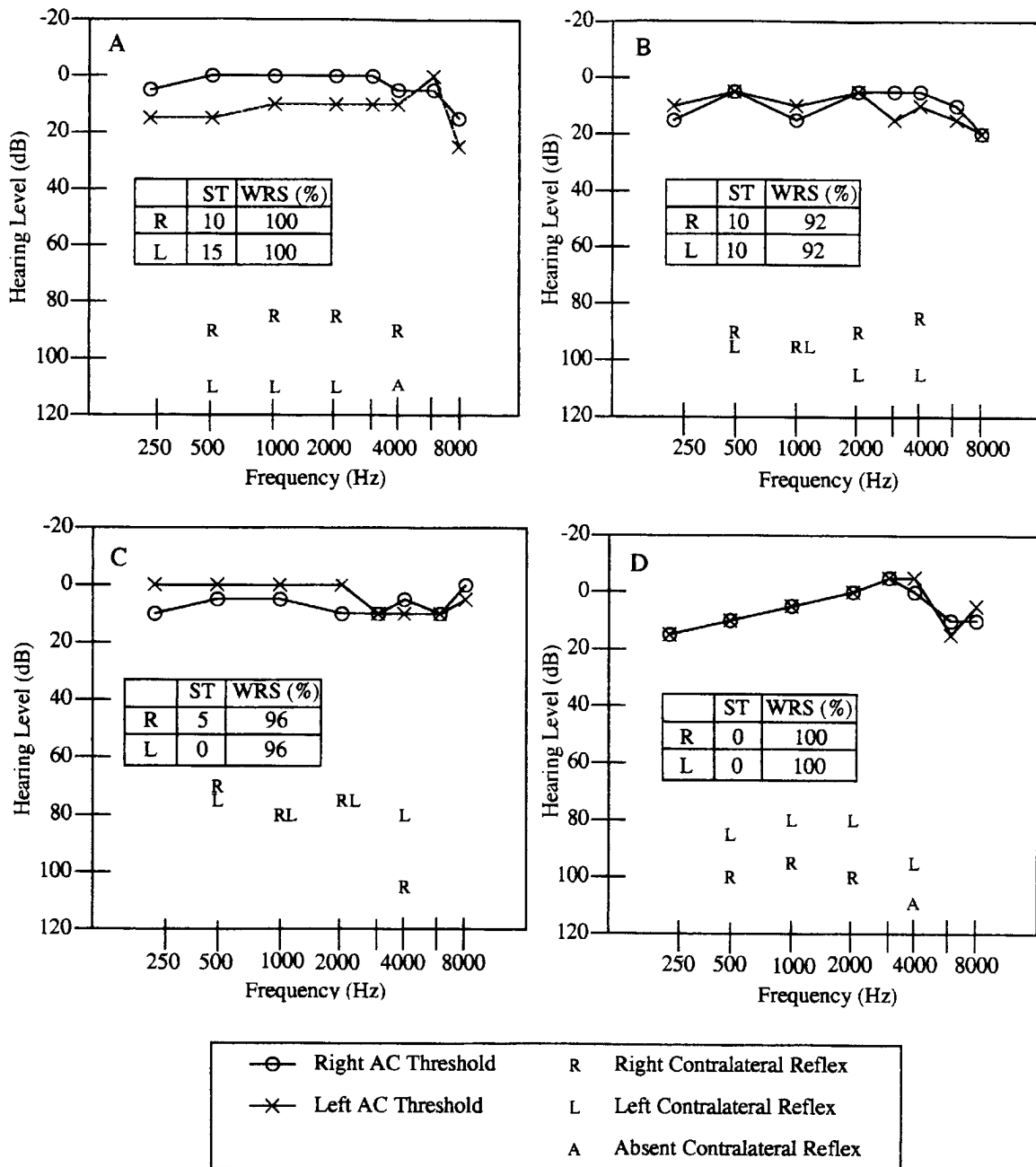


Figure 1 Air-conduction thresholds, spondee thresholds, word recognition scores, and acoustic reflex thresholds for the four cases.

For the four subjects, ABRs were measured using click stimuli at 70 dB nHL with repetition rates of 11.1 and 21.1/sec delivered via standard audiometric earphones (subjects 1 and 4) or TIP 300 insert earphones (subjects 2 and 3). The use of the TIP 300 insert earphones introduced a delay of approximately 0.8 msec in stimulus delivery, which resulted in an equivalent delay in the absolute waveform latency. The bandpass filter was set at 150 to 3000 Hz and the recording sensitivity was adjusted to 20 microvolts. The number of averages per trial varied from 1000 to 2000 for the four subjects. Two-channel vertical recordings were obtained with silver disc recording electrodes placed at the vertex and bilaterally at the earlobes. A ground electrode was placed at the forehead. Only ipsilateral recordings are displayed in Figure 2, A-D.

ABR results for the first case (see Fig. 2A) were within normal limits bilaterally. However, a significant wave V asymmetry was noted (0.52 msec), suggesting retrocochlear involvement on the left side. In addition, the wave I-V

interpeak latency for the left side was prolonged (4.32 msec) when compared to the right ear.

ENG was performed using bitemporal electrode placement and four-channel recording. There was a 6 to 8 degrees right beating nystagmus seen only in right gaze. There was no post-headshake nystagmus. Positional and positioning testing was negative for nystagmus. Finally, bithermal binocular caloric irrigation produced symmetric nystagmus. Fixation suppression of the caloric-induced nystagmus was normal. Dynamic platform posturography was within normal limits.

An MRI revealed a small left cerebellopontine angle lesion consistent with an acoustic schwannoma that completely filled and enlarged the left internal auditory canal.

Facial electromyographic (EMG) activity was monitored throughout surgery. Significant EMG activity was noted primarily during tumor manipulation and dissection. Several bursts and several sustained trains of EMG activity were noted throughout surgery. Following complete tumor removal, stimulation of the facial

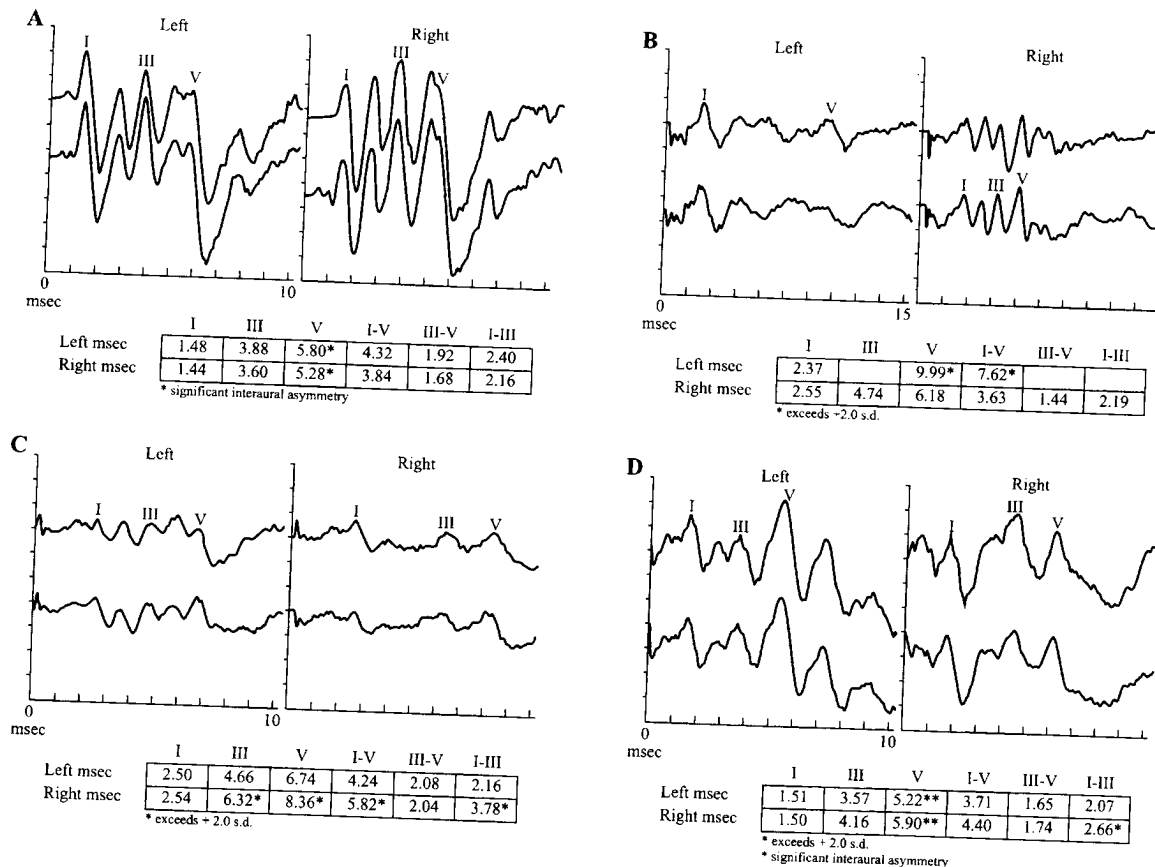


Figure 2 Preoperative ABR test results from the four cases.

nerve resulted in replicated EMG recordings consistent with facial nerve continuity. Slight left facial weakness was noted postoperatively. Long-term left facial nerve function was excellent.

## Case 2

This 51-year-old female reported a "faint pounding" tinnitus in the left ear as well as pain and numbness on the left side of her jaw for 2 months. She reported no problems related to hearing. Her physician suggested that she see her dentist for a tooth extraction and root canal. Neither of these two procedures alleviated the pain. The pain and numbness continued and she complained of intermittent left-sided headaches and mild problems with balance. Her physician ordered an MRI, which revealed a 5-cm left cerebellopontine angle tumor with a large extension into the internal auditory canal.

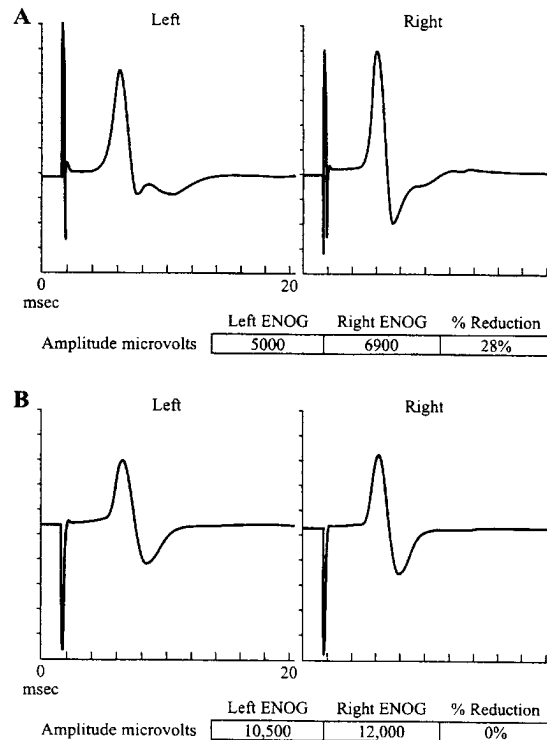
She was seen at our facility and the audiometric evaluation (see Fig. 1B) revealed normal hearing bilaterally. Spondee thresholds, word recognition scores, and tympanograms were normal. Acoustic reflex thresholds for contralateral stimulation to the left ear were elevated at 2000 and 4000 Hz. Reflex decay was difficult to interpret due to wide needle excursions.

ABR (see Fig. 2B) for the left ear revealed wave I present at a normal absolute latency with a significant delay of wave V (approximately 10 msec with a stimulus level of 90 dB nHL). Waveform morphology was poor with poor repeatability of waves II, III, and IV. The wave I-V interwave latency was significantly prolonged (7.6 msec).

ENOG (Fig. 3A) revealed compound muscle action potential response amplitudes of 5000 microvolts and 6900 microvolts for the right and left sides, respectively. These results were consistent with a 28 percent reduction in the left facial EMG response amplitude compared to the right. Results suggested a slight subclinical facial nerve involvement.

ENG was performed using bitemporal electrode placement and four-channel recording. Results revealed (a) symmetric but suppressed caloric responses bilaterally; and (b) biphasic post-headshake nystagmus with the initial phase beating toward the right (normal) side. Dynamic platform posturography was within normal limits.

Bilateral suppressed caloric responses can occur for many reasons (alertness, medications, inhibition, central compensation, or true bilateral vestibulopathy). In this case, the presence of a left acoustic tumor is probably the cause of



**Figure 3** Preoperative ENOG test results from two cases.

the suppressed left caloric. The suppressed caloric response in the opposite ear is likely a result of central suppression by the cerebellum to compensate for the static and, to some extent, dynamic low-frequency asymmetry in the end organ system. The presence of a post-headshake nystagmus beyond 2-Hz stimulation with the initial phase beating toward the intact ear is good evidence for persistent dynamic asymmetry at higher frequencies. The presence of post-headshake nystagmus has been reported in both acute and chronic vestibular injuries, with the fast phase usually beating towards the intact side (Hain et al, 1987; Wei et al, 1989; Goebel and Garcia, 1992).

The patient underwent a combined translabyrinthine/suboccipital approach to remove the left acoustic tumor. ABR and facial EMG monitoring were conducted throughout surgery. The ABR was lost during translabyrinthine craniectomy surgery and the facial nerve was extremely thinned and elongated by the tumor. Due to the size of the tumor and involvement of the facial and auditory nerves, both nerves were sacrificed in order to achieve complete tumor resection. Three weeks later, a hypoglossal-facial nerve anastomosis was performed.

Due to the complete loss of hearing in the left ear, the patient was counseled on the potential benefits of a right CROS or transcranial CROS fitting (Valente et al, 1994a, b). At the present time, the patient has chosen not to pursue either recommendation.

### Case 3

This 31-year-old male had a sudden hearing loss in the right ear for 2 weeks, which gradually improved. In his right ear, he reported pressure but no vertigo, intermittent "high-pitched" tinnitus, and occasional numbness of his left arm and leg. The reports of numbness lead to an MRI, which revealed a 1-cm acoustic tumor on the right side that filled the internal auditory canal and extended approximately 1 cm into the cerebellopontine angle.

The audiometric evaluation (see Fig. 1C) revealed normal hearing at 250 to 8000 Hz. Spondee thresholds, word recognition scores, and tympanograms were normal. Contralateral acoustic reflex thresholds to the right ear were normal at 500 to 2000 Hz but elevated at 4000 Hz. An audiometric exam 3 months later revealed a moderate severe sensorineural hearing loss at 1500 to 8000 Hz in the right ear. A word recognition score of 60 percent was revealed at 45 dB SL (re: ST) and improved to 86 percent at 55 dB SL. Also, reflex decay was present at 500 to 1000 Hz and contralateral and ipsilateral reflex thresholds were elevated or absent at 1000 to 4000 Hz.

ABR (see Fig. 2C) for the right ear revealed a significant delay in the absolute latency for waves III and V, with a significant prolongation of the wave V latency (0.74 msec) with increased stimulus repetition rate also noted on the right side.

ENG was performed using bitemporal electrode placement and four-channel recording. The patient had normal oculomotor function including saccades and smooth pursuit. There was no gaze nystagmus. There was a low-amplitude left-beating post-headshake nystagmus (PHN). Positional and positioning testing was negative for nystagmus. Finally, bithermal binaural caloric irrigation revealed a 100 percent reduced response on the right. Ice water (18C) produced low but symmetric responses bilaterally. Fixation suppression of the caloric-induced nystagmus was normal. Dynamic platform posturography (Equitest) showed normal scores for all six conditions of the Sensory Organization Test. In addition,

center of gravity alignment and muscle reflex latencies were normal.

The patient underwent a suboccipital approach for removal of the tumor. ABR and facial EMG monitoring were conducted throughout surgery. The ABR was extremely degraded, with wave V only present at a very delayed latency. During removal of the tumor, wave V disappeared. EMG findings consisted of almost constant train activity during drilling within the internal auditory canal. Tumor dissection along the facial nerve also resulted in three additional trains of 1- to 2-minute duration as well as several bursts of EMG activity. Following complete tumor removal, stimulation of the facial nerve at the brain stem resulted in an EMG response of > 200 microvolt amplitude. Immediate postoperative facial nerve function was excellent. After recovery, the patient will be counseled on the potential benefits of a left CROS or transcranial CROS fitting.

### Case 4

This 27-year-old female reported intermittent right tinnitus, episodic vertigo, nausea, and occasional facial twitching on the right side. She had no complaints relative to hearing sensitivity.

The audiometric evaluation (see Fig. 1D) revealed normal hearing at 250 to 8000 Hz. Spondee thresholds, word recognition scores, and tympanograms were normal. Contralateral acoustic reflex thresholds at 500 to 4000 Hz were elevated or absent for the right ear and reflex decay was normal.

ABR (see Fig. 2D) for the right side revealed that all absolute latencies for waves I-V were within normal limits. The I-III interwave interval was prolonged for the right side, with all other interwave intervals within normal limits. The strongest finding was a significant wave V interaural asymmetry (0.69 msec). Results were consistent with retrocochlear dysfunction on the right side.

ENOG (see Fig. 3B) revealed compound muscle action potential amplitude of 10.5 microvolts and 12.0 microvolts for the left and right sides, respectively. Results were not consistent with a reduction in right facial EMG response amplitude as compared to the left.

The patient underwent a suboccipital approach for removal of the tumor. ABR and facial EMG monitoring were conducted throughout surgery. The ABR remained stable throughout tumor exposure; however, during removal of the tumor along the auditory nerve, the ABR

disappeared. EMG recordings consisted of frequent bursts of EMG activity as well as several sustained trains. Following complete tumor removal, stimulation of the facial nerve resulted in a large amplitude EMG response (>800 microvolts). Immediate postoperative facial nerve function was excellent with a slight facial weakness noted at discharge. After recovery, the patient will be counseled on the potential benefits of a left CROS or transcranial CROS fitting because of the resulting profound hearing loss in the right ear.

### DISCUSSION

Due to numerous experiences with cases similar to the ones described above, our facility has always had a policy that any patient reporting unilateral tinnitus will be treated as if it indicated an acoustic tumor until proven otherwise. Our protocol includes a comprehensive audiometric evaluation that includes tympanometry, acoustic reflex thresholds, and decay. In addition, an ABR will be strongly recommended, as well as an ENOG, if the patient reports any facial abnormalities.

In each case described above, the one common denominator was patient reports of unilateral tinnitus. Three patients reported some problems with dizziness or vertigo while two patients reported problems with unilateral facial twitching, pain, or numbness. In addition, two patients reported a unilateral sensation of pressure.

From an audiometric viewpoint, all revealed elevated or absent acoustic reflex thresholds at one or more frequencies, while reflex decay was normal. Finally, all patients revealed abnormal ABR findings. The variety of abnormalities included interaural asymmetry of wave V latency; delays of waves III, IV, or V; or prolongation of interwave intervals of I-III or I-V.

The relative value of vestibular studies in patients with acoustic neuromas depends upon the reason for which the studies were requested. None of the vestibulo-ocular (ENG, rotary chair, headshake) or posturographic tests (visual, vestibular, and somatosensory input) are specific for identifying or excluding acoustic neuromas. These tests are important, however, to quantify the functional state of the VOR and posture control mechanisms before and after surgery to plan appropriate rehabilitative strategies. Successful rehabilitation depends upon (1) the functioning of the intact labyrinth and (2) the visual

compensatory ability of the central nervous system to integrate visual and somatosensory inputs with the remaining vestibular information. For this reason, preoperative vestibular studies enhance the overall management strategy for acoustic neuroma patients after diagnosis is firmly established by other means.

### REFERENCES

- Bauch C, Rose D, Harner S. (1982). Auditory brainstem response results from 255 patients with suspected retrochlear involvement. *Ear Hear* 3:83-86.
- Brackmann DE, Arriaga MA. (1993). Differential diagnosis of neoplasms of the posterior fossa. In: Cummings CW, Fredrickson JM, Harker LA, Krause CJ, Schuller DE, eds. *Otolaryngology-Head and Neck Surgery* (2nd Ed.). St. Louis: Mosby Year Book, 3271-3291.
- Clemis JD, Mastricola PG. (1976). Special audiometric test battery in 121 proven acoustic tumors. *Arch Otolaryngol* 102:654-656.
- Clemis JD, McGee T. (1979). Brainstem electric response audiometry in the differential diagnosis of acoustic tumors. *Laryngoscope* 89:31-42.
- Dickins JRE, Graham SS. (1991). Differential diagnosis of tumors at the cranial base. In: Jackson CG, ed. *Surgery of Skull Base Tumors*. New York: Churchill Livingstone, 1-17.
- Esslen E. (1977). *The Acute Facial Palsies*. Berlin: Springer-Verlag.
- Gantz BJ, Holliday M, Gmuer AA, Fisch U. (1984). Electroneurographic evaluation of the facial nerve: method and technical problems. *Ann Otol Rhinol Laryngol* 93:394-398.
- Glasscock M, Jackson C, Josey A, Dickins J, Wiet R. (1979). Brainstem evoked response audiometry in clinical practice. *Laryngoscope* 89:1021-1034.
- Goebel JA, Garcia P. (1992). Prevalence of post-headshake nystagmus in patients with caloric deficits and vertigo. *Otolaryngol Head Neck Surg* 106:121-127.
- Guyot JP, Hausler R, Reverdin A, Berney J, Montandon PB. (1992). The value of otoneurologic diagnostic procedures compared with radiological and operative findings. In: Tos M, Thomsen J, eds. *Acoustic Neuroma*. Amsterdam: Kugler Publications, 31-37.
- Haid CT, Christ P, Wolf SR, Wigand ME. (1992). Clinical suspicion of an acoustic neuroma: a neuro-otological review of 302 operated cases. In: Tos M, Thomsen J, eds. *Acoustic Neuroma*. Amsterdam: Kugler Publications, 39-44.
- Hain TC, Fetter M, Zee DS. (1987). Headshaking nystagmus in patients with unilateral peripheral vestibular lesions. *Am J Otolaryngol* 8:36-47.
- Hart RG, Gardner DP, Howieson J. (1983). Acoustic tumors: atypical features and recent diagnostic tests. *Neurology* 33:211-221.
- Jerger S, Jerger J. (1981). Acoustic schwannoma. In: *Auditory Disorders. A Manual for Clinical Evaluation*. Boston: Little, Brown and Company, 1-11.



- Johnson EW. (1977). Auditory tests in 500 cases of acoustic neuromas. *Arch Otolaryngol* 103:152-158.
- May M, Klein SR, Blumenthal F. (1983). Evoked electromyography and idiopathic facial paralysis. *Otolaryngol Head Neck Surg* 6:678-685.
- Monsell EM, Rock JP. (1990). Sensorineural hearing loss and the diagnosis of acoustic neuroma. *Henry Ford Hosp Med J* 38(1):9-12.
- Musiek FE, Josey A, Kibbe-Michal K, Geurkink N, Glasscock M. (1986). ABR results in patients with posterior fossa tumors and normal pure-tone thresholds. *Arch Otolaryngol* 94:868-873.
- Nager GT. (1993). *Pathology of the Ear and Temporal Bone*. Baltimore: Williams and Wilkins.
- Olsson JE, Barrs DM, Krueger WO, Gibbons DR. (1992). Use of receiver operating curves in the design of diagnostic strategies for retrocochlear lesions. In: Tos M, Thomsen J, eds. *Acoustic Neuroma*. Amsterdam: Kugler Publications, 77-81.
- Selters WA, Brackmann DE. (1979). Brainstem electric response audiometry: acoustic tumor detection. In: House W, Luetje C, eds. *Acoustic Tumors (Vol. 1)*. Baltimore University Park Press, 225-235.
- Thomsen J, Tos M, Moller H. (1992). Diagnostic strategies in acoustic neuroma surgery: findings in 504 cases. In: Tos M, Thomsen J, eds. *Acoustic Neuroma*. Amsterdam: Kugler Publications, 69-72.
- Traguina DN, Guttenberg I, Sasaki CT. (1989). Delayed diagnosis and treatment of acoustic neuroma. *Laryngoscope* 99:814-818.
- Valente M, Valente M, Meister M, Macauley K, Vass V. (1994a). Selecting and verifying hearing aid fittings for unilateral hearing loss. In: Valente M, ed. *Strategies for Selecting and Verifying Hearing Aid Fittings*. New York: Thieme Medical Publishers, 228-248.
- Valente M, Valente M, Potts L, Goebel J. (1994b). CROS versus transcranial CROS for unilateral hearing loss. *Am J Audiol* (in press).
- Weaver M, Staller SJ. (1984). The acoustic nerve tumor. In: Northern JL, ed. *Hearing Disorders* (2nd ed.). Boston: Little, Brown and Company, 171-177.
- Wei D, Hain TC, Proctor LR. (1989). Headshaking nystagmus: associations with canal paresis and hearing loss. *Acta Otolaryngol (Stockh)* 108:362-367.

"N  
W  
Jan  
Kay  
Fran

T  
ture  
be s  
deal  
in th  
of th  
The  
sens  
may  
of th  
tion  
brain  
the  
to d  
ciple  
prec  
whe  
ABB

of M  
of A  
Leba  
Neur  
New  
Com  
Box