

Washington University School of Medicine

Digital Commons@Becker

---

Open Access Publications

---

11-1-2020

## Detection of a somatic GREB1-NCOA1 gene fusion in a uterine tumor resembling ovarian sex cord tumor (UTROSCT)

Whitney R Grither

*Washington University School of Medicine in St. Louis*

Brendan C Dickson

*University of Toronto*

Katherine C Fuh

*Washington University School of Medicine in St. Louis*

Ian S Hagemann

*Washington University School of Medicine in St. Louis*

Follow this and additional works at: [https://digitalcommons.wustl.edu/open\\_access\\_pubs](https://digitalcommons.wustl.edu/open_access_pubs)


**Please let us know how this document benefits you.**

---

### Recommended Citation

Grither, Whitney R; Dickson, Brendan C; Fuh, Katherine C; and Hagemann, Ian S, "Detection of a somatic GREB1-NCOA1 gene fusion in a uterine tumor resembling ovarian sex cord tumor (UTROSCT)." *Gynecologic Oncology Reports*. 34, 100636 (2020).  
[https://digitalcommons.wustl.edu/open\\_access\\_pubs/9596](https://digitalcommons.wustl.edu/open_access_pubs/9596)

This Open Access Publication is brought to you for free and open access by Digital Commons@Becker. It has been accepted for inclusion in Open Access Publications by an authorized administrator of Digital Commons@Becker. For more information, please contact [vanam@wustl.edu](mailto:vanam@wustl.edu).



## Case report

Detection of a somatic *GREB1-NCOA1* gene fusion in a uterine tumor resembling ovarian sex cord tumor (UTROSCT)Whitney R. Grither<sup>a</sup>, Brendan C. Dickson<sup>c,d</sup>, Katherine C. Fuh<sup>a</sup>, Ian S. Hagemann<sup>a,b,\*</sup><sup>a</sup> Department of Obstetrics and Gynecology, Washington University School of Medicine, St. Louis, MO, USA<sup>b</sup> Department of Pathology and Immunology, Washington University School of Medicine, St. Louis, MO, USA<sup>c</sup> Department of Laboratory Medicine and Pathobiology, University of Toronto, Toronto, ON, Canada<sup>d</sup> Department of Pathology and Laboratory Medicine, Mount Sinai Hospital, Toronto, ON, Canada

## ARTICLE INFO

## Keywords:

Uterine tumor resembling ovarian sex cord tumor  
 RNA-sequencing  
 Fusion gene  
 Uterine tumors  
 Pathology

## ABSTRACT

Uterine tumor resembling ovarian sex cord tumor (UTROSCT) is a rare uterine neoplasm of uncertain malignant potential. We present the case of a 69-year-old woman who underwent hysterectomy for postmenopausal bleeding and was found to have a myometrial UTROSCT. RNA-sequencing identified a somatic *GREB1-NCOA1* fusion, supporting the diagnosis. Next-generation sequencing is increasingly being adopted in diagnostic pathology laboratories. This report highlights the value of RNA-sequencing in identifying rare fusion events to support pathologic diagnoses.

## 1. Introduction

Uterine tumor resembling ovarian sex cord tumor (UTROSCT) is a mesenchymal neoplasm with predominantly sex cord-like differentiation, classified by the World Health Organization as a subset of endometrial stromal and related neoplasms. Fewer than 100 cases of UTROSCT have been published since the entity was first described (Schraag et al., 2017), and it is clearly a rare entity, although the true incidence is difficult to estimate due to its rarity and the historical absence of a reliable diagnostic marker. UTROSCT usually occurs in middle-aged women (average age of 50 years) who present with abnormal bleeding or pelvic pain (Blake et al., 2014; Clement and Scully, 1976). Hysterectomy with or without bilateral salpingo-oophorectomy is considered standard treatment for these neoplasms. While typically considered to be of low malignant potential, a recent series documented extrauterine metastasis in 8 of 34 patients (Moore and McCluggage, 2017). Although referral bias is likely to be present, the non-negligible rate of malignant behavior underscores the need for accurate diagnostic tools for such patients.

Sex cord-like elements are present in a variety of uterine neoplasms. They can be a focal pattern within endometrioid adenocarcinoma, or can be mimicked by adenosarcoma, carcinosarcoma, or smooth muscle tumors. Once these mimickers are excluded, uterine tumors with a bona fide sex cord-like element have been divided into two groups: group I tumors, known as endometrial stromal tumors with sex cord-like

elements (ESTSCLE), and group II tumors, comprising classic UTROSCTs. A recent systematic review showed that subcategorization is often not reported, but that group I tumors have the greater malignant potential of the two, with disease-free survival at 2 years being 23.8% for group I, but 100% for group II (Blake et al., 2014). Group I tumors contain focal sex cord-like elements (although > 10% by definition), and these tumors appear to be closely related to low-grade endometrial stromal sarcomas, sometimes harboring characteristic genetic rearrangements such as *JAZF1-SUZ12*. Group II tumors appear to be a separate entity (Blake et al., 2014; Clement and Scully, 1976). Molecular features of UTROSCT were elusive until RNA sequencing (RNA-seq) revealed recurrent *NCOA1* rearrangements (Dickson et al., 2019; Goebel et al., 2020), usually partnering with estrogen receptor 1 (*ESR1*) or growth regulation by estrogen in breast cancer (*GREB1*).

Here we report a case of a 69-year-old woman with a uterine tumor. The histopathologic findings were initially equivocal, but RNA-seq identified a diagnostic *GREB1-NCOA1* fusion, supporting classification as UTROSCT.

## 2. Case summary

The patient provided consent for publication. A 69-year-old woman with past medical history significant for breast cancer (stage I ER/PR-positive, HER-2-negative invasive ductal carcinoma diagnosed in 2010) presented with postmenopausal bleeding and underwent hysteroscopy

\* Corresponding author at: 425 S. Euclid Ave., Campus Box 8118, St. Louis, MO 63110, USA.

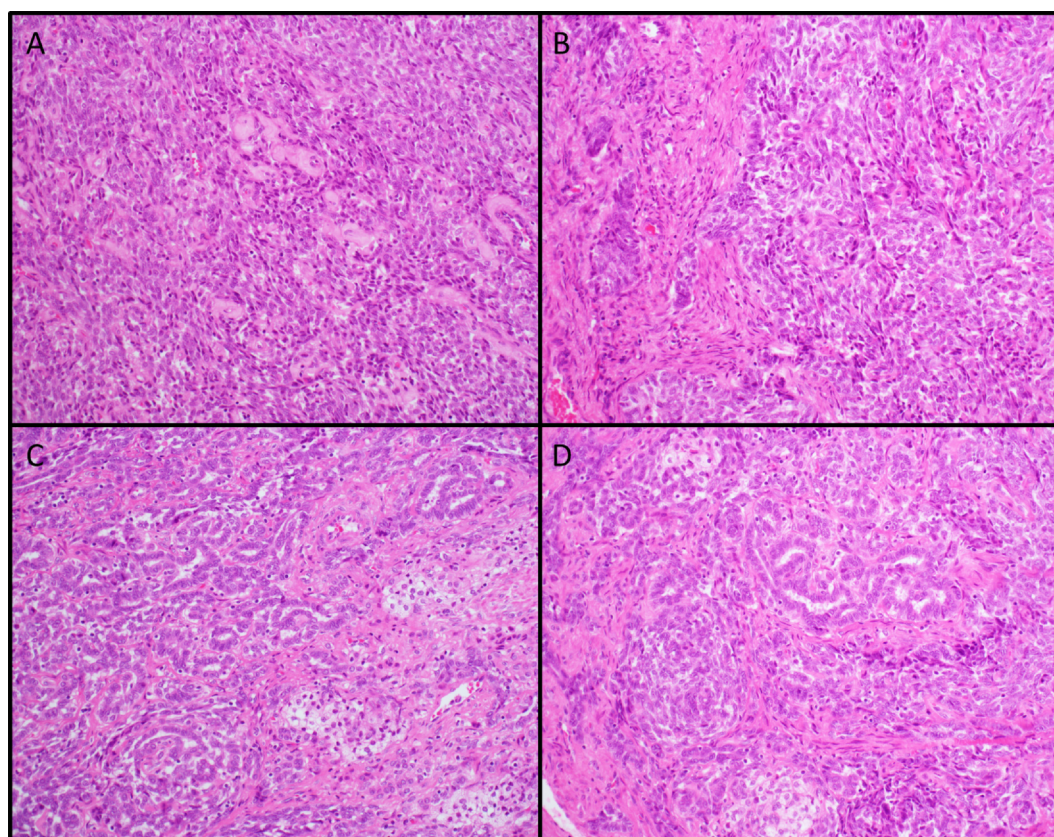
E-mail address: [hagemani@wustl.edu](mailto:hagemani@wustl.edu) (I.S. Hagemann).

<https://doi.org/10.1016/j.gore.2020.100636>

Received 30 June 2020; Received in revised form 24 August 2020; Accepted 30 August 2020

Available online 06 September 2020

2352-5789/ © 2020 The Author(s). Published by Elsevier Inc. This is an open access article under the CC BY-NC-ND license (<http://creativecommons.org/licenses/by-nc-nd/4.0/>).



**Fig. 1.** (A) Spindled elements of tumor. H&E stain, 200x original magnification. (B) Spindled elements at edge of tumor, 200x. (C) Sex cord-like elements of tumor, 200x. (D) Juxtaposition of spindled and sex cord-like areas, 200x.

and D&C in 2016, with removal of a benign endometrial polyp. She had a recurrent episode of postmenopausal bleeding in February 2019. A transvaginal ultrasound at that time demonstrated a thickened endometrium at 1.2 cm, as well as an isoechoic 3.9 cm mass within the myometrium without mass effect on adjacent endometrium. Repeat D&C in early 2019 revealed no evidence of malignancy. The patient remained symptomatic and desired definitive management. In July 2019, she underwent robotic-assisted total laparoscopic hysterectomy and bilateral salpingo-oophorectomy. Operative findings were notable for normal uterus, tubes and ovaries, vaginal strictures and atrophy, a 2 cm inclusion cyst on the anterior uterine serosa, and adhesions from ascending and descending colon to pelvic sidewalls.

Gross examination of the bivalved uterus showed a  $5.2 \times 4.1 \times 3.2$  cm tan-white, well delineated, focally necrotic-appearing mass. Histology showed a stromal tumor within the myometrium, with several histologic components (Fig. 1). One component consisted of cells with small to medium-sized, round to oval nuclei and inconspicuous cytoplasm, resembling cells of low-grade endometrial stromal sarcoma, with a mitotic rate of approximately 1 per 10 high-power fields. Other more peripheral areas showed similar cells arranged in cords, tubules and other pseudoglandular configurations, resembling patterns that can be seen in granulosa cell tumors of the ovary, also with aggregates of foamy macrophages. Each component was noted to make up close to 50% of the volume of the tumor. The growth habitus appeared expansile, but on microscopic examination, the sex cord elements peripherally infiltrated the myometrium. Margins and serosa were negative, and lymphovascular invasion was absent. Immunostains showed tumor cells to be positive for CD10, pancytokeratin (sex cord elements only), progesterone receptor, calretinin, and vimentin, very weakly positive for estrogen receptor, and negative for smooth muscle actin. Inhibin showed multifocal but strong positivity, mainly in the sex cord-like component.

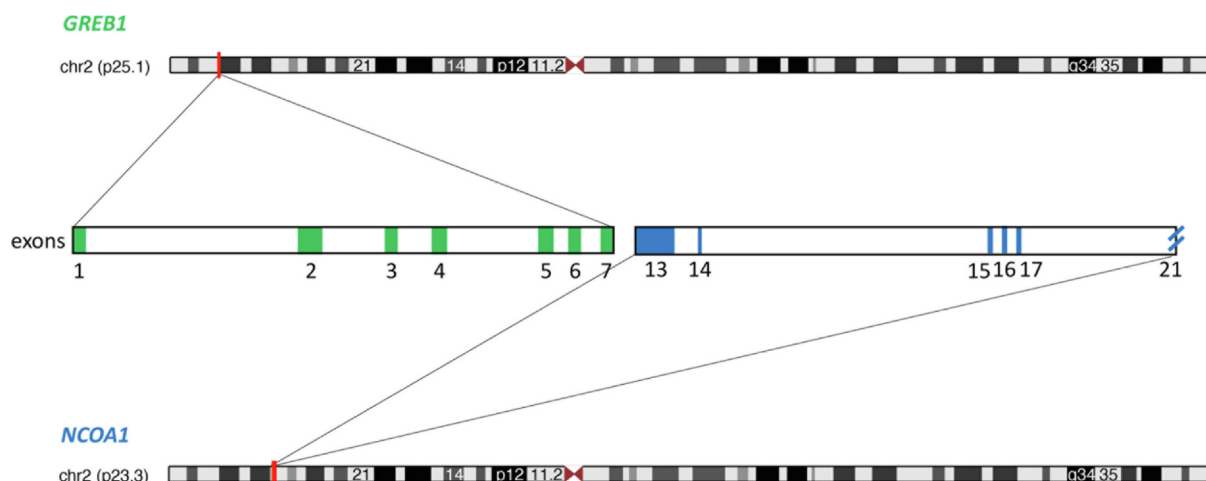
Several diagnoses were considered. Less likely entities included carcinosarcoma, adenosarcoma and dedifferentiated endometrioid adenocarcinoma. More probable entities included low-grade endometrial stromal sarcoma, endometrial stromal tumor with sex cord-like elements (ESTSCLE) or uterine tumor resembling ovarian sex cord tumors (UTROSCT). Fluorescence in situ hybridization was negative for *JAZF1*, *PHF1*, or *YWHAE* rearrangements. RNA-seq (Dickson et al., 2019) identified a fusion between *GREB1* (NCBI Reference Sequence: NM\_014668.3; exon 7 of 33) and *NCOA1* (NM\_003743.4; exon 13 of 21) (Fig. 2). The presence of a somatic *GREB1-NCOA1* fusion supported a definitive diagnosis of UTROSCT.

The patient recovered from surgery without complication and was seen at 2 and 6 weeks postoperatively. No adjuvant therapy was felt to be indicated. She was without apparent disease at an 8-month post-operative interval.

### 3. Discussion

The current World Health Organization (WHO) classification includes UTROSCT under the category of “endometrial stromal and related tumors”. However, these tumors do not resemble ovarian sex cord-stromal tumors nor uterine stromal neoplasms at a molecular level, despite their morphologic resemblance (Croce et al., 2016; Staats et al., 2009). Recently, a small number of studies have identified molecular alterations strongly associated with UTROSCT. A recent study showed recurrent *NCOA2/3* gene fusions in 4 UTROSCTs (*ESR1-NCOA3*,  $n = 2$ ; *ESR1-NCOA2*,  $n = 1$ ; *GREB1-NCOA2*,  $n = 1$ ) (Dickson et al., 2019). A subsequent report characterized the features of 4 *GREB1*-rearranged uterine sarcomas (*GREB1-NCOA1*, *GREB1-NR4A3*, *GREB1-SS18*, and *GREB1-NCOA1*), as well as 4 classic UTROSCT harboring *ESR1-NCOA3* (Lee et al., 2019). The *GREB1*-rearranged sarcomas were said to have limited sex cord differentiation, but





**Fig. 2.** Ideogram depicting the presumed chromosome 2 rearrangement resulting in fusion of *GREB1* exons 1–7 with *NCOA1* exons 13–21. Adapted from the UCSC Genome Browser, <http://genome.ucsc.edu> (Kent et al., 2002).

our case with *NCOA1-GREB1* showed reasonably strong sex cord features.

In response to those initial studies, Goebel et al. sought to further describe the molecular characteristics of this rare tumor using a larger cohort of 26 UTROSCT cases. A majority of cases showed *NCOA1*, *NCOA2*, or *NCOA3* gene fusions (18/22). The most commonly identified fusion partners were *ESR1* or *GREB1* (17/22). Further, a subset of the UTROSCTs were analyzed for alterations characteristic of low-grade stromal neoplasms (*JAZF1-SUZ12* translocations and *PHF1* rearrangements), all of which were negative (Goebel et al., 2020).

*ESR1* (estrogen receptor 1) is a ligand-dependent transcription factor and *GREB1* (growth regulation by estrogen in breast cancer) is expressed in all *ESR1*-expressing tissues, and is a mediator of estrogen activity (Dickson et al., 2019). *NCOA1-3* genes encode a family of nuclear receptor co-activators (p160/Src family) that, when bound to nuclear receptors, stimulate transcription in a hormone-dependent manner. Their role in steroid hormone-dependent uterine function and has been described (Szwarc et al., 2014). It has been surmised that these fusions cause uterine disease because *ESR1* and *GREB1* are highly expressed in uterine tissue. The putative fusion oncoproteins retain the active promoter region of *ESR1/GREB1* fused to the nuclear receptor co-activator domain of *NCOA1-3*. This would result in dysregulated expression of the nuclear receptor co-activator domain of *NCOA1-3* (Dickson et al., 2019). Functional studies supporting this hypothesis have not been reported.

Making a distinction between UTROSCT and ESTSCLC may be difficult on morphologic grounds. Given the difference in malignant potential of these two subtypes, however, the distinction is clinically relevant. While optimal postoperative surveillance methods are not standardized at this time, definite diagnosis allows for more appropriate monitoring. With the more aggressive behavior of ESTSCLC, a period of postoperative imaging may be warranted, whereas clinical surveillance alone is likely appropriate for type II (UTROSCT) tumors.

In conclusion, the present case showed a somatic *GREB1-NCOA1* fusion, supporting the diagnosis of UTROSCT. This newly recognized molecular event can aid in distinguishing these rare, apparently indolent tumors from more aggressive morphologic mimics.

#### CRediT authorship contribution statement

**Whitney R. Grither:** Conceptualization, Writing - original draft, Writing - review & editing. **Brendan C. Dickson:** Data curation, Investigation, Methodology, Validation, Writing - review & editing. **Katherine C. Fuh:** Conceptualization, Investigation. **Ian S.**

**Hagemann:** Conceptualization, Writing - review & editing, Data curation, Investigation, Methodology, Project administration, Supervision.

#### References

- Blake, E.A., Sheridan, T.B., Wang, K.L., Takiuchi, T., Kodama, M., Sawada, K., Matsuo, K., 2014. Clinical characteristics and outcomes of uterine tumors resembling ovarian sex-cord tumors (UTROSCT): a systematic review of literature. *Eur. J. Obstet. Gynecol. Reprod. Biol.* 181, 163–170. <https://doi.org/10.1016/j.ejogrb.2014.07.050>. PubMed PMID: 25150955.
- Clement, P.B., Scully, R.E., 1976. Uterine tumors resembling ovarian sex-cord tumors. a clinicopathologic analysis of fourteen cases. *Am. J. Clin. Pathol.* 66 (3), 512–525. <https://doi.org/10.1093/ajcp/66.3.512>. PubMed PMID: 961630.
- Croce, S., de Kock, L., Boshari, T., Hostein, I., Velasco, V., Foulkes, W.D., McCluggage, W.G., 2016. Uterine Tumor Resembling Ovarian Sex Cord Tumor (UTROSCT) commonly exhibits positivity with sex cord markers FOXL2 and SF-1 but lacks FOXL2 and DICER1 mutations. *Int. J. Gynecol. Pathol.* 35 (4), 301–308. <https://doi.org/10.1097/PGP.0000000000000240>. PubMed PMID: 26598979.
- Dickson, B.C., Childs, T.J., Colgan, T.J., Sung, Y.S., Swanson, D., Zhang, L., Antonescu, C.R., 2019. Uterine tumor resembling ovarian sex cord tumor: a distinct entity characterized by recurrent *NCOA2/3* gene fusions. *Am. J. Surg. Pathol.* 43 (2), 178–186. <https://doi.org/10.1097/PAS.0000000000001153>. PubMed PMID: 30273195; PMCID: PMC6719705.
- Goebel, E.A., Hernandez Bonilla, S., Dong, F., Dickson, B.C., Hoang, L.N., Hardisson, D., Lacambra, M.D., Lu, F.I., Fletcher, C.D.M., Crum, C.P., Antonescu, C.R., Nucci, M.R., Kolin, D.L., 2020. Uterine Tumor Resembling Ovarian Sex Cord Tumor (UTROSCT): a morphologic and molecular study of 26 cases confirms recurrent *NCOA1-3* rearrangement. *Am. J. Surg. Pathol.* 44 (1), 30–42. <https://doi.org/10.1097/PAS.0000000000001348>. PubMed PMID: 31464709.
- Kent, W.J., Sugnet, C.W., Furey, T.S., Roskin, K.M., Pringle, T.H., Zahler, A.M., Haussler, D., 2002. The human genome browser at UCSC. *Genome Res.* 12 (6), 996–1006. <https://doi.org/10.1101/gr.229102>. PubMed PMID: 12045153; PMCID: PMC186604.
- Lee, C.H., Kao, Y.C., Lee, W.R., Hsiao, Y.W., Lu, T.P., Chu, C.Y., Lin, Y.J., Huang, H.Y., Hsieh, T.H., Liu, Y.R., Liang, C.W., Chen, T.W., Yip, S., Lum, A., Kuo, K.T., Jeng, Y.M., Yu, S.C., Chung, Y.C., Lee, J.C., 2019. Clinicopathologic characterization of *GREB1*-rearranged uterine sarcomas with variable sex-cord differentiation. *Am. J. Surg. Pathol.* 43 (7), 928–942. <https://doi.org/10.1097/PAS.0000000000001265>. PubMed PMID: 31094921.
- Moore, M., McCluggage, W.G., 2017. Uterine tumour resembling ovarian sex cord tumour: first report of a large series with follow-up. *Histopathology* 71 (5), 751–759. <https://doi.org/10.1111/his.13296>. PubMed PMID: 28656712.
- Schraag, S.M., Caduff, R., Dedes, K.J., Fink, D., Schmidt, A.M., 2017. Uterine tumors resembling ovarian sex cord tumors - treatment, recurrence, pregnancy and brief review. *Gynecol. Oncol. Rep.* 19, 53–56. <https://doi.org/10.1016/j.gore.2017.01.004>. PubMed PMID: 28119954; PMCID: PMC5238603.
- Staats, P.N., Garcia, J.J., Dias-Santagata, D.C., Kuhlmann, G., Stubbs, H., McCluggage, W.G., De Nictolis, M., Kommoss, F., Soslow, R.A., Iafra, A.J., Oliva, E., 2009. Uterine tumors resembling ovarian sex cord tumors (UTROSCT) lack the *JAZF1-JJAZ1* translocation frequently seen in endometrial stromal tumors. *Am. J. Surg. Pathol.* 33 (8), 1206–1212. <https://doi.org/10.1097/PAS.0b013e3181a7b9cf>. PubMed PMID: 19542872.
- Szwarc, M.M., Kommagani, R., Lessey, B.A., Lydon, J.P., 2014. The p160/steroid receptor coactivator family: potent arbiters of uterine physiology and dysfunction. *Biol. Reprod.* 91 (5), 122. <https://doi.org/10.1095/biolreprod.114.125021>. PubMed PMID: 25297546; PMCID: PMC4434928.