

Washington University School of Medicine

Digital Commons@Becker

Open Access Publications

9-1-2020

Technical challenges of heart avoidance for synchronous breast and lung cancers in a postmenopausal female: A planning case report from a safety-net hospital

Christophe Marques
University of Southern California

Joshua Schiff
Washington University School of Medicine in St. Louis

Fahad Momin
University of Southern California

Nicole McAllister
University of Southern California

Richard L Jennelle
University of Southern California

See next page for additional authors

Follow this and additional works at: https://digitalcommons.wustl.edu/open_access_pubs

Please let us know how this document benefits you.

Recommended Citation

Marques, Christophe; Schiff, Joshua; Momin, Fahad; McAllister, Nicole; Jennelle, Richard L; Bian, Shelly X; Schechter, Naomi R; and Yoo, Stella K, "Technical challenges of heart avoidance for synchronous breast and lung cancers in a postmenopausal female: A planning case report from a safety-net hospital." *Advances in Radiation Oncology*. 5, 5. 1076 - 1082. (2020).
https://digitalcommons.wustl.edu/open_access_pubs/9718

This Open Access Publication is brought to you for free and open access by Digital Commons@Becker. It has been accepted for inclusion in Open Access Publications by an authorized administrator of Digital Commons@Becker. For more information, please contact vanam@wustl.edu.

Authors

Christophe Marques, Joshua Schiff, Fahad Momin, Nicole McAllister, Richard L Jennelle, Shelly X Bian, Naomi R Schechter, and Stella K Yoo

Teaching Case

Technical Challenges of Heart Avoidance for Synchronous Breast and Lung Cancers in a Postmenopausal Female: A Planning Case Report From a Safety-Net Hospital



Christophe Marques, MD, PhD,^{a,*} Joshua Schiff, MD,^b
Fahad Momin, BS, CMD,^a Nicole McAllister, BS, CMD,^a
Richard L. Jennelle, MD,^a Shelly X. Bian, MD,^a
Naomi R. Schechter, MD,^a and Stella K. Yoo, MD^a

^aDepartment of Radiation Oncology, University of Southern California, Keck School of Medicine, Los Angeles, California; and ^bDepartment of Radiation Oncology, Barnes Jewish Hospital, Washington University School of Medicine, St. Louis, Missouri

Received 6 April 2019; revised 21 March 2020; accepted 20 April 2020

Introduction

Synchronously presenting carcinomas provide a challenge for the radiation oncologist, particularly in the chest. Such cases are rarely reported in literature, and treatment guidelines are not well defined. Approximately 0.5% of patients with BC experience synchronous lung cancers, and 0.5% of patients with lung cancer present with synchronous primary lung malignancies.^{1,2}

Jin et al³ describe the challenges in treating 3 primary thoracic cavity cancers and the solutions provided by modern therapies such as stereotactic ablative radiotherapy. Even when tumor volume or location limit the applicability of such techniques, IMRT allows for positive outcomes and appropriate dose limits to the adjacent organs at risk. Kim et al⁴ compared the IMRT and volumetric-modulated arc therapy (VMAT) plans to 3DCRT plans for synchronous bilateral BC and

established that IMRT provided superior planning target volume (PTV) dose coverage, whereas VMAT demonstrated superior treatment efficiency.

We present the case of a postmenopausal female with synchronous HER2-positive breast and atypical carcinoid lung cancers. To our knowledge, no prior reported case exists. She was treated with adjuvant systemic therapy involving trastuzumab followed by concurrent 3DCRT and IMRT, targeted to each disease site, respectively. The patient provided informed consent to report the details of her case, including images.

Case

A 63-year-old asymptomatic postmenopausal female, with no significant past medical history, presented with a new left breast lesion detected on screening mammography (Fig 1a,b). Her work-up (Table 1) included the diagnosis of a synchronous lung primary tumor (Fig 1c).

The patient underwent a left breast lumpectomy with sentinel lymph node biopsy and subsequent right upper lobectomy with mediastinal lymph node dissection, with final diagnoses of hormone receptor-negative HER2-positive pT1cN0(sn)M0 (stage IA, American Joint

Sources of support: This work had no specific funding.

Data sharing: Research data are not available at this time.

Disclosures: The authors have no conflicts of interest to disclose.

* Corresponding author: Christophe Marques, MD, PhD; E-mail: Christophe.Marques@med.usc.edu

<https://doi.org/10.1016/j.adro.2020.04.041>

2452-1094/© 2020 The Authors. Published by Elsevier Inc. on behalf of American Society for Radiation Oncology. This is an open access article under the CC BY-NC-ND license (<http://creativecommons.org/licenses/by-nc-nd/4.0/>).

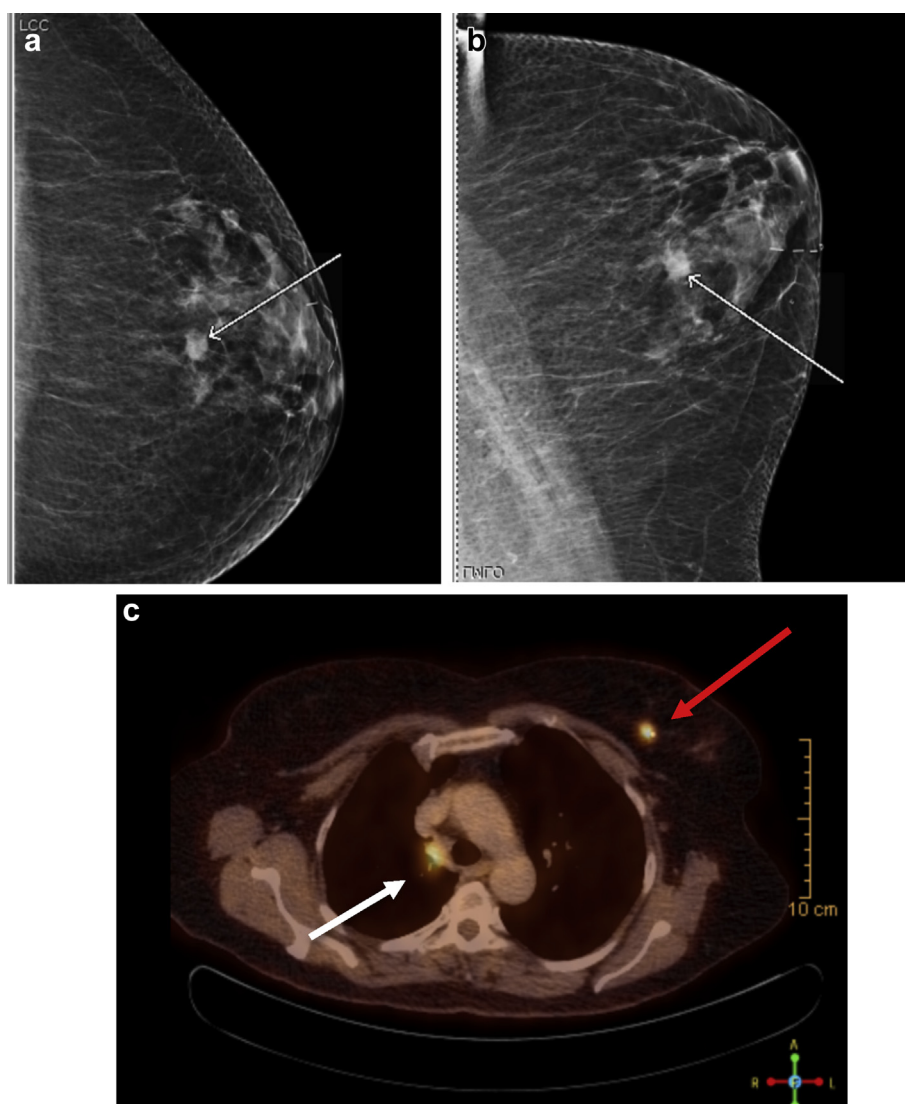


Figure 1 Left breast mammogram showing lesion (white arrow): (a) craniocaudal view, (b) medio-lateral oblique view, (c) positron emission tomography (PET)/computed tomography (CT) scan axial views of right paratracheal lesion standardized uptake value (SUV) 4.6 (white arrow) and left breast lesion SUV 6.4 (red arrow).

Committee on Cancer, eighth edition) invasive ductal carcinoma of the left breast and pT2aN2cM0 (stage IIIA, American Joint Committee on Cancer, eighth edition) atypical carcinoid tumor of the right upper lobe.

She later received adjuvant systemic therapy with docetaxel, carboplatin, and trastuzumab (TCH), consisting of docetaxel (75 mg/m²) plus carboplatin (area under curve, 6 mg/mL/min) every 3 weeks for 5 cycles (sixth cycle omitted owing to poor tolerance) concurrently with trastuzumab, followed by trastuzumab to complete a year of treatment. Heart function was monitored with multigated acquisition cardiac pool imaging to assess left ventricular ejection fraction and wall motion. The left ventricular ejection fraction decreased from 70% to 56% after 6 months of trastuzumab but was stable for the remainder of treatment.

Her Eastern Cooperative Oncology Group performance status was zero when first evaluated by radiation oncology, and she complained of a mild postsurgical cough. She was offered adjuvant left whole breast RT with surgical cavity boost to complete breast conservation therapy, concurrently with adjuvant right lung and mediastinal irradiation.

After radiopaque markers were placed over the lumpectomy scar and the clinical breast borders, she underwent a 2.5-mm thickness free-breathing noncontrast CT simulation scan while immobilized on a breast board in the supine position, with both arms above the head (Fig 2).

The left breast and lumpectomy surgical cavity clinical target volumes were delineated according to the Radiation Therapy Oncology Group (RTOG) BC atlas guidelines,⁵

Table 1 Patient workup including all relevant imaging tests and procedures in chronological order from top to bottom

Test/procedure (chronological order)	Results
Screening mammography (Fig 1a,b)	1.0 × 0.9 × 0.6 cm left breast lesion at 12 o'clock, 3 cm from the nipple
US guided biopsy of the left breast lesion	Moderately differentiated adenocarcinoma, estrogen receptor and progesterone receptor negative, HER2 amplified
PET/CT scan (Fig 1c)	Known left breast lesion (SUV 6.4) and a 2.1 × 1.5 cm FDG-avid right paratracheal lesion (SUV 4.6)
EBUS with FNA of the right paratracheal lesion	Low-grade endocrine tumor, synaptophysin and chromogranin positive
Left breast lumpectomy with SLNB	1.5 cm invasive ductal carcinoma, Nottingham system grade II/III, negative margins, 0 of 4 lymph nodes positive
Mediastinoscopy	No evidence of metastatic disease
Right upper lobectomy with MLND	3.1 cm atypical carcinoid tumor, lymphovascular invasion present, negative margins, positive lymph node station 4R, negative lymph node stations 7, 8, 9, and 11R

Abbreviations: CT = computed tomography; EBUS = endobronchial ultrasound; FDG = fluorodeoxyglucose; FNA = fine needle aspiration; HER2 = human epidermal growth factor receptor 2; MLND = mediastinal lymph node dissection; PET = positron emission tomography; SLNB = sentinel lymph node biopsy; SUV = standardized uptake value; US = ultrasound.

with a 5-mm expansion for the PTV. The right lung clinical target volume was delineated around the right upper lobe bronchial stump and mediastinal lymph node stations 4R, 10R, and 7. The PTV included 5-mm medio-lateral, 5-mm dorso-ventral, and 10-mm craniocaudal expansions. Organs at risk delineated included each lung and the heart.

A composite plan was generated with Eclipse (v13.6 Varian Medical Systems) to deliver 95% of the prescribed dose (50 Gy, 2 Gy fractions) to 95% of the whole left breast PTV, 100% of the prescribed sequential boost dose (10 Gy, 2 Gy fractions) to 95% of the surgical cavity, and concurrently 95% of the prescribed dose (50 Gy, 2 Gy fractions) to 100% of the right lung and mediastinum PTV. The planning objective was to minimize cardiopulmonary doses as much as reasonably possible while treating targets well.

A 3DCRT breast plan was generated using 2 opposed tangential fields with 18 MV photons and field-in-field technique to ensure dose homogeneity (95%-107% dose levels relative to 100% prescription point per International Committee on Radiation Units and Measurements-50 guidelines). A mix of 6 and 18

MV photons was used for the boost. The left lung and the heart were shielded using multileaf collimators. A 5-field IMRT right lung treatment plan using 6 MV photons was also created. Figure 3 shows beam arrangement, color wash dose, and isodose lines. Figure 4 shows the corresponding dose volume histogram, and Table 2 summarizes key values.

Radiation treatment (MV image guided) began 4 weeks after the last cycle of TCH. During treatment, the patient reported expected acute gastrointestinal (odynophagia), pulmonary (dry cough), and dermatologic (erythema) toxicities, all grade 1 per the Common Terminology Criteria for Adverse Events. All toxicities resolved at 1 month, except for cough, which lasted 6 months. Her follow-up CT scans showed RT-related changes at the periphery of the right medial and left upper lungs.

Discussion

An increase in incidence of primary breast tumors in the setting of metachronous primary lung carcinoid

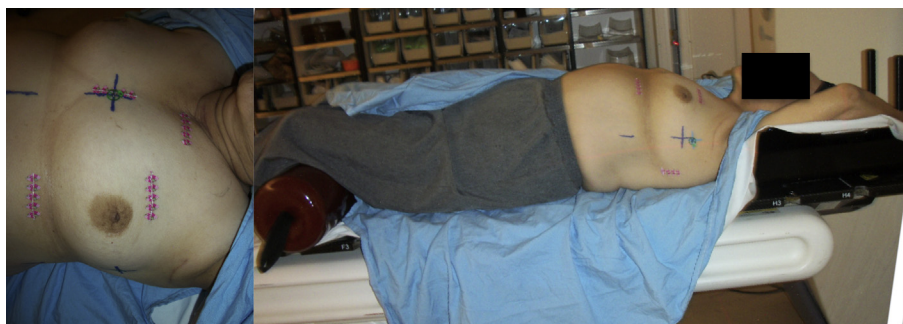

Figure 2 Radiopaque markers indicating lumpectomy scar and clinical breast borders (medial, midline over sternum; lateral, mid-axillary line; cranial, inferior aspect of the clavicular head; and caudal, 2 cm below the inframammary fold) (left). Patient on a breast board in the supine position, both arms above the head (right).

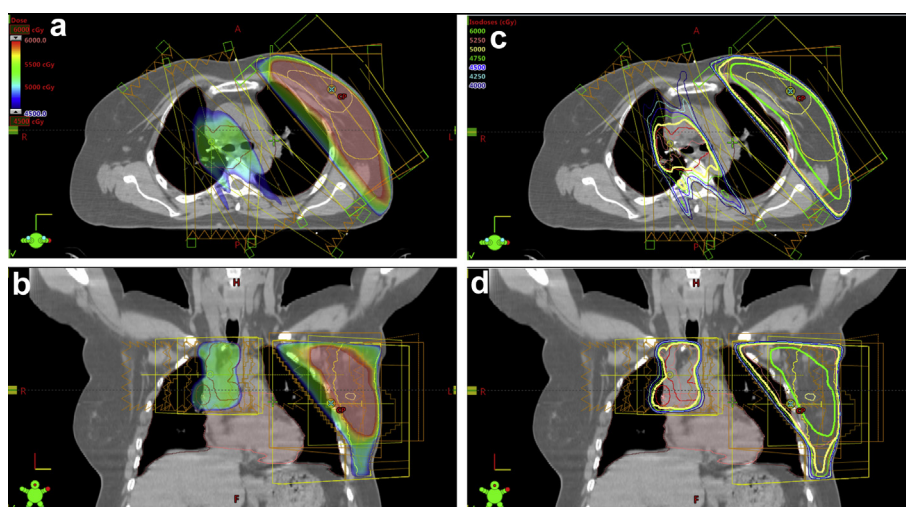


Figure 3 Composite radiation treatment plan illustrating beam arrangements in Eclipse (v13.6 Varian Medical Systems); (a) dose-color-wash axial and (b) coronal section; (c) isodose lines axial and (d) coronal section.

tumors has been observed.⁶ Our patient provided a challenging case for her multidisciplinary care team.

The decision whether to provide adjuvant chemotherapy and/or RT to a stage IIIA atypical carcinoid tumor of the lung is complex owing to lack of prospective randomized data. In a retrospective review of 73 patients with lung neuroendocrine tumors treated with surgical resection, 7 patients received adjuvant chemotherapy and/or RT due to lymph node involvement, local invasion, or involved margins.⁷ However, only 1 of 7 patients was alive at 10 years. Typical chemotherapy regimens include cisplatin/etoposide, carboplatin/etoposide, or temozolomide.⁸ Our patient received adjuvant docetaxel and carboplatin, which were both reported in the treatment of atypical carcinoid tumors and selected because both agents are active in breast and lung cancer (including carcinoid).⁹ In pN2 lung adenocarcinoma, postop RT has shown benefits in terms

of overall survival (OS).^{10–12} Given the more aggressive nature of atypical carcinoid, the presence of positive nodes, and lack of data, we extrapolated lung adenocarcinoma adjuvant RT findings. The patient elected adjuvant RT over omission when we explained that RT would likely improve local recurrence but not OS.¹³

For the radiation oncologist, the most challenging prospect in the setting of synchronous breast and lung tumors is limiting heart dose. Current clinical trial protocols for stage III non-small cell lung cancer (NSCLC), including the ongoing RTOG 1306 (using 3DCRT or IMRT), specify cardiac dosimetric limits mostly unchanged since RTOG 0617: V60 (volume receiving ≥ 60 Gy) $< 1/3$, V45 $< 2/3$, and V40 $< 3/3$.

Table 2 shows these limits were all satisfied by the composite RT plan. Recent trials for BC, such as National Surgical Adjuvant Breast and Bowel Project (NSABP) B-51/RTOG 1304 and RTOG 1005, define more stringent

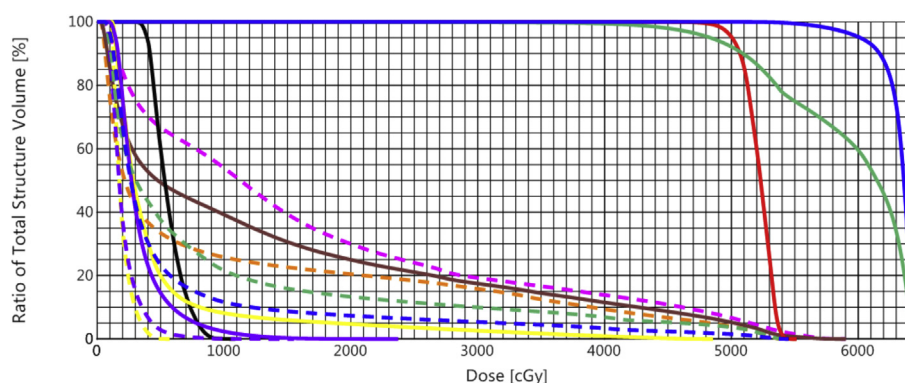


Figure 4 Composite plan cumulative dose volume histogram (DVH) of planning target volumes (PTVs) (solid red, right lung and mediastinum; solid green, left whole breast; solid blue, left breast surgical cavity; dotted pink, left lung; dotted orange, right lung; solid brown, both lungs; dotted blue, whole heart; solid black, left anterior descending (LAD); dotted green, pericardium; solid purple, left ventricle; dotted purple, right ventricle; solid yellow, left atrium; dotted yellow, right atrium).

Table 2 OAR composite plan values with limitations per locally advanced lung cancer protocols, single institutions, and breast cancer protocols. Cardiac structure with radiation dose levels, HR rate of cardiac events, and estimated HR of cardiac events

Cancer protocols: Cardiac structure with radiation dose levels, HR rate of cardiac events, and estimated HR of cardiac events							
OAR	Value	RTOG 0617, RTOG 1306	WashU UNC RCI	RTOG 1005	NSABP B-51 (left breast)		
Whole heart							
Mean	6.0 Gy		<20 Gy*	≤4 Gy (5 Gy [†])	≤ 4 Gy (5 Gy [†])		
Max	54.5 Gy						
V5	23%						
V10	12%			≤30% (35% [†])*			
V20	7%			≤5%			
V25	6%			≤5% [†]	≤10%*		
V30	5%				≤10%* [†]		
V40	3%	<100%*					
V45	2%	<67%*					
V50	2%		<25%*				
V60	0%	<33%*					
LAD artery							
Mean	5.5 Gy						
Max	10.9 Gy						
Both lungs (minus PTV)							
Mean	13.3 Gy	≤20-22 Gy*					
Max	59.0 Gy						
V20	25.0%	≤37-40%*					
Ipsilateral lung (minus PTV)							
V20	20%			≤15% (20% [†])*	≤15% (20% [†])*		
Contralateral lung							
V5	67%			≤10% (15% [†])	≤15%		
Cardiac structure	Value	HR rate	Estimated HR	Cardiac structure	Value	HR rate	Estimated HR
Left ventricle				Left atrium			
Mean	3.4 Gy	1.05/Gy	3.6	Mean	4.9 Gy	1.04/Gy	5.1
V5	15%	1.03/%	15.5	V5	20%	1.05/%	21.0
V30	0%	1.03/%	0.0	V30	3%	1.03/%	3.1
				V60	0%	1.03/%	0.0
Whole heart				Right atrium			
Mean	6.0 Gy	1.02/Gy	6.1	Mean	2.0 Gy	1.03/Gy	2.1
V5	23%	1.03/%	23.7	V5	0%	1.02/%	0.0
V30	5%	1.02/%	5.1	V60	0%	1.02/%	0.0
V60	0%	1.04/%	0.0				

Abbreviations: HR = hazard ratio; LAD = left anterior descending; NSABP = National Surgical Adjuvant Breast and Bowel Project; OAR = organs at risk; PTV = planning target volume; RCI = Rutgers Cancer Institute of New Jersey; RTOG = Radiation Therapy Oncology Group; UNC = University of North Carolina; Vx = percentage of the structure volume receiving ≥ x Gy; WashU = Washington University St Louis.

* Dose limit met.

[†] Acceptable value per protocol.

heart dose limits due to a better prognosis of patients with BC versus patients with lung cancer. In general, the goals are maximal mean heart dose (MHD) of 4 to 5 Gy, V25 < 10% and V30 < 10% for left-sided BC.¹⁴ In our plan, the MHD limit was exceeded due to the contribution from the lung IMRT component, which represents approximately 75% of the 6.0 Gy MHD.

Remaining below dose limits is crucial, as the risk of ischemic heart disease in women after breast RT is well-studied. Darby et al¹⁵ established that this risk in women treated before the 3DCRT era starts within 5 years

after exposure, lasts for at least 20 years, and is proportional to the MHD, with a linear increase in major coronary events of 7.4% per Gy. Van den Bogaard et al¹⁶ showed that the left ventricle V5 after breast conservation surgery is a better predictor for acute coronary events than MHD.

In RTOG 0617 for stage III NSCLC, heart dose was associated with worse OS at 2-year median follow-up, suggesting RT-induced cardiac disease develops sooner than historically understood.^{17,18} Speirs et al¹⁹ reported on patients with locally advanced NSCLC who received

definitive RT alone or with chemotherapy. On multivariate analysis (MVA), V50 was the strongest factor independently associated with worse OS and keeping V50 < 25% (hazard ratio [HR], 1.23; $P < .0001$) yielded nearly a 20% absolute improvement in 2-year OS.

Wang et al²⁰ reported on patients with stage III NSCLC with definitive dose-escalated 3DCRT after induction chemotherapy with or without concurrent chemotherapy and suggested dose-dependent RT-related cardiotoxicity. On MVA, heart doses were significantly associated with incidence of symptomatic cardiac events (pericardial effusion, acute coronary syndrome, pericarditis, significant arrhythmia, and heart failure) adjusted for the competing risk of death (estimated using baseline cardiac risk). Events were higher with MHD ≥ 20 Gy versus < 10 Gy (HR, 5.47; $P < .001$), but OS was not. An MHD < 20 Gy, or lower if possible, was deemed a reasonable limit, which was also advocated by Yegya-Raman et al²¹ based on a retrospective review of inoperable patients with NSCLC treated with definitive concurrent chemoRT. On MVA, only baseline cardiac status and MHD were associated with increased risk of symptomatic cardiac events (defined by Wang et al²⁰). When stratified by MHD ≥ 20 Gy versus 10 to 20 Gy versus < 10 Gy, cumulative symptomatic cardiac events were significantly higher with MHD ≥ 20 Gy versus < 10 Gy (HR, 4.95; $P = .0024$). Although no direct association between MHD and OS was found, symptomatic cardiac events predicted worse OS. Atkins et al²² also reported on stage II (unresectable or inoperable) and stage III NSCLC treated with multimodality therapy involving RT. In patients without preexisting coronary heart disease, there was a significantly higher risk of all-cause mortality with MHD ≥ 10 Gy versus < 10 Gy (HR, 1.34; $P = .014$).

Wang et al²³ also showed that cardiac events (pericardial, ischemia, and arrhythmia) were associated with distinct heart subvolume dose levels and were detected by 2-year median follow-up, supporting the possibility of distinct etiologies for RT-induced cardiotoxicity. The subvolumes (delineated per Feng et al²⁴) included whole heart, left ventricle, right atrium, and left atrium. Using HR values from Wang et al,²³ our patient was at highest risk of cardiac ischemia (HR, 15.5 from left ventricle V5 and HR, 23.7 from whole heart V5) and arrhythmia (HR, 23.7 from whole heart V5), as summarized in Table 2.

The LAD coronary artery was also contoured per Feng et al²⁴ as a critical structure for RT-induced cardiac events. Lind et al²⁵ studied single-photon emission tomography myocardial perfusion imaging in 69 patients who underwent RT for left-sided BC and found perfusion defects in the LAD distribution, pointing to a likely mechanism of cardiac damage. Copper et al²⁶ suggested the maximum LAD dose (LAD_{max}) may be more clinically relevant over the mean LAD dose, as occlusion

of only 1 section of the LAD can result in symptomatic heart disease and proposed LAD_{max} < 10 Gy. Our patient's LAD_{max} was very close at 10.9 Gy.

Limiting heart dose was additionally important, as the patient's BC necessitated adjuvant trastuzumab, which improves disease-free survival and OS in HER2-positive BC; however, it can induce a statistically significant increase in congestive heart failure and cardiac dysfunction, particularly when used with an anthracycline-based chemotherapy regimen.²⁷

Modalities that possibly could have reduced toxicity to the heart and lungs are not available at our safety-net hospital and include motion encompassment (eg, 4-dimensional CT scanning) and respiratory gating (triggered activation or deactivation of RT delivery).²⁸ Lung radiation was delivered with IMRT, although VMAT (not available at our institution) is shown to help reduce heart dose.²⁹ Proton therapy also can theoretically reduce dose to critical structures; the ongoing RTOG 1308 trial comparing motion-managed proton versus photon RT in inoperable stage II-IIIB NSCLC is investigating cardiac toxicity as a primary objective.

Conclusions

Synchronous breast and lung cancers are rare and pose a technical challenge for RT planning should concurrent treatment be warranted. Satisfying more stringent cardiac dose limits than specified by ongoing lung cancer trials is critical, as patients with lung cancer can develop RT-related cardiac toxicities within 2 years posttreatment. Tracking dose levels within cardiac substructures may be more relevant than whole heart doses. Techniques employing 3DCRT and IMRT create a composite plan both safe and practical with minimal acute or subacute toxicities, as our patient's case shows. Further research is warranted to investigate best strategies in this unique patient population.

Acknowledgments

The authors would like to thank Dr Jason C. Ye for his help revising this manuscript.

References

1. Ferguson MK. Synchronous primary lung cancers. *Chest*. 1993;103:398S-400S.
2. Burstein HJ, Swanson SJ, Christian RL, McMenamin ME. Unusual aspects of breast cancer: Case 2. Synchronous bilateral lung and breast cancers. *J Clin Oncol*. 2001;19:2571-2573.
3. Jin CJ, Mei X, Falkson CB. A case of synchronous breast and bilateral lung cancers: literature review and considerations for radiation treatment planning. *BJR Case Rep*. 2017;3: 20150464.
4. Kim SJ, Lee MJ, Youn SM. Radiation therapy of synchronous bilateral breast carcinoma (SBBC) using multiple techniques. *Med Dosim*. 2018;43:55-68.

5. Radiation Therapy Oncology Group (RTOG) Foundation INC. Breast cancer contouring atlas. Available at: <https://www.rtog.org/corelab/contouringatlases/breastcanceratlas.aspx>. Accessed March 15, 2020.
6. Tsai HJ, Wu CC, Tsai CR, Lin SF, Chen LT, Chang JS. Second cancers in patients with neuroendocrine tumors. *PLoS One*. 2013;8:e86414.
7. Perkins P, Kemp BL, Putnam JB, Cox JD. Pretreatment characteristics of carcinoid tumors of the lung which predict aggressive behavior. *Am J Clin Oncol*. 1997;20:285-288.
8. National Comprehensive Cancer Network. Neuroendocrine and adrenal tumors (Version 3.2018). Available at: https://www.nccn.org/professionals/physician_gls/pdf/neuroendocrine.pdf. Accessed March 15, 2020.
9. Chong CR, Wirth LJ, Nishino M, et al. Chemotherapy for locally advanced and metastatic pulmonary carcinoid tumors. *Lung Cancer*. 2014;86:241-246.
10. Douillard JY, Rosell R, De Lena M, et al. Impact of postoperative radiation therapy on survival in patients with complete resection and stage I, II, or IIIA non-small-cell lung cancer treated with adjuvant chemotherapy: The adjuvant Navelbine International Trialist Association (ANITA) Randomized Trial. *Int J Radiat Oncol Biol Phys*. 2008;72:695-701.
11. Lally BE, Zelterman D, Colasanto JM, Haffty BG, Detterbeck FC, Wilson LD. Postoperative radiotherapy for stage II or III non-small-cell lung cancer using the surveillance, epidemiology, and end results database. *J Clin Oncol*. 2006;24:2998-3006.
12. PORT Meta-analysis Trialists Group. Postoperative radiotherapy in non-small-cell lung cancer: Systematic review and meta-analysis of individual patient data from nine randomised controlled trials. *Lancet*. 1998;352:257-263.
13. Thomas CF, Tazelaar HD, Jett JR. Typical and atypical pulmonary carcinoids: Outcome in patients presenting with regional lymph node involvement. *Chest*. 2001;119:1143-1150.
14. RTOG Foundation. RTOG 1005 protocol: A phase III trial of accelerated whole breast irradiation with hypofractionation plus concurrent boost versus standard whole breast irradiation plus sequential boost for early-stage irradiation. Available at: <http://www.rtog.org/ClinicalTrials/ProtocolTable/StudyDetails.aspx?action=openFile&FileID=9366>. Accessed March 15, 2020.
15. Darby SC, Ewertz M, McGale P, et al. Risk of ischemic heart disease in women after radiotherapy for breast cancer. *N Engl J Med*. 2013;368:987-998.
16. van den Bogaard VA, Ta BD, van der Schaaf A, et al. Validation and modification of a prediction model for acute cardiac events in patients with breast cancer treated with radiotherapy based on three-dimensional dose distributions to cardiac substructures. *J Clin Oncol*. 2017;35:1171-1178.
17. Bradley JD, Paulus R, Komaki R, et al. Standard-dose versus high-dose conformal radiotherapy with concurrent and consolidation carboplatin plus paclitaxel with or without cetuximab for patients with stage IIIA or IIIB non-small-cell lung cancer (RTOG 0617): A randomised, two-by-two factorial phase 3 study. *Lancet Oncol*. 2015;16:187-199.
18. Chun SG, Hu C, Choy H, et al. Impact of intensity-modulated radiation therapy technique for locally advanced non-small-cell lung cancer: A secondary analysis of the NRG Oncology RTOG 0617 Randomized Clinical Trial. *J Clin Oncol*. 2017;35:56-62.
19. Speirs CK, DeWees TA, Rehman S, et al. Heart dose is an independent dosimetric predictor of overall survival in locally advanced non-small cell lung cancer. *J Thorac Oncol*. 2017;12:293-301.
20. Wang K, Eblan MJ, Deal AM, et al. Cardiac toxicity after radiotherapy for stage III non-small-cell lung cancer: Pooled analysis of dose-escalation trials delivering 70 to 90 Gy. *J Clin Oncol*. 2017;35:1387-1394.
21. Yegya-Raman N, Wang K, Kim S, et al. Dosimetric predictors of symptomatic cardiac events after conventional-dose chemoradiation therapy for inoperable NSCLC. *J Thorac Oncol*. 2018;13:1508-1518.
22. Atkins KM, Rawal B, Chaunzwa TL, et al. Cardiac radiation dose, cardiac disease, and mortality in patients with lung cancer. *J Am Coll Cardiol*. 2019;73:2976-2987.
23. Wang K, Pearlstein KA, Patchett ND, et al. Heart dosimetric analysis of three types of cardiac toxicity in patients treated on dose-escalation trials for Stage III non-small-cell lung cancer. *Radiother Oncol*. 2017;125:293-300.
24. Feng M, Moran JM, Koelling T, et al. Development and validation of a heart atlas to study cardiac exposure to radiation following treatment for breast cancer. *Int J Radiat Oncol Biol Phys*. 2011;79:10-18.
25. Lind PA, Pagnanelli R, Marks LB, et al. Myocardial perfusion changes in patients irradiated for left-sided breast cancer and correlation with coronary artery distribution. *Int J Radiat Oncol Biol Phys*. 2003;55:914-920.
26. Cooper BT, Li X, Shin SM, et al. Preplanning prediction of the left anterior descending artery maximum dose based on patient, dosimetric, and treatment planning parameters. *Adv Radiat Oncol*. 2016;1:373-381.
27. Slamon D, Eiermann W, Robert N, et al. Adjuvant trastuzumab in HER2-positive breast cancer. *N Engl J Med*. 2011;365:1273-1283.
28. Molitoris JK, Diwanji T, Snider JW, et al. Advances in the use of motion management and image guidance in radiation therapy treatment for lung cancer. *J Thorac Dis*. 2018;10:S2437-S2450.
29. Choi J. Comparison of IMRT and VMAT plan for advanced stage non-small cell lung cancer treatment. *Arch Can Res*. 2018;6.