

1-1-2021

Incidentally found rib hemangioma: Case report and discussion of management

Deniz B. Morkan
Washington University School of Medicine in St. Louis

Jason M. Gauthier
Washington University School of Medicine in St. Louis

Daniel Kreisel
Washington University School of Medicine in St. Louis

Varun Puri
Washington University School of Medicine in St. Louis

Ruben G. Nava
Washington University School of Medicine in St. Louis

Follow this and additional works at: https://digitalcommons.wustl.edu/oa_4

 Part of the [Medicine and Health Sciences Commons](#)

Please let us know how this document benefits you.

Recommended Citation

Morkan, Deniz B.; Gauthier, Jason M.; Kreisel, Daniel; Puri, Varun; and Nava, Ruben G., "Incidentally found rib hemangioma: Case report and discussion of management." *AME Case Reports*. 5, e13 (2021).
https://digitalcommons.wustl.edu/oa_4/579

This Open Access Publication is brought to you for free and open access by the Open Access Publications at Digital Commons@Becker. It has been accepted for inclusion in 2020-Current year OA Pubs by an authorized administrator of Digital Commons@Becker. For more information, please contact vanam@wustl.edu.



Incidentally found rib hemangioma: case report and discussion of management

Deniz B. Morkan¹, Jason M. Gauthier¹, Daniel Kreisel^{1,2}, Varun Puri¹, Ruben G. Nava¹

¹Division of Cardiothoracic Surgery, Department of Surgery, Washington University School of Medicine in St. Louis, St. Louis, MO, USA;

²Department of Pathology and Immunology, Washington University School of Medicine in St. Louis, St. Louis, MO, USA

Correspondence to: Ruben G. Nava, MD. Division of Cardiothoracic Surgery, Department of Surgery, Washington University School of Medicine in St. Louis, Campus Box 8109, 660 South Euclid Avenue, St. Louis, MO 63110, USA. Email: navar@wustl.edu.

Abstract: Rib hemangioma is a rare chest wall tumor for which few reports in the literature exist to help guide treatment. The clinical presentation, radiographic findings, and treatment strategies vary in the literature, with the majority of patients undergoing surgical resection to definitively rule out malignancy. Here, we report a 23-year-old woman with an incidentally discovered rib hemangioma, who had a history of migraines, during the workup of a severe headache refractory to medical treatment. Imaging revealed a solitary, expansile tumor arising from the posterior left third rib. Spinal magnetic resonance imaging (MRI) showed a fat-containing lesion with multiple vascular flow voids, non-enhancement, and high signal intensity on the T2-weighted series. It appeared to have a honeycomb core on chest computed tomography (CT). Imaging characteristics of the lesion were consistent with an intraosseous hemangioma. The tumor was managed with upfront surgical resection without a preoperative biopsy. The case was uneventful and no complications were encountered. The patient recovered well, denied any symptoms four weeks after surgery, and a follow-up chest X-ray was unremarkable. Following resection, the pathological diagnosis was concordant with the radiographic diagnosis of a rib hemangioma. Here, we review existing literature on the rare case of a rib hemangioma with a focus on the radiographic characteristics and management. Given that radiographic features of this lesion were consistent with prior reports and surgery did not change the diagnosis, we suggest that non-operative management be considered for similar lesions, as surgical resection does not appear to reveal occult malignancy in the majority of cases.

Keywords: Rib hemangioma; vascular tumor; chest wall; imaging; management

Received: 29 September 2020; Accepted: 06 February 2021; Published: 25 April 2021.

doi: [10.21037/acr-20-144](https://doi.org/10.21037/acr-20-144)

View this article at: <http://dx.doi.org/10.21037/acr-20-144>

Introduction

Bone hemangiomas account for approximately 1% of primary bone tumors, and 60% to 80% of bone hemangiomas arise from the skull or the vertebral column (1,2). The rib cage is an extremely uncommon location for hemangiomas, with few cases reported in the literature (3). While some lesions have a characteristic appearance on imaging that is highly suggestive of the diagnosis, a final diagnosis can only be obtained from the histological analysis. A preoperative biopsy, however, is not recommended. Given that the malignancy rate is

50–89% among primary rib tumors and the lack of evidence to help guide treatment, the majority of previously reported cases have been managed with surgical resection (4,5). In this report, we describe a case of rib hemangioma incidentally discovered during the workup of a cerebrospinal fluid (CSF) leak and discuss the rationale of non-operative management for selected cases that introduces a novel perspective for the management of rib hemangioma to the literature. We present the following case in accordance with the CARE reporting checklist (available at <http://dx.doi.org/10.21037/acr-20-144>).

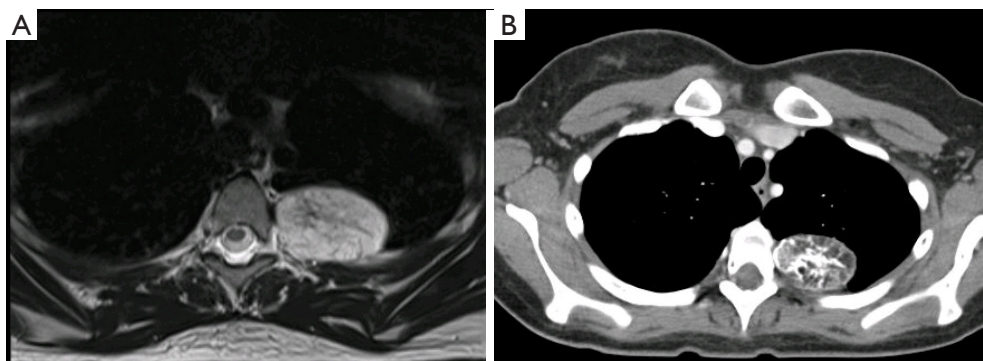


Figure 1 Radiographic appearance of an intraosseous hemangioma of the rib. (A) T2-weighted MRI series reveals an expansile, fat containing lesion in the posterior aspect of the third rib. (B) CT imaging reveals a benign appearing lesion with a honeycomb core.

Case presentation

A 23-year-old female with a history of chronic migraines was incidentally found to have a bone tumor on the left third rib. The patient had presented to the emergency department with the complaint of a severe migraine, refractory to analgesics. Physical examination at the time was unremarkable. Acute intracranial pathology was excluded on head computed tomography (CT), and brain magnetic resonance imaging (MRI) demonstrated findings of intracranial hypotension concerning for a CSF leak. A spinal MRI was then obtained, revealing a meningeal diverticulum on the right aspect of the T10-T11 vertebrae, as well as a left third rib tumor. The lesion was 4.8 cm × 3.2 cm, expansile, solitary, and arising from the posterior aspect of the third rib. The tumor appeared to be fat-containing, had multiple vascular flow voids, did not enhance with contrast, and exhibited high signal intensity on the T2-weighted MRI series (*Figure 1A*). The lesion was further characterized with a CT scan (*Figure 1B*) and felt by our radiologist to be an intraosseous hemangioma. The patient was treated with a blood patch to relieve the CSF leak and referred to our clinic following relief of her migraine symptoms.

Given the uncertain etiology of the tumor, the patient was offered *en bloc* resection of the mass. We did not pursue a preoperative biopsy due to the increased risk of bleeding, which was a complication in a previous report (5). Arterial embolization of the feeding blood vessels has been previously described to decrease the risk of bleeding during the operation; this strategy was attempted in our case yet was unsuccessful due to extensive collateral vessels arising from the aorta (5,6). The patient was

brought to the operating room, intubated with a dual-lumen tube, and placed in right lateral decubitus position. A left posterolateral thoracotomy was made in the fifth intercostal space with preservation of the serratus anterior muscle. Single lung ventilation was achieved, and the lesion was easily identified. The posterior aspect of the left third rib was resected. Chest wall reconstruction was not seen necessary due to the small defect after resection. No complications were encountered in the postoperative period, and the patient was discharged to home on the fifth postoperative day.

Gross examination of the specimen revealed a firm, well-circumscribed mass measuring 5.0 cm × 3.8 cm × 2.5 cm, arising from the medullary cavity of the third rib (*Figure 2A*). Histological examination revealed a tan-yellow intraosseous mass expanding the periosteum, directly underneath the pleural surface with neither gross necrosis nor soft tissue invasion (*Figure 2B*). The final pathological diagnosis was an intraosseous hemangioma.

Four weeks after the operation, the patient denied any symptoms, and her physical examination was unremarkable. A follow-up chest X-ray was obtained and did not reveal any pathologies such as a pneumothorax or pleural effusion.

All procedures performed in studies involving human participants were in accordance with the ethical standards of the institutional and/or national research committee(s) and with the Helsinki Declaration (as revised in 2013). Written informed consent was obtained from the patient.

Discussion

Rib hemangiomas have largely been reported as incidental findings, although there are reports of symptomatic

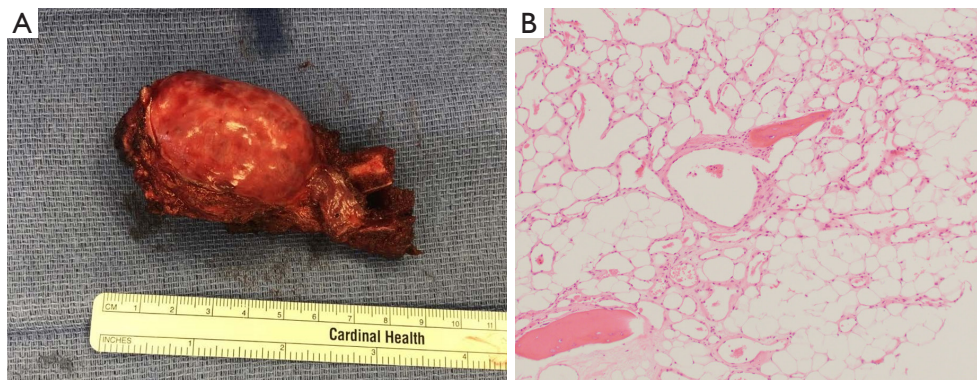


Figure 2 Gross and pathological appearance of the surgical specimen. (A) Gross analysis of the specimen revealing a tan-yellow, well-circumscribed mass arising from the medullary cavity and expanding the periosteum. (B) Microscopic examination of the surgical specimen demonstrating bone marrow contents and numerous thin-walled blood vessels without atypia (H&E, 100 \times).

presentations, such as chest pain and swelling, shortness of breath, back pain, pleural effusion, intercostal paresthesia, and thoracic outlet syndrome (4,5,7-10). In our case, the hemangioma was incidentally found during the workup of a CSF leak. CT imaging will reveal a well-circumscribed, expansile intraosseous mass containing osteolytic areas and coarsened trabeculae, which often referred as honeycomb appearance (11-13). Although it is characteristic to skull hemangiomas, a rib hemangioma may also display sunburst calcifications (12,14). Cortical disruption is sometimes seen, and while this may be concerning for malignancy, this finding has been seen in some lesions that ultimately were found to be benign intraosseous hemangiomas (8,11,15,16) (*Table 1*). MRI is an important adjunct, as can be seen in our case (*Figure 1A*). T1-weighted images highlight the fatty content and reticular architecture of the medullary component, and T2-weighted images will reveal a hyperintense lesion due to abundant large vascular channels (5,14). Some of the above imaging findings can also be seen in the setting of malignant tumors, such as chondrosarcoma or Ewing sarcoma (12). As such, all but one prior case report have been treated with resection in order to definitively rule out cancer.

In our case, the radiologists were confident that the lesion was a benign intraosseous hemangioma, and non-operative management was considered. A tissue diagnosis would have been quite helpful and likely changed our management strategy, but several concerns prevented us from pursuing this. Some authors have cited concern for bleeding, wound infection, and disruption of the surgical bed prior to resection as the reason for forgoing a biopsy (12). Furthermore, should the tumor be malignant, then there is the

added risk of seeding the needle tract with cancer (12). Given the overall malignancy rate amongst rib cage tumors and the paucity of literature on non-operative management of similar lesions, we ultimately elected to perform a resection (*Table 1*).

One case has been reported of the non-operative management of a rib hemangioma. Here, an open biopsy was obtained, which confirmed the radiological diagnosis, and the patient was not treated with resection. There was no malignant degeneration or size increase in one year (6). No cases have been reported that demonstrate non-operative management based upon a radiographic diagnosis alone. At first glance, it seems hazardous to non-operatively manage a mass that appears to be a rib hemangioma, as this often shares radiographic features with some malignant lesions (14). Conversely, if a lesion appears most consistent with an intraosseous hemangioma avoiding the resection also seems reasonable, as surgery does not appear to frequently change the diagnosis; there is a paucity of literature available to guide such decision making, and thus our recommendation on how to best treat similar lesions remains limited. A needle or open biopsy may prove helpful in the decision to resect or manage conservatively, and should be considered if concerning imaging findings are present, such as cortical disruption (6).

In conclusion, given our experience with this case and that of others, whereby the radiographic diagnosis was not changed by the pathologic analysis, non-operative management for similarly appearing, asymptomatic rib tumors can be considered.

Acknowledgments

Funding: None.

Table 1 Epidemiology, clinical manifestations, diagnostic features, and management of rib hemangioma

Variables	Reported cases/lesions	Percentage (%)
Age >40	24	83
Male gender	10	34
Tumor laterality*		
Right rib	14	48
Left rib	14	48
Bilateral ribs	1	4
Tumor location*		
1 st –2 nd ribs	2	7
3 rd –7 th ribs	21	70
8 th –12 th ribs	7	23
Symptomatic presentation	11	38
Radiologic features* [†]		
Cortical disruption	15	50
Expansion	23	77
Osteolysis	9	30
Calcification	6	20
Biopsy	7	24
Surgical management	28	97

*, the data above is extrapolated from 29 case reports in the literature (see Supplementary Appendix I for citations). All tumors are single and unilateral, aside from one case of bilateral tumors. As such, N=29 for all variables above except for those which are marked with an asterisk, representing N=30. †, see Supplementary Appendix I for methods and detailed explanation of how radiologic features were abstracted.

Footnote

Reporting Checklist: The authors have completed the CARE reporting checklist. Available at <http://dx.doi.org/10.21037/acr-20-144>

Conflicts of Interest: All authors have completed the ICMJE uniform disclosure form (available at <http://dx.doi.org/10.21037/acr-20-144>). Dr. Kreisel reports grants and personal fees from Compass Therapeutics, outside the submitted work; in addition, Dr. Kreisel has a patent Pending US patent entitled “Compositions and methods for detecting CCR2 receptors” (application number 15/611,577). pending. Dr. Puri reports other from Intuitive Surgical, outside the submitted work. The other authors have no conflicts of interest to declare.

Ethical Statement: The authors are accountable for all

aspects of the work in ensuring that questions related to the accuracy or integrity of any part of the work are appropriately investigated and resolved. All procedures performed in studies involving human participants were in accordance with the ethical standards of the institutional and/or national research committee(s) and with the Helsinki Declaration (as revised in 2013). Written informed consent was obtained from the patient.

Open Access Statement: This is an Open Access article distributed in accordance with the Creative Commons Attribution-NonCommercial-NoDerivs 4.0 International License (CC BY-NC-ND 4.0), which permits the non-commercial replication and distribution of the article with the strict proviso that no changes or edits are made and the original work is properly cited (including links to both the formal publication through the relevant DOI and the license).

See: <https://creativecommons.org/licenses/by-nc-nd/4.0/>.

References

1. Shimizu K, Yamashita Y, Hihara J, et al. Cavernous hemangioma of the rib. *Ann Thorac Surg* 2002;74:932-4.
2. Dorfman HD, Steiner GC, Jaffe HL. Vascular tumors of bone. *Hum Pathol* 1971;2:349-76.
3. Woo CG, Lee HC, Son SM, et al. Clinicopathological characteristics of costal hemangiomas: a case report and literature review. *J Int Med Res* 2019;47:982-5.
4. Huang H, Ning C, Pan Y. Giant cavernous hemangioma of the eleventh rib. *J Cardiothorac Surg* 2019;14:95.
5. Deshmukh H, Rathod KK, Hira P, et al. Hemangioma of Rib: A Different Perspective. *Pol J Radiol* 2015;80:172-5.
6. Itabashi T, Emori M, Terashima Y, et al. Hemangioma of the rib showing a relatively high 18F-FDG uptake: a case report with a literature review. *Acta Radiol Open* 2017;6:2058460117728416.
7. Weinandt M, Legras A, Mordant P, et al. Chest wall resection for multifocal osseous haemangioma. *Interact Cardiovasc Thorac Surg* 2016;22:233-4.
8. Hashimoto N, Takenaka S, Akimoto Y, et al. Capillary hemangioma in a rib presenting as large pleural effusion. *Ann Thorac Surg* 2011;91:e59-61.
9. Nakamura H, Kawasaki N, Taguchi M, et al. Cavernous hemangioma of the rib diagnosed preoperatively by percutaneous needle biopsy. *Gen Thorac Cardiovasc Surg* 2007;55:134-7.
10. Yeow KM, Hsieh HC. Thoracic outlet syndrome caused by first rib hemangioma. *J Vasc Surg* 2001;33:1118-21.
11. Tanaka T, Masaoka Y, Sugimoto S, et al. Cavernous hemangioma of the rib mimicking a chondrosarcoma: Diagnostic value of delayed phase MRI. *Diagn Interv Imaging* 2019;100:455-7.
12. Abrão FC, Tamagno M, Canzian M, et al. Hemangioma of the rib. *Ann Thorac Surg* 2011;91:595-6.
13. Leong S, Kok HK, Delaney H, et al. The Radiologic Diagnosis and Treatment of Typical and Atypical Bone Hemangiomas: Current Status. *Can Assoc Radiol J* 2016;67:2-11.
14. Ogose A, Hotta T, Morita T, et al. Solitary osseous hemangioma outside the spinal and craniofacial bones. *Arch Orthop Trauma Surg* 2000;120:262-6.
15. Okumura T, Asamura H, Kondo H, et al. Hemangioma of the rib: a case report. *Jpn J Clin Oncol* 2000;30:354-7.
16. Tew K, Constantine S, Lew WYC. Intraosseous hemangioma of the rib mimicking an aggressive chest wall tumor. *Diagn Interv Radiol* 2011;17:118-21.

doi: 10.21037/acr-20-144

Cite this article as: Morkan DB, Gauthier JM, Kreisel D, Puri V, Nava RG. Incidentally found rib hemangioma: case report and discussion of management. *AME Case Rep* 2021;5:13.

Appendix I

I. List of Investigators

Deniz B. Morkan¹, Jason M. Gauthier¹, Daniel Kreisel^{1,2}, Varun Puri¹, Ruben G. Nava¹

¹Division of Cardiothoracic Surgery, Department of Surgery, Washington University School of Medicine in St. Louis, St. Louis, MO, USA; ²Department of Pathology and Immunology, Washington University School of Medicine in St. Louis, St. Louis, MO, USA

II. Methods

A literature review was conducted in PubMed in order to identify studies describing rib hemangioma characteristics and management. The search term [rib hemangioma] and Medical Subject Headings (Mesh) terms “Ribs”[Mesh] AND “Hemangioma”[Mesh] were used for review. The following search criteria were applied: manuscript written in English, patient age > 18, and full text accessible through our academic institution. A total of 29 cases with 30 lesions were identified for *Table 1*. A full list of citations for these cases can be found below in “III References” used in *Table 1*.

Data for eight variables (*patient age, patient gender, tumor laterality, tumor location, presence of symptoms, radiologic features, biopsy, and treatment*) were abstracted. Given that variables *patient age, patient gender, presence of symptoms, biopsy, and treatment* are case-related, percentage calculations for these variables were performed by the total number of cases (29). On the other hand, since *tumor laterality, tumor location, and radiologic features* are lesion-related, percentages for these variables were calculated from the total number of lesions (30). *Radiologic features* were further classified as “cortical disruption”, “osteolysis”, “expansile”, and “calcification”. Reports that exactly stated expansion, lysis, and calcification were considered for regarding features. Those which stated cortical disruption, bone destruction, cortical thinning, and cortical erosion were considered “cortical disruption”. The table was created and percentages were calculated using MS Excel (Microsoft, Redmond, WA).

III. References

1. Abrão, Fernando Conrado; Tamagno, Mauro; Canzian, Mauro; Fernandez, Ângelo; Bibas, Jacques; Fernandes, Paulo Manuel Pêgo; Jatene, Fabio Biscegli (2011): Hemangioma of the rib. In *The Annals of thoracic surgery* 91 (2), pp. 595–596. DOI: 10.1016/j.athoracsur.2010.07.091.
2. Bubnjar, Josip; Papeš, Dino (2012): Rib hemangioma presenting as an asymptomatic mass. In *The American surgeon* 78 (4), E238-9.
3. Cakir, E.; Tastepe, I.; Agackiran, Y. (2008): Cavernous hemangioma of the rib: a rare tumour. In *Acta chirurgica Belgica* 108 (5), pp. 619–620. DOI: 10.1080/00015458.2008.11680303.
4. Ceberut, Kadri; Aksoy, Yasar Metin; Savas, Fikriye; Müslehiddinoglu, Ahmet (2008): Cavernous hemangioma of the rib: a case report. In *Asian cardiovascular & thoracic annals* 16 (3), e25-7. DOI: 10.1177/021849230801600324.
5. Clements, R. H.; Turnage, R. B.; Tyndal, E. C. (1998): Hemangioma of the rib: a rare diagnosis. In *The American surgeon* 64 (11), pp. 1027–1029.
6. Deshmukh, Hemant; Rathod, Kranti K.; Hira, Priya; Sankhe, Shilpa; Pandit, Nilesh; Mittal, Kartik; Dey, Amit K. (2015): Hemangioma of Rib: A Different Perspective. In *Polish journal of radiology* 80, pp. 172–175. DOI: 10.12659/PJR.893011.
7. Gourgiotis, Stavros; Piyis, Anastasios; Panagiotopoulos, Nikolaos; Panayotopoulos, Panayotis; Salemis, Nikolaos S. (2010): Cavernous hemangioma of the rib: a rare diagnosis. In *Case reports in medicine* 2010, p. 254098. DOI: 10.1155/2010/254098.
8. Haro, Akira; Nagashima, Akira (2015): A rare case report of rib hemangioma mimicking a malignant bone tumor or metastatic tumor. In *International journal of surgery case reports* 16, pp. 141–145. DOI: 10.1016/j.ijscr.2015.09.036.
9. Hashimoto, Nobuyuki; Takenaka, Satoshi; Akimoto, Yasuyoshi; Tanaka, Hisashi; Morii, Eiichi; Minami, Masato; Yoshikawa, Hideki (2011): Capillary hemangioma in a rib presenting as large pleural effusion. In *The Annals of thoracic surgery* 91 (4), e59-61. DOI: 10.1016/j.athoracsur.2010.11.074.
10. Huang, Heping; Ning, Chengdong; Pan, Yu (2019): Giant cavernous hemangioma of the eleventh rib. In *Journal of cardiothoracic surgery* 14 (1), p. 95. DOI: 10.1186/s13019-019-0919-6.
11. Imai, Kentaro; Saji, Hisashi; Ikeda, Norihiko (2013): Cavernous hemangioma of the first rib. In *Asian cardiovascular & thoracic annals* 21 (4), pp. 488–489. DOI: 10.1177/0218492312457924.
12. Itabashi, Takahide; Emori, Makoto; Terashima, Yoshinori; Hasegawa, Tadashi; Shimizu, Junya; Nagoya, Satoshi; Yamashita, Toshihiko (2017): Hemangioma of the rib showing a relatively high 18F-FDG uptake: a case report

- with a literature review. In *Acta Radiologica Open* 6 (9). DOI: 10.1177/2058460117728416.
13. Jain, Sanjay K.; Songra, Moolchand; Malhotra, Amber; Kapoor, Neelkamal; Malik, Rini; Shrivastava, Adesh (2011): Rib haemangioma: a rare differential for rib tumours. In *The Indian journal of surgery* 73 (6), pp. 447–449. DOI: 10.1007/s12262-011-0278-6.
 14. Jia, Qiang; Meng, Zhaowei; Zhou, Qinghua; Li, Dong; Zhang, Yujie; Tan, Jian (2011): Asymptomatic rib cavernous hemangioma. In *Clinical nuclear medicine* 36 (12), pp. 1112–1114. DOI: 10.1097/RLU.0b013e31821c9ad4.
 15. Nakamura, Haruhiko; Kawasaki, Norihito; Taguchi, Masahiko; Kitamura, Hajime (2007): Cavernous hemangioma of the rib diagnosed preoperatively by percutaneous needle biopsy. In *General thoracic and cardiovascular surgery* 55 (3), pp. 134–137. DOI: 10.1007/s11748-006-0086-2.
 16. Ogose, A.; Hotta, T.; Morita, T.; Takizawa, T.; Ohsawa, H.; Hirata, Y. (2000): Solitary osseous hemangioma outside the spinal and craniofacial bones. In *Archives of orthopaedic and trauma surgery* 120 (5-6), pp. 262–266. DOI: 10.1007/s004020050461.
 17. Okumura, T.; Asamura, H.; Kondo, H.; Matsuno, Y.; Tsuchiya, R. (2000): Hemangioma of the rib: a case report. In *Japanese journal of clinical oncology* 30 (8), pp. 354–357. DOI: 10.1093/jjco/hyd097.
 18. Ortega, W.; Mahboubi, S.; Dalinka, M. K.; Robinson, T. (1986): Computed tomography of rib hemangiomas. In *Journal of Computer Assisted Tomography* 10 (6), pp. 945–947. DOI: 10.1097/00004728-198611000-00009.
 19. Oruc, Memduh; Atay, Ahmet Engin; Karabulut, Pervin; Pasa, Semir; Elbey, Ahmet; Ekin, Nazim; Yildirim, Serdar (2013): An unusual case of cavernous hemangioma of the rib in a young man with lung tuberculosis: a brief review and case report. In *Internal medicine (Tokyo, Japan)* 52 (11), pp. 1263–1265. DOI: 10.2169/internalmedicine.52.9212.
 20. Puri, Shailja; Gupta, Neelam; Asotra, Sarita (2018): Hemangioma of rib masquerading a malignancy. In *Journal of cancer research and therapeutics* 14 (Supplement), S809–S811. DOI: 10.4103/0973-1482.204847.
 21. Roy, Louis; Isler, Marc (2005): Surgical images: musculoskeletal. Costal hemangioma presenting as rib pain after pneumonia. In *Canadian journal of surgery. Journal canadien de chirurgie* 48 (2), p. 152.
 22. Shimizu, Katsuhiko; Yamashita, Yoshinori; Hihara, Jun; Seto, Yoshihiro; Toge, Tetsuya (2002): Cavernous hemangioma of the rib. In *The Annals of thoracic surgery* 74 (3), pp. 932–934. DOI: 10.1016/s0003-4975(02)03797-9.
 23. Tanaka, T.; Masaoka, Y.; Sugimoto, S.; Iguchi, T.; Hiraki, T.; Yanai, H.; Kanazawa, S. (2019): Cavernous hemangioma of the rib mimicking a chondrosarcoma: Diagnostic value of delayed phase MRI. In *Diagnostic and interventional imaging* 100 (7-8), pp. 455–457. DOI: 10.1016/j.diii.2019.04.002.
 24. Tew, Khimseng; Constantine, Sarah; Lew, Wendy Yuen Chee (2011): Intraosseous hemangioma of the rib mimicking an aggressive chest wall tumor. In *Diagnostic and interventional radiology (Ankara, Turkey)* 17 (2), pp. 118–121. DOI: 10.4261/1305-3825.DIR.3031-09.2.
 25. Weinandt, Marthe; Legras, Antoine; Mordant, Pierre; Le Pimpec Barthes, Françoise (2016): Chest wall resection for multifocal osseous haemangioma. In *Interactive cardiovascular and thoracic surgery* 22 (2), pp. 233–234. DOI: 10.1093/icvts/ivv321.
 26. Woo, Chang Gok; Lee, Ho-Chang; Son, Seung-Myoung; Hong, Jong-Myeon; Lee, Ok-Jun (2019): Clinicopathological characteristics of costal hemangiomas: a case report and literature review. In *The Journal of international medical research* 47 (2), pp. 982–985. DOI: 10.1177/0300060518809589.
 27. Yeow, K. M.; Hsieh, H. C. (2001): Thoracic outlet syndrome caused by first rib hemangioma. In *Journal of vascular surgery* 33 (5), pp. 1118–1121. DOI: 10.1067/mva.2001.112801.
 28. Young Park, Joon; gyoon Park, Jin; Jin Lee, Seung (2016): Cavernous Hemangioma of the Rib: A Case Report. In *Iranian Journal of Radiology* 13 (3). DOI: 10.5812/iranjradiol.31677.
 29. Zhu, You-Cai; Lin, Xue-Ping; Lu, Yan; Wang, Wen-Xian; Du, Kai-Qi; Ye, Xiao-Qian et al. (2017): Hemangioma of the Rib: A Rare Case Report and Literature Review. In *Open medicine (Warsaw, Poland)* 12, pp. 257–260. DOI: 10.1515/med-2017-0038.