

3-1-2004

# Pedicle subtraction osteotomy for the treatment of fixed sagittal imbalance: Surgical technique.

Keith H. Bridwell

*Washington University School of Medicine in St. Louis*

Stephen J. Lewis

*Washington University School of Medicine in St. Louis*

Anthony Rinella

*Loyola University Medical Center*

Lawrence G. Lenke

*Washington University School of Medicine in St. Louis*

Christy Baldus

*Washington University School of Medicine in St. Louis*

*See next page for additional authors*

Follow this and additional works at: [https://digitalcommons.wustl.edu/open\\_access\\_pubs](https://digitalcommons.wustl.edu/open_access_pubs)



Part of the [Medicine and Health Sciences Commons](#)

---

## Recommended Citation

Bridwell, Keith H.; Lewis, Stephen J.; Rinella, Anthony; Lenke, Lawrence G.; Baldus, Christy; and Blanke, Kathy, "Pedicle subtraction osteotomy for the treatment of fixed sagittal imbalance: Surgical technique." *The Journal of Bone and Joint Surgery*,. 44-49. (2004). [https://digitalcommons.wustl.edu/open\\_access\\_pubs/1052](https://digitalcommons.wustl.edu/open_access_pubs/1052)

---

**Authors**

Keith H. Bridwell, Stephen J. Lewis, Anthony Rinella, Lawrence G. Lenke, Christy Baldus, and Kathy Blanke

# Pedicle Subtraction Osteotomy for the Treatment of Fixed Sagittal Imbalance

## Surgical Technique

BY KEITH H. BRIDWELL, MD, STEPHEN J. LEWIS, MD, MSc, FRCSC, ANTHONY RINELLA, MD, LAWRENCE G. LENKE, MD, CHRISTY BALDUS, RN, AND KATHY BLANKE, RN

*Investigation performed at the Department of Orthopaedic Surgery, Barnes-Jewish Hospital and Washington University School of Medicine, St. Louis, Missouri*

*The original scientific article in which the surgical technique was presented was published in JBJS Vol. 85-A, pp. 454-463, March 2003*

### ABSTRACT

#### BACKGROUND:

Fixed sagittal imbalance (a syndrome in which the patient is only able to stand with the weight-bearing line in front of the sacrum) has many etiologies. The most commonly reported technique for correction is the Smith-Petersen osteotomy. Few reports on pedicle subtraction procedures (resection of the posterior elements, pedicles, and vertebral body through a posterior approach) are available in the peer-reviewed literature. We are aware of no report involving a substantial number of patients with coexistent scoliosis who underwent pedicle/vertebral body subtraction for the treatment of fixed sagittal imbalance.

#### METHODS:

Twenty-seven consecutive patients in whom sagittal imbalance was treated with lumbar pedicle subtraction osteotomy at one institution were analyzed. Radiographic analysis included assessment of

*continued*

### INTRODUCTION

Treatment of fixed sagittal imbalance involves performing osteotomies to shorten the spine. One option is to perform multiple Smith-Petersen procedures, which do not directly address the anterior column of the spine. Another option is to perform a pedicle subtraction osteotomy, which usually achieves about 30° of lordosis. Performance of that procedure amounts to performing two Smith-Petersen osteotomies as well as resection of the pedicles and vertebral body bilaterally from a posterior approach. This accomplishes approximately as much correction as can be achieved with three Smith-Petersen osteotomies, but it is technically much more demanding. The advantage of the pedicle subtraction osteotomy is that, when the osteotomy is completed, there is bone-on-bone contact throughout all three columns of the spine.

### SURGICAL TECHNIQUE

*Step 1:* Prior to the initiation of the osteotomy, the fixation points should be placed. In the illustrations in this article, pedicle screws are depicted. Next, a laminectomy is performed and the necessary posterior elements are resected (Fig. 1). If there is no coronal plane deformity, the wedge should be made symmetrically on both sides. When resecting the posterior elements, the surgeon should start off using hand instruments such as Leksell rongeurs, osteotomes, and curets to try to retain as much bone graft as possible. Then, if needed, a high-speed air-drill is used to thin the posterior elements. Finally, a Kerrison rongeur is used to surround the pedicles. The first step of surrounding the pedicles is to resect bone centrally and then to perform, in essence, a Smith-Petersen osteotomy both cephalad to and caudad to the pedicles on both sides. This involves exposing the nerve

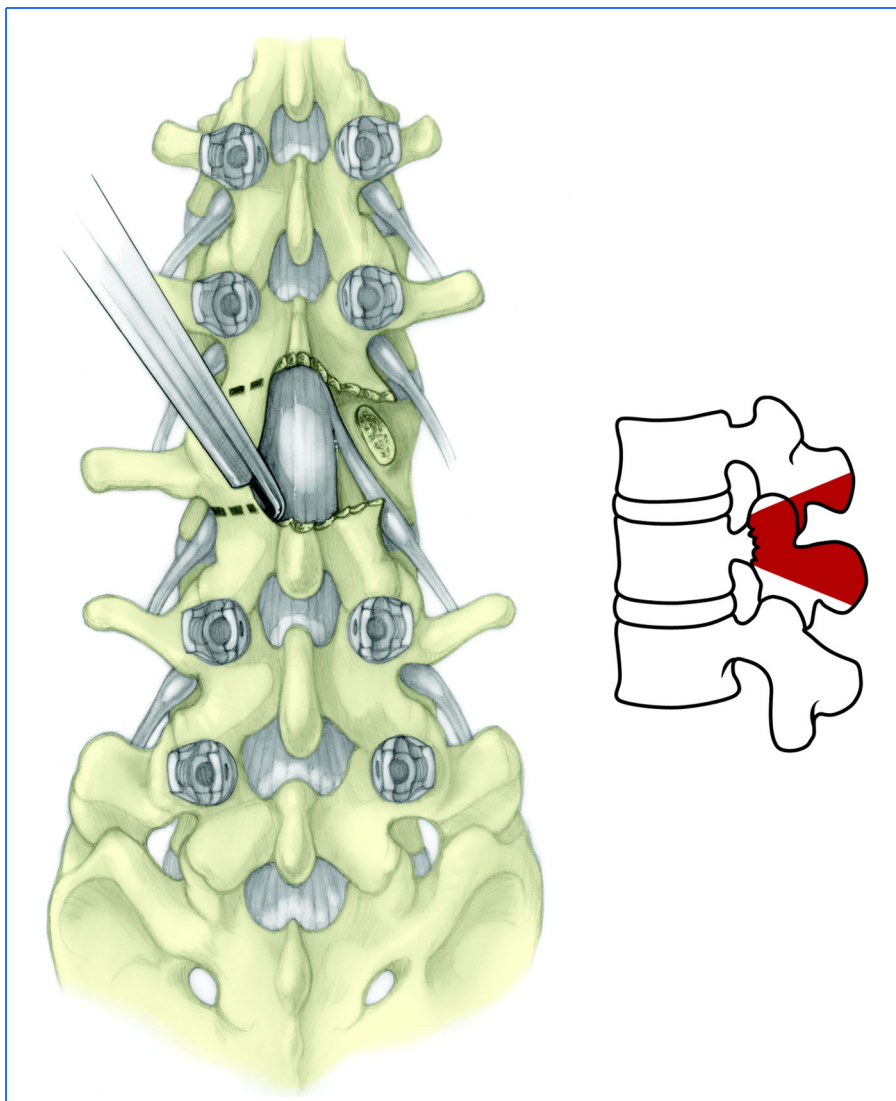


FIG. 1

The initial resection of the posterior elements and surrounding of the pedicles. The amount of bone resected is demonstrated in the lateral view in this figure and the subsequent figures.

root caudad to the pedicle, which, in the case illustrated, is the L3 nerve root. As the pedicles are circumferentially surrounded, they are detached from the transverse processes.

*Step 2:* The next step is to decancellate the pedicles and vertebral body (Fig. 2). The medial wall of the pedicle is identified, and the thecal sac and the nerve root are retracted with a Penfield retractor to identify the posterior wall of the vertebral body. It is helpful to move straight and curved curets and Woodson elevators back and forth from one side to the other until the resection of the vertebral body connects one side to the other. If there is bleeding from epidural vessels cephalad and caudad to the pedicles, it is best controlled

**ABSTRACT** | continued

thoracic kyphosis, lumbar lordosis, lordosis through the pedicle subtraction osteotomy site, and the C7 sagittal plumb line. Outcomes analysis was performed with use of a before-and-after pain scale, items from the Oswestry questionnaire, and the Scoliosis Research Society (SRS) questionnaire after a minimum duration of follow-up of two years. Complications and radiographic findings were also analyzed for the entire group.

**RESULTS:**

Overall, the average increase in lordosis was 34.1° and the average improvement in the sagittal plumb line was 13.5 cm. One patient had development of a lumbar pseudarthrosis through the area of pedicle subtraction osteotomy, and six patients had development of a thoracic pseudarthrosis. Two patients had development of increased kyphosis at L5/S1, caudad to the fusion, resulting in some loss of sagittal correction. There were significant improvements in the overall Oswestry score ( $p < 0.0001$ ) and the pain-scale score ( $p = 0.0002$ ). Most patients reported improvement in terms of pain and self-image as well as overall satisfaction with the procedure.

**CONCLUSIONS:**

Pedicle subtraction osteotomy is a useful procedure for patients with fixed sagittal imbalance. A worse clinical result is associated with increasing patient comorbidities, pseudarthrosis in the thoracic spine, and subsequent breakdown caudad to the fusion.

## CRITICAL CONCEPTS

### INDICATIONS:

The main candidate for a pedicle subtraction osteotomy is a patient with some component of fixed sagittal imbalance who needs to have approximately 30° of additional lordosis.

The four most common presentations are:

1. A patient who previously had surgery for idiopathic scoliosis, usually with instrumentation and fusion to L3 or L4, in whom the lumbar spine was fused with a component of hypolordosis and the discs subsequently degenerated at L3-L4, L4-L5, and L5-S1.
2. A patient with what we term a “degenerative sagittal imbalance.” Such a patient has usually had several lower lumbar fusions for degenerative spine disease. With each fusion, the tendency is to lose some lower lumbar lordosis. Subsequently, the segments above degenerate and fall into kyphosis, and the patient is not able to stand erect.
3. A patient with a sharp, angular post-traumatic kyphosis. Not uncommonly, there is some component of pseudarthrosis within the kyphosis. Pain usually emanates either from a pseudarthrosis at the apex of the kyphosis or from breakdown and disc degeneration caudad to the kyphosis from discs caudad to the fusion having to hyperextend to maintain balance. In this circumstance, usually the appropriate treatment is pedicle subtraction osteotomy through the previous fusion and then incorporation of the severely degenerated segments below into the fusion.

*continued*

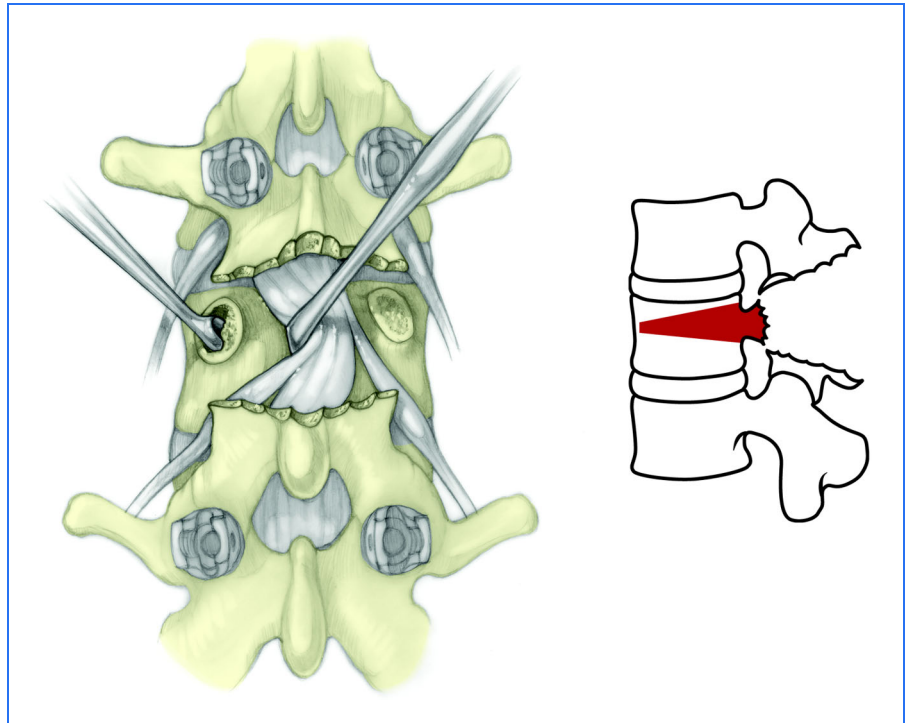


FIG. 2

Decancellation of the pedicles and the vertebral body.

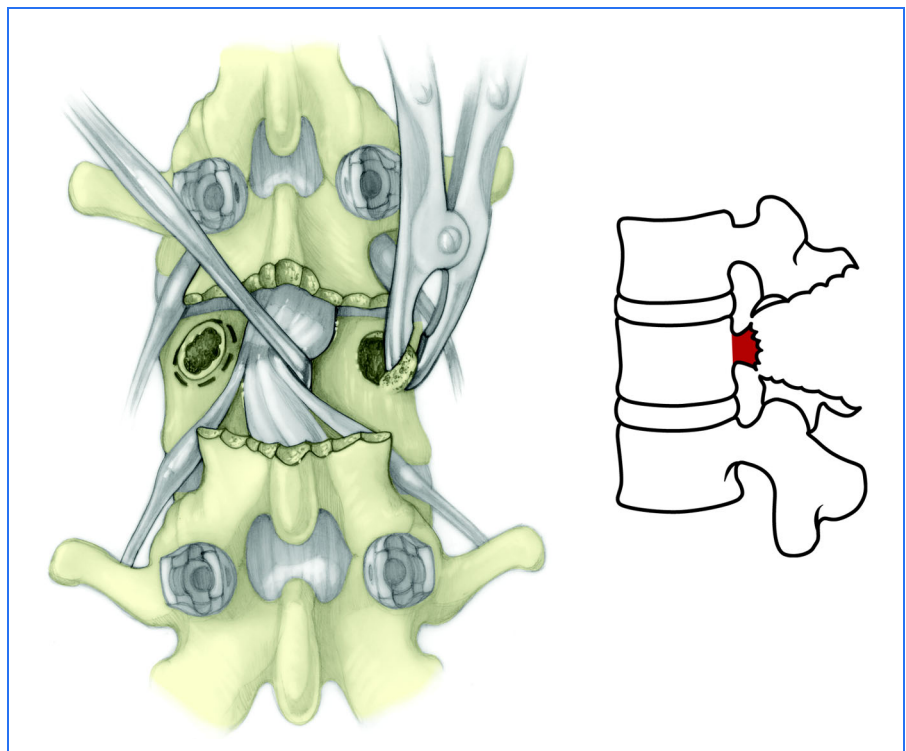


FIG. 3

Resection of the pedicles flush with the posterior aspect of the vertebral body.

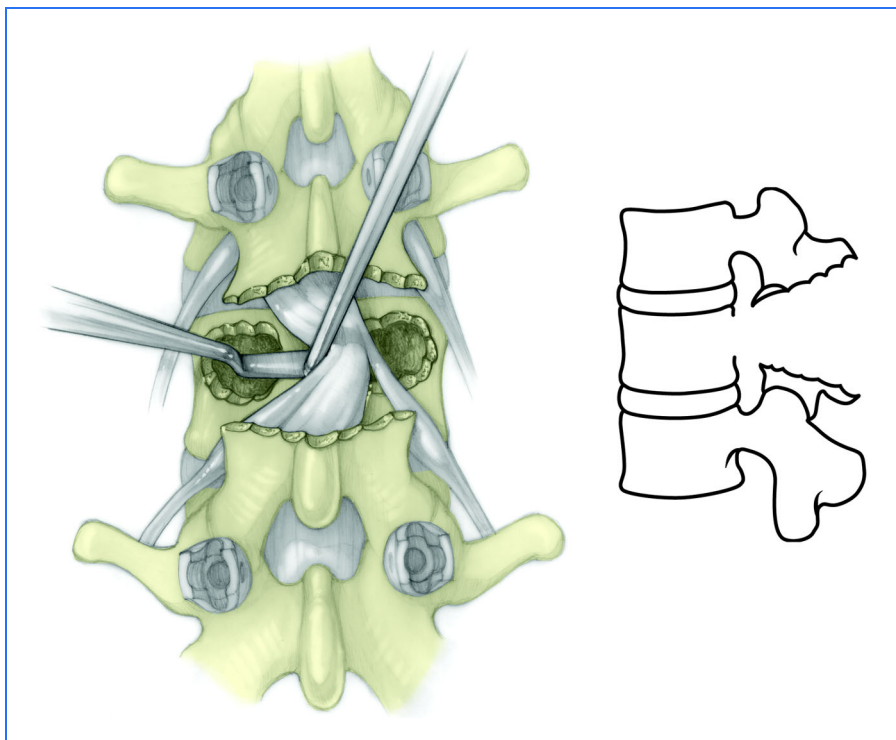


FIG. 4

Greenstick fracture and resection of the posterior vertebral cortex.

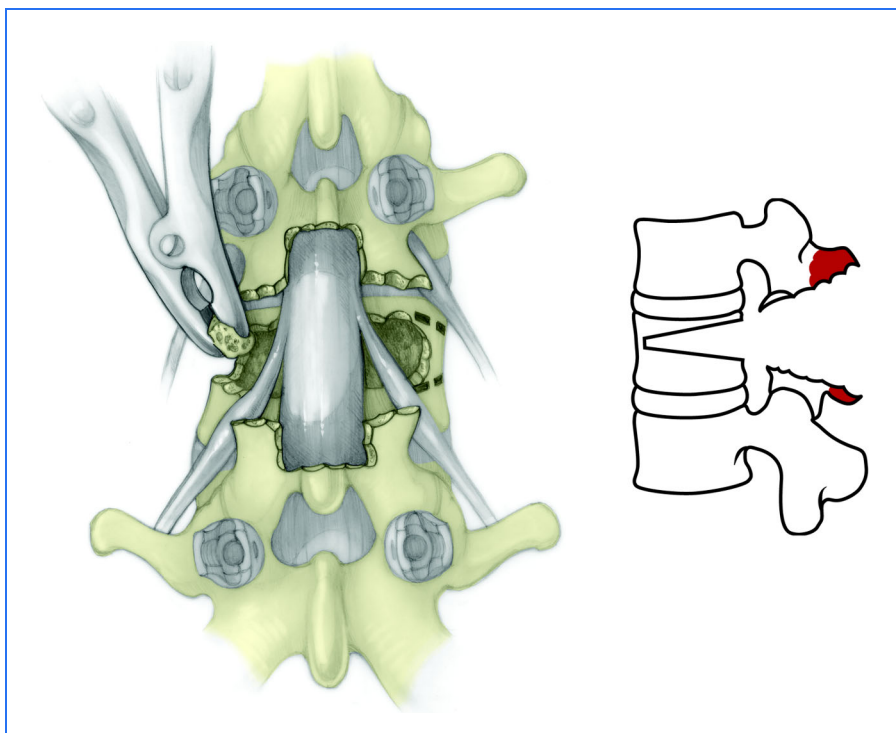


FIG. 5

Resection of the lateral walls and central canal enlargement. Note the v-shaped wedge.

## CRITICAL CONCEPTS | continued

### INDICATIONS (continued):

4. Patients with ankylosing spondylitis often present with cervicothoracic kyphosis or thoracolumbar kyphosis. The pedicle subtraction procedure is primarily indicated for sagittal imbalance secondary to the thoracolumbar kyphosis.

### CONTRAINDICATIONS:

In order to benefit from the pedicle subtraction surgery, the patient has to be physiologically young enough and not have substantial comorbidities. Relative contraindications are psychiatric disease, diabetes, osteoporosis, substantial cardiopulmonary disease, and poor family or social support. An older patient who does not have a fusion mass and needs to have a substantial number of segments treated with instrumentation and fusion is a relatively poor candidate because of the much lower likelihood of achieving a solid fusion throughout all of the segments.

Also, the amount of correction that is desired needs to be matched to the surgical procedure. If the patient needs only 10° to 20° of lordosis or 4 to 7 cm of correction of the C7 plumb, then it may be more appropriate to perform a more limited number of Smith-Petersen osteotomies rather than doing a pedicle subtraction procedure.

Pedicle subtraction procedures can be performed through areas in which a laminectomy had been performed, but it is more technically challenging to do so and the likelihood of achieving a solid fusion is much lower than the likelihood with a pedicle subtraction procedure through a solid fusion mass.

*continued*

**CRITICAL CONCEPTS** | continued**CONTRAINDICATIONS (continued):**

Patients with a degenerative cause of the sagittal imbalance are much less likely to have a good result than are those in the other three categories described under "Indications." In part, this relates to the fact that these patients are older and usually have more segments that have to be incorporated into the fusion. Furthermore, in general, the more previous spine procedures that a patient has had, the less likely he or she is to have an excellent result.

**PITFALLS:**

The principal problems that we have had with the procedure are: (1) neurologic deficit, (2) pseudarthrosis, (3) blood loss, and (4) proximal junctional kyphosis.

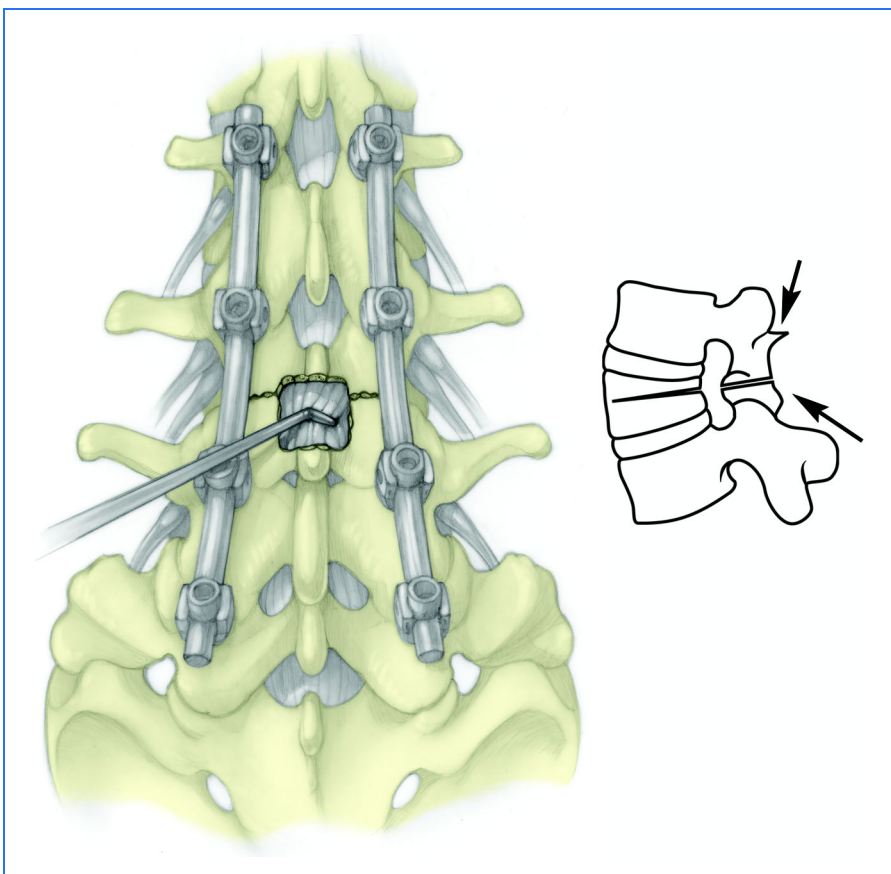
If the procedure is done through a prior fusion mass, then the likelihood for healing with posterior-only surgery is quite high. However, it is important to close down the lateral masses very tightly. Although not everybody agrees with us, our preference is to always enlarge the spinal canal somewhat more centrally and to pass a nerve hook or Woodson elevator north, south, east, and west to be sure that there is no dorsal compression of the dura and also to watch carefully and evaluate the extent of dorsal dural buckling that occurs. It would appear that as long as the lateral masses are squeezed together very tightly, leaving the canal somewhat open centrally does not compromise the likelihood of achieving a solid fusion.

*continued*

with a surface hemostatic agent and packing with cottonoids. At this point of the procedure, one should try to preserve the medial wall of the pedicle.

*Step 3:* Next, the pedicle stump is resected on both sides flush with the vertebral body (Fig. 3). This is done with a combination of a Kerrison rongeur from within the pedicle and a thin Leksell rongeur from without. Care should be taken to retract the neural elements so that the exiting nerve root is not injured during the process.

*Step 4:* The next step is to finish the resection of the posterior wall of the vertebral body. Working underneath the posterior vertebral cortex, the surgeon thins the cortex as much as possible with curets and Woodson elevators. Once the posterior wall of the vertebral body is thin enough, a Woodson elevator or a substantial reverse-angled curet is placed between the anterior dura and the posterior vertebral cortex and pushed anteriorly to create a greenstick fracture of the posterior vertebral cortex. The fractured posterior cortex is then removed (Fig. 4). At this point, the osteotomy is still stable because the lateral vertebral body walls remain intact. The amount of the posterior wall that is removed should be symmetrical.



**FIG. 6**

Closure of the osteotomy and final instrumentation.

*Step 5:* Next, the spinal canal is enlarged centrally somewhat more with use of Kerrison rongeurs, but the surgeon must be sure that the lateral masses remain symmetrical. In preparation for resection of the lateral vertebral body walls, the surgeon first dissects them with a small Cobb or Penfield elevator. The lateral vertebral cortex should be hugged during the dissection so that the segmental vessel is not injured. Then, a Leksell rongeur is used to resect the lateral vertebral body walls down to, but not through, the anterior cortex (Fig. 5). Once this is accomplished on both sides, the osteotomy is complete.

*Step 6:* The final step is to close the osteotomy (Fig. 6). Depending on the circumstance, this can be accomplished by either applying compression or cantilevering the spine. Also, hyperextending the patient's chest and lower extremities may accomplish closure. Sometimes, when this step is performed, subluxation occurs, most commonly with the proximal elements subluxating dorsally on the distal elements. If this does occur, the subluxation needs to be reduced anatomically as the final implants are placed. When the construct is complete and the osteotomy is closed on both sides, the spinal canal is dissected, first with a nerve hook and then with a Woodson elevator to confirm that there is no dorsal compression of the dural sac. The lateral masses should be squeezed together very tightly to promote stability and osteogenesis.

## CRITICAL CONCEPTS | continued

### PITFALLS (continued):

We have found that spinal cord monitoring is not always predictive of neurologic deficits. A global spinal cord or cauda equina syndrome is usually predicted, but compression of one or two nerve roots unilaterally may not be identified by any type of intraoperative monitoring (dermatomal, somatosensory, or spontaneous electromyographic monitoring). Thus, we always perform a wake-up test after we close the osteotomy.

The problem of substantial blood loss has been reduced quite a bit by using surface hemostatic agents and packing. Most of the intraoperative bleeding actually occurs from epidural vessels, not from the bone. Also, when we have to remove quite a bit of instrumentation and then establish many new fixation points through distorted anatomy, we find that it is often beneficial to perform the surgery in stages. In the first stage, the implants are removed and new fixation points are created. In the second stage, we perform the osteotomy. Staging the procedure reduces the amount of blood loss during one procedure.

Pseudarthrosis is most likely to occur when the pedicle subtraction procedure is performed through an area without prior fusion. Also, it may be difficult to achieve a solid fusion at segments that are added to the construct. Furthermore, if the pedicle subtraction procedure is performed through an area of previous pseudarthrosis, nonunion is possible. Thus, the pedicle subtraction procedure does not totally eliminate the need for anterior surgery in some patients.

For patients with osteoporosis and degenerative sagittal imbalance, our preference has often been to try to end the fusion in the lower thoracic or upper lumbar spine rather than automatically extending it cephalad to T3 or T4. We do this both to limit the magnitude of the procedure and to reduce the number of fusion segments that are being added cephalad. However, a problem that has occasionally occurred is fracture of the vertebral body at the upper level or one level cephalad to it. The exact remedy for this problem is not entirely clear. A brace provides some protection, but patients often are not compliant with regard to wearing the brace.

### AUTHOR UPDATE:

The use of staging and topical hemostatic agents was discussed in the "Pitfalls" section of this article. To some extent, we have recently been more restrictive with regard to the kind of patient we will consider for the procedure on the basis of comorbidity factors previously discussed.

We always try to resect as much of the pedicle as we can. Leaving behind some residual pedicle produces a risk of foraminal stenosis. In many cases, it is possible to perform a pedicle subtraction procedure safely and to close it down all the way across without causing dural impingement if the osteotomy has been adequately undercut. However, in some instances, undercutting the osteotomy centrally is not adequate. Therefore, our preference is to always create a central enlargement that allows us to use a tool such as a Woodson elevator or a nerve hook to explore the spinal canal dorsally cephalad and caudad (Fig. 6).

*continued*



**CRITICAL CONCEPTS** | continued**AUTHOR UPDATE (continued):**

When performing the procedure, we always place our fixation points cephalad and caudad before we perform the osteotomy. Although the osteotomy can be performed through segments that are somewhat rotated, it is technically easier to carry out the procedure through a neutrally rotated segment and through a segment that is fairly close to the apex of the kyphosis without prior dural dissection.

The techniques for closing the osteotomy vary quite a bit according to the presentation of the patient. Closing usually involves a combination of some cantilevering as well as compression and physically hyperextending the patient on the table through the chest and the lower extremities. At times, direct compression force can be applied through the fixation points. In other circumstances, though, the bone stock may not be strong enough to allow compression with use of the fixation points. In that situation, it is better to hyperextend the patient's chest above and the lower extremities below on the frame.

Keith H. Bridwell, MD  
Stephen J. Lewis, MD, MSc, FRCS  
Lawrence G. Lenke, MD  
Christy Baldus, RN  
Kathy Blanke, RN  
Department of Orthopaedic Surgery, Washington University School of Medicine, One Barnes-Jewish Hospital Plaza, Suite 11300 West Pavilion, St. Louis, MO 63110. E-mail address for K.H. Bridwell: [bridwellk@wustl.edu](mailto:bridwellk@wustl.edu)

Anthony Rinella, MD  
Department of Orthopaedic Surgery and Rehabilitation, Loyola University Medical Center, Macguire Center, Suite 1700, 2160 South First Avenue, Maywood, IL 60153

The authors did not receive grants or outside funding in support of their research or preparation of this manuscript. They did not receive payments or other benefits or a commitment or agreement to provide such benefits from a commercial entity. No commercial entity paid or directed, or agreed to pay or direct, any benefits to any research fund, foundation, educational institution, or other charitable or nonprofit organization with which the authors are affiliated or associated.

The line drawings in this article are the work of Elizabeth Roselius ([roselius@optonline.net](mailto:roselius@optonline.net)).