

Washington University School of Medicine

Digital Commons@Becker

2020-Current year OA Pubs

Open Access Publications

2-1-2021

Robotic bronchoscopy for peripheral pulmonary lesions: A multicenter pilot and feasibility study (BENEFIT)

Alexander C Chen

Washington University School of Medicine in St. Louis

Nicholas J Pastis Jr

Medical University of South Carolina

Amit K Mahajan

Inova Health System

Sandeep J Khandhar

Inova Health System

Michael J Simoff

Henry Ford Hospital

See next page for additional authors

Follow this and additional works at: https://digitalcommons.wustl.edu/oa_4



Part of the [Medicine and Health Sciences Commons](#)

Please let us know how this document benefits you.

Recommended Citation

Chen, Alexander C; Pastis, Nicholas J Jr; Mahajan, Amit K; Khandhar, Sandeep J; Simoff, Michael J; Machuzak, Michael S; Cicensia, Joseph; Gildea, Thomas R; and Silvestri, Gerard A, "Robotic bronchoscopy for peripheral pulmonary lesions: A multicenter pilot and feasibility study (BENEFIT)." *Chest*. 159, 2. 845 - 852. (2021).

https://digitalcommons.wustl.edu/oa_4/1222

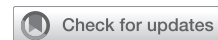This Open Access Publication is brought to you for free and open access by the Open Access Publications at Digital Commons@Becker. It has been accepted for inclusion in 2020-Current year OA Pubs by an authorized administrator of Digital Commons@Becker. For more information, please contact vanam@wustl.edu.

Authors

Alexander C Chen, Nicholas J Pastis Jr, Amit K Mahajan, Sandeep J Khandhar, Michael J Simoff, Michael S Machuzak, Joseph Cicenia, Thomas R Gildea, and Gerard A Silvestri

Robotic Bronchoscopy for Peripheral Pulmonary Lesions

A Multicenter Pilot and Feasibility Study (BENEFIT)



Alexander C. Chen, MD; Nicholas J. Pastis Jr, MD; Amit K. Mahajan, MD; Sandeep J. Khandhar, MD; Michael J. Simoff, MD; Michael S. Machuzak, MD; Joseph Cicenia, MD; Thomas R. Gildea, MD; and Gerard A. Silvestri, MD



BACKGROUND: The diagnosis of peripheral pulmonary lesions (PPL) continues to present clinical challenges. Despite extensive experience with guided bronchoscopy, the diagnostic yield has not improved significantly. Robotic-assisted bronchoscopic platforms have been developed potentially to improve the diagnostic yield for PPL. Presently, limited data exist that evaluate the performance of robotic systems in live human subjects.

RESEARCH QUESTION: What is the safety and feasibility of robotic-assisted bronchoscopy in patients with PPLs?

STUDY DESIGN AND METHODS: This was a prospective, multicenter pilot and feasibility study that used a robotic bronchoscopic system with a mother-daughter configuration in patients with PPL 1 to 5 cm in size. The primary end points were successful lesion localization with the use of radial probe endobronchial ultrasound (R-EBUS) imaging and incidence of procedure related adverse events. Robotic bronchoscopy was performed in patients with the use of direct visualization, electromagnetic navigation, and fluoroscopy. After the use of R-EBUS imaging, transbronchial needle aspiration was performed. Rapid on-site evaluation (ROSE) was used on all cases. Transbronchial needle aspiration alone was sufficient when ROSE was diagnostic; when ROSE was not diagnostic, transbronchial biopsy was performed with the use of the robotic platform, followed by conventional guided bronchoscopic approaches at the discretion of the investigator.

RESULTS: Fifty-five patients were enrolled at five centers. One patient withdrew consent, which left 54 patients for data analysis. Median lesion size was 23 mm (interquartile range, 15 to 29 mm). R-EBUS images were available in 53 of 54 cases. Lesion localization was successful in 51 of 53 patients (96.2%). Pneumothorax was reported in two of 54 of the cases (3.7%); tube thoracostomy was required in one of the cases (1.9 %). No additional adverse events occurred.

INTERPRETATION: This is the first, prospective, multicenter study of robotic bronchoscopy in patients with PPLs. Successful lesion localization was achieved in 96.2% of cases, with an adverse event rate comparable with conventional bronchoscopic procedures. Additional large prospective studies are warranted to evaluate procedure characteristics, such as diagnostic yield.

CLINICAL TRIAL REGISTRATION: ClinicalTrials.gov; No.: NCT03727425; URL: www.clinicaltrials.gov.
CHEST 2021; 159(2):845-852

KEY WORDS: peripheral pulmonary lesion; radial probe endobronchial ultrasound imaging; rapid on-site evaluation; robotic bronchoscopy

ABBREVIATIONS: IQR = interquartile range; R-EBUS = radial endobronchial ultrasound; ROSE = rapid on-site evaluation; TBNA = transbronchial needle aspiration

AFFILIATIONS: From the Washington University School of Medicine (Dr Chen), St. Louis, MO; Medical University of South Carolina (Drs Pastis and Silvestri), Charleston, SC; Inova Health System

An estimated 1.5 million new pulmonary nodules are expected to be detected in the United States annually.¹ Widespread adoption of lung cancer screening programs is expected to further increase these numbers in the coming years. Although the majority of these nodules may simply require surveillance imaging, many will require biopsy.

Despite technologic advancements in guided bronchoscopy such as electromagnetic navigation bronchoscopy, ultrathin bronchoscopy, and radial probe endobronchial ultrasound (R-EBUS) imaging, the diagnostic yield of bronchoscopic approaches for peripheral nodules has been inconsistent in randomized controlled studies, ranging from 40% to 60%.²⁻⁴

Potential limitations to current approaches include challenges that advance the bronchoscope into peripheral airways due to size limitations of the scope as subsegmental bronchi become progressively smaller as they extend peripherally. In addition, subsegmental bronchi often branch at varying angles, which may be difficult to negotiate with the use of conventional bronchoscopes. These factors may limit operators' ability to advance the bronchoscope into close proximity to peripheral pulmonary lesions when attempting biopsy and may negatively affect the diagnostic yield of the procedure.

Robotic surgery has been performed across many platforms that include urologic, gynecologic, and thoracic surgery and offers potential advantages of improved dexterity and visualization while maintaining minimally invasive approaches.⁵ Early preclinical experience with a robotic endoscopic system within human cadaveric lungs demonstrated increased reach into the lung periphery with the robotic platform compared with a similarly sized bronchoscope in both tortuous and relatively straightforward segmental bronchi.⁶ Additional preclinical studies demonstrated high accuracy with the use of the robotic system to perform transbronchial needle aspiration (TBNA) of simulated tumor targets sized 1 to 3 cm in cadaveric lungs and the ability to place biopsy instruments within targeted lesions in cadaver models with a greater degree of accuracy compared with conventional guided approaches.^{7,8} Presently, very few data exist regarding the use of a robotic endoscopic system in live human subjects with peripheral lesions in need of biopsy.^{9,10}

This study was performed to assess the feasibility of performing robotic bronchoscopy to locate peripheral lesions in patients and to evaluate the safety and performance characteristics of procedures in a multicenter, prospective trial.

Methods

This was a multicenter, prospective pilot study of robotic bronchoscopy in patients with peripheral pulmonary lesions 1 to 5 cm in size and no evidence of disease in mediastinal or hilar lymph nodes by CT or PET imaging. CT scans were performed with the use of a standardized protocol with slice thickness of 1 to 1.25 mm, with variations dependent on the manufacturer of the CT scanner. Five study sites participated; each site enrolled 11 study patients. Consecutive patients who met inclusion and exclusion criteria were considered for this study. All study procedures were performed with general anesthesia in a dedicated operating room or endoscopy suite. The study was approved by each center's institutional review board.

(Drs Mahajan and Khandhar), Falls Church, VA; Henry Ford Hospital (Dr Simoff), Detroit, MI; Cleveland Clinic (Drs Machuzak, Cicienia, and Gildea), Cleveland, OH.

FUNDING/SUPPORT: This study was supported by research funding from Auris Health.

CORRESPONDENCE TO: Alexander C. Chen, MD, Divisions of Pulmonary and Critical Care Medicine and Cardiothoracic Surgery, Washington University School of Medicine, Campus Box 8052, 4523 Clayton Ave, St. Louis, MO 63110; e-mail: chenac@wustl.edu

Copyright © 2020 The Authors. Published by Elsevier Inc under license from the American College of Chest Physicians. This is an open access article under the CC BY-NC-ND license (<http://creativecommons.org/licenses/by-nc-nd/4.0/>).

DOI: <https://doi.org/10.1016/j.chest.2020.08.2047>

Bronchoscopy

Flexible bronchoscopy with airway inspection was performed initially to exclude the presence of endobronchial disease and to provide topical anesthesia, as per the discretion of the bronchoscopist. Following this, the robotic bronchoscopic system (Monarch; Auris Health) was connected to the existing endotracheal tube. The robotic bronchoscopic system is composed of a tower with monitor and a unit that houses arms that control insertion, retraction, and articulation of an outer sheath (6.0 mm outer diameter) and inner scope (4.4 mm outer diameter) that has a 2.1-mm working channel. With the use of a hand-held controller, the sheath and scope may be driven independently or simultaneously as a unit (Fig 1). Electromagnetic navigation bronchoscopy is incorporated into the system to provide navigational support with a CT scan that was obtained within 2 weeks of the procedure (Fig 2).

With the robotic system in place, the sheath and scope were driven simultaneously to the targeted lobe where the outer sheath was left in position. Subsequently, the inner scope was advanced distally into the lobar and segmental bronchi with a combination of direct visualization, electromagnetic navigation, and fluoroscopic guidance towards the targeted lesion.

Radial Endobronchial Ultrasound Imaging

Once the robotic scope was positioned at the targeted location, a R-EBUS imaging probe (UM S20-17S; Olympus Tokyo) was introduced through the working channel of the system and was used to survey the lung parenchyma and confirm lesion localization.

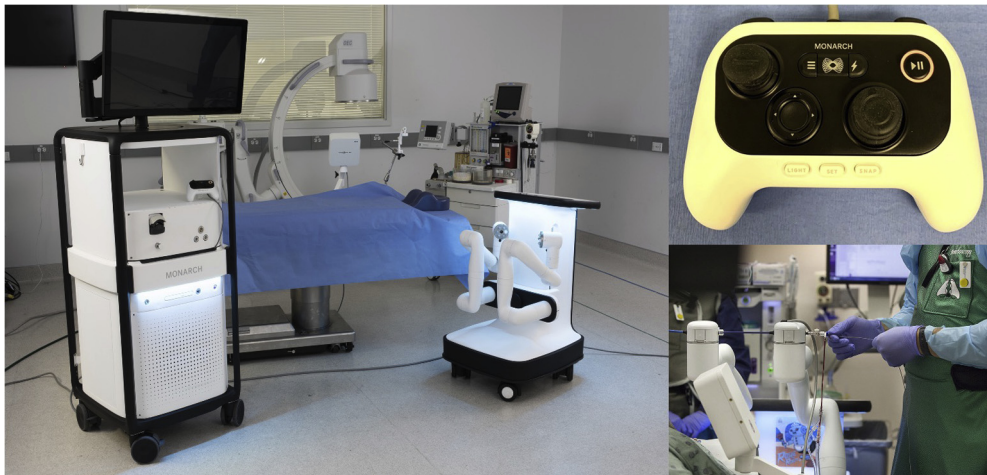

Figure 1 – Robotic bronchoscopy components: Robotic tower and handheld controller.

Radial ultrasound images were recorded as “concentric” when the ultrasound representation of the targeted lesion surrounded the R-EBUS imaging probe and “eccentric” when the ultrasound image was biased to one side of the probe with no component of the lesion surrounding the probe. If no lesion could be identified with the use of R-EBUS imaging, this was also recorded.

Biopsy

After evaluation with R-EBUS imaging, biopsy of the targeted lesion was performed with TBNA (Fig 3). Three TBNA specimens were obtained from each lesion, which was followed by rapid on-site evaluation (ROSE) of plated specimens. In cases in which ROSE was diagnostic, no further biopsy specimens were required. In cases in which ROSE was not diagnostic, three transbronchial biopsies were performed.

Crossover Procedures

For cases in which TBNA with ROSE were not diagnostic, conventional bronchoscopic approaches such as electromagnetic navigation or thin bronchoscopy with radial ultrasound imaging were performed at the discretion of the bronchoscopist after transbronchial biopsy as described earlier. Pathologic specimens that were collected through crossover procedures were separated from those that were collected during robotic bronchoscopy; characteristics (such as procedure time, biopsy instruments, and diagnostic yield) were likewise noted.

After Bronchoscopy

All patients received postprocedure chest radiography within 2 hours after bronchoscopy to evaluate for the presence of pneumothorax.

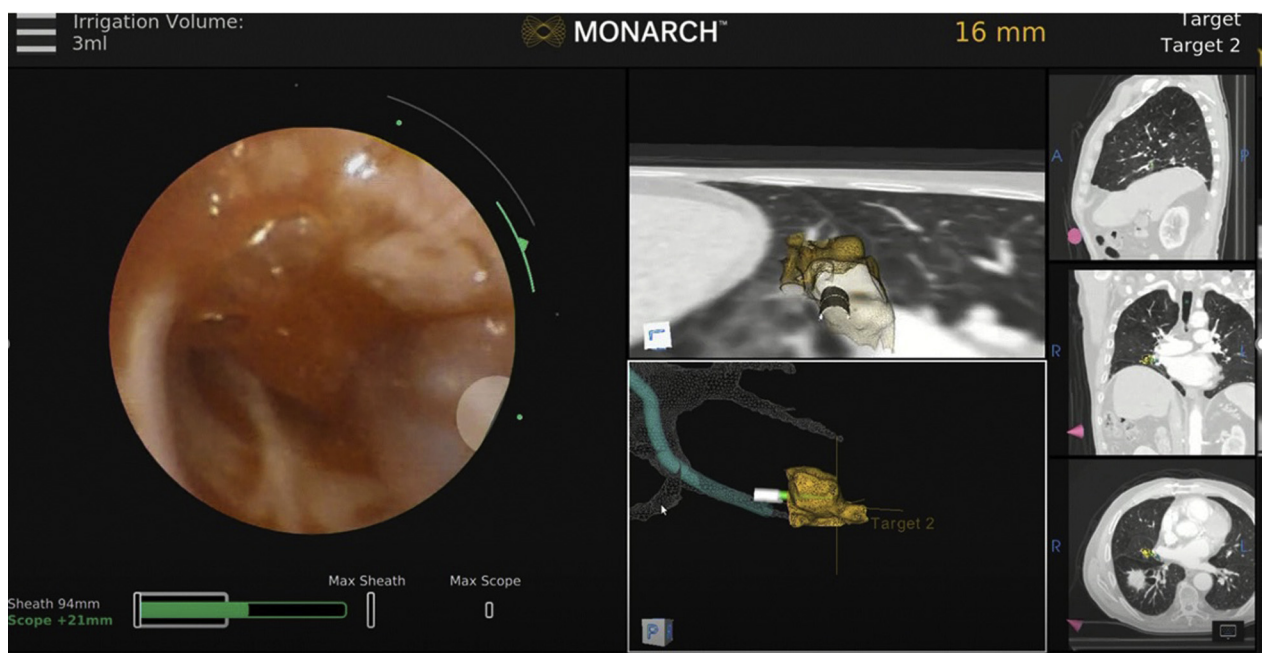


Figure 2 – Robotic system user interface shows live bronchoscopic, electromagnetic navigation bronchoscopy with targeting, and multiplanar CT views.

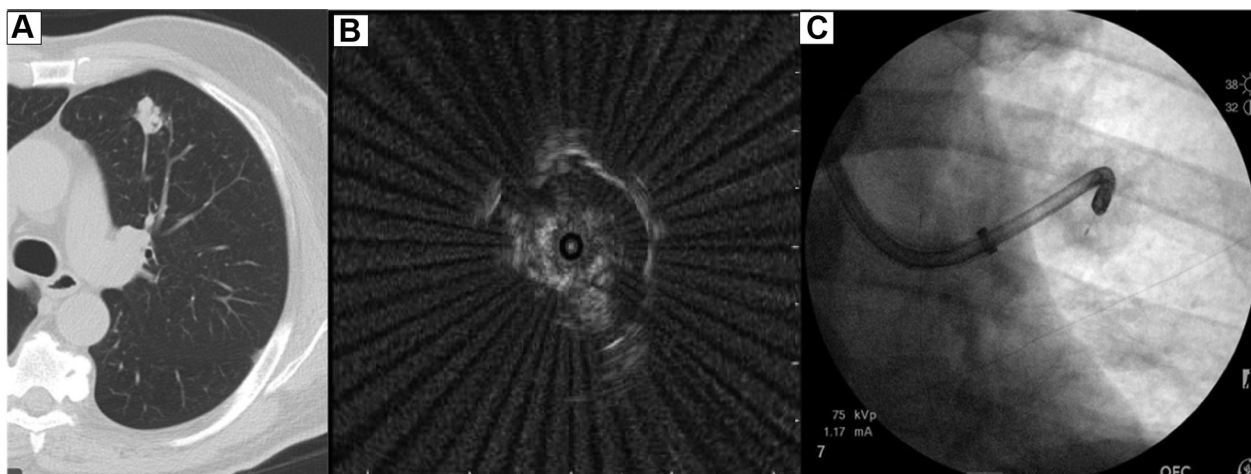


Figure 3 – A-C: A, CT image; B, concentric radial endobronchial ultrasound view; C, robotic bronchoscopy with transbronchial needle aspiration.

Patients were recovered and discharged as per each institution's standard practice.

End Points

The primary efficacy end point of this study was confirmation of lesion localization with R-EBUS imaging; the primary safety end point was the incidence of procedure- or device-related adverse events. The secondary end points included procedure time, insertion depth by bronchus generation count, and the distance from the tip of the robotic scope to the center of the targeted lesion. An exploratory end point was diagnostic yield at 12-month follow up.

Definitions

Peripheral Pulmonary Lesion: Peripheral pulmonary lesions were defined as lesions surrounded by pulmonary parenchyma that were deemed inaccessible with convex probe endobronchial ultrasound imaging by the bronchoscopist and without any evidence of endobronchial disease during airway inspection.

Safety: Procedure or device adverse events were defined as (1) pneumothorax of any kind, regardless of the need for tube thoracostomy, (2) bleeding during bronchoscopy that required intervention, and (3) change in patient status after bronchoscopy, such as hospital admission (if outpatient) or transfer to the ICU.

Diagnostic and Nondiagnostic Biopsy Specimens: A "diagnostic" specimen was based on cytopathologic results and was defined as a biopsy that resulted in a specific malignant process or a specific

diagnosis of a nonmalignant process that explained the presence of a peripheral pulmonary lesion (ie, granuloma, fungal elements). A biopsy that showed "inflammation" was considered truly diagnostic only if the targeted lesion demonstrated improvement or resolution on follow-up imaging or if subsequent surgical biopsy specimens confirmed the finding of inflammation. If follow-up imaging was unavailable, a finding of "inflammation" was considered nondiagnostic. Specimens reported as "atypical cells" were considered nondiagnostic. Biopsy specimens that showed normal pulmonary elements only on cytopathologic examination were also considered nondiagnostic, regardless of improvement on follow-up imaging, because these biopsy specimens were not believed to be representative of the targeted peripheral lesion. All patients received follow up for at least 1 year, and all biopsy results were independently evaluated by two investigators (A. C, C., G. A. S.) for consistency.

Statistical Analysis

Statistical analysis was performed with JMP 14.0 software (SAS Institute) statistical program. The Shapiro–Wilk test was used for normality testing. Continuous, normally distributed data were presented as the mean \pm SD. Data with skewed distribution were reported as the median (interquartile range [IQR]). Fisher exact test was used to compare proportions. The 95% CI was calculated for outcomes of interest to show the precision of an estimate. A probability value of $<.05$ was considered significant.

Results

Fifty-five patients were enrolled across five study sites. One patient withdrew consent that results in 54 patients being available for data analysis.

Patient and Lesion Characteristics

Median lesion size measured as longest cross-sectional diameter on axial imaging was 23 mm (IQR, 15 to 29 mm), with 23 of 54 nodules (42.6%) being 10 to 20 mm, with 19 of 54 nodules (35.2%) being 21 to 30 mm, and 12 of 54 lesions (22.2%) being 31 to

50 mm. Seventy-eight percent of lesions were ≤ 30 mm, which represented true pulmonary nodules. Thirty-two of 54 patients (59.3%) had a bronchus sign defined as a visible bronchus that was observed on axial, coronal, or sagittal CT view that came in contact with any portion of the lesion. Lesion distribution is reported in Table 1.

Primary Efficacy End Point: Lesion Localization

R-EBUS imaging was available in 53 of 54 cases. Lesion localization

TABLE 1] Baseline Characteristics

Characteristic	Value
Patient	
Total, ^a No.	54
Female, No. (%)	29 (53.7)
Age, mean (SD), y	67.1 (8.5)
BMI, mean (SD), kg/m ²	28.8 (6.3)
Lesion	
Nodule size, mean (SD), ^b mm	23.2 (10.8)
≤20	23 (42.6)
21-30	19 (35.2)
>30	12 (22.2)
Bronchus sign, No. (%)	32 (59.3)
Nodule location, No. (%)	
Right upper lobe	19 (35.2)
Left upper lobe	12 (22.2)
Right middle lobe	6 (11.1)
Right lower lobe	8 (14.8)
Left lower lobe	9 (16.7)

^aFifty-five patients enrolled; one patient withdrew consent.

^bMeasured as longest diameter on axial CT imaging.

was confirmed with radial probe endobronchial ultrasound imaging in 51 of 53 patients (96.2%; 95% CI, 86.5-99.7%). Concentric R-EBUS imaging views were obtained in 31 of 51 cases (60.8%; 95% CI, 47.1-73.0%) and eccentric R-EBUS imaging views in 20 of 51 cases (39.2%; 95% CI, 27.0-52.9%), respectively. Median time to lesion confirmation was 13 minutes (IQR, 10 to 24 min).

Primary Safety End Point: Adverse Events

Pneumothorax occurred in two of 54 cases (3.7%; 95% CI, 0.3-13.3%), which required tube thoracostomy in one case (1.9%; 95% CI, <0.01-10.7%). No evidence of airway trauma was observed on insertion or retraction of the robotic bronchoscope. No other significant adverse events were noted.

Secondary End Point: Procedure Characteristics

Median procedure time, defined as robotic scope insertion to removal, was 51 minutes (IQR, 44-64 min). Median insertion depth by bronchus generation count was 5.5 (IQR, 5-7). Median distance from the tip of the robotic scope to the center of the targeted lesion was 23 mm (IQR, 14-32 mm) (Table 2).

Exploratory End Point: Diagnostic Yield

A diagnosis was obtained in 40 of 54 patients (74.1%; 95% CI, 61-84%). Malignancy accounted for 33 of 40

patients (82.5%) in whom a diagnosis was obtained; nonmalignant processes accounted for 7 of 40 cases (17.5%). One-year follow up was not available in one patient, whose results were categorized as not diagnostic. The diagnostic yield for peripheral lesions with a concentric view was 80.6% (25/31 lesions; 95% CI, 63.3-91.2%) compared with 70% (14/20 lesions; 95% CI, 47.9-85.7%; $P = .502$) for eccentric lesions (Tables 3 and 4).

Crossover procedures after nondefinitive ROSE cases were performed in five patients, of whom one was diagnostic with the use of thin bronchoscopy and R-EBUS with TBNA. In an additional crossover case, the final cytologic report from the robotic procedure was positive (initial ROSE was not definitive), although the crossover procedure was not diagnostic. In the remaining three cases, both robotic bronchoscopy and crossover procedures were not diagnostic.

Discussion

The American College of Chest Physicians clinical practice guidelines currently recommend guided bronchoscopy for the diagnosis of peripheral pulmonary lesions when lung cancer is suspected.¹¹ Despite experience with a myriad of bronchoscopic approaches over the past 10 years, the diagnosis of peripheral nodules continues to present a significant challenge to clinicians. Although earlier data reported diagnostic yields of approximately 70% for guided bronchoscopic approaches, more recent results from randomized controlled trials with clearly defined end points have been inconsistent, which suggests that the diagnostic yield may be closer to 40% to 60% and is even lower when peripheral nodules are adjacent to the bronchus.^{2-4,12,13}

This represents the first prospective, multicenter trial of robotic bronchoscopy in patients with peripheral pulmonary lesions. Robotic bronchoscopic approaches remain in early phases of exploration, and this study contributes to understanding the technology in the following ways. First, the primary effectiveness end point was designed to assess the ability to navigate successfully to peripheral lesions, confirmed in real-time with the use of R-EBUS imaging. The ability to use the robotic system to locate and confirm lesion localization in 96.2% of patients suggests that the current system successfully positions bronchoscopists within close proximity to targeted lesions, which is a critical step prior to performing biopsies. Second, the observed adverse event rate of procedures was low, even among novice operators

TABLE 2] Procedure Characteristics

Characteristic	Value
Procedure	
Procedure time, min	51 (44-64)
Time to radial endobronchial ultrasound confirmation, min	13 (10-24)
Bronchoscopy	
Insertion depth by bronchus generation count	5.5 (5-7)
Distance from scope tip to center of lesion, mm	23 (14-32)

Values represent median (interquartile range).

who previously had not used the new technology outside of cadaver models.^{6,7} This may be of significance in that, unlike conventional bronchoscopy, robotic systems do not provide the operator with haptic feedback. Although prior cadaver studies had assessed the ability to navigate peripheral airways, safety data could not be evaluated readily. In this study, there was no evidence of airway trauma during robotic bronchoscopy, and the pneumothorax rate was similar to what has been reported when current guided bronchoscopic techniques were used.¹⁴ Also, despite additional steps required to prepare the robotic system, procedure times were comparable with early experiences with the use of navigational systems.¹⁵ Third, despite the limitations of evaluating efficacy in a pilot study, we feel that the diagnostic yield of 74% achieved in this study with new technology compares favorably with recent publications of established technologies that have largely shown lower diagnostic yields when similarly strict definitions were applied in randomized controlled studies. Although Oki et al¹⁶ reported a diagnostic yield of 70% using ultrathin bronchoscopy, virtual bronchoscopic navigation, and radial ultrasound imaging for pulmonary nodules, a prospective, randomized controlled trial that compared thin bronchoscopy with R-EBUS to conventional transbronchial biopsy with fluoroscopy demonstrated a diagnostic yield of 49% for guided bronchoscopy, which was not statistically different from the yield of conventional bronchoscopy.² An additional large prospective observational study that used similar definitions reported a diagnostic yield of 57% among patients who were undergoing various guided bronchoscopic techniques.¹⁷ Although there are significant limitations in comparing this study with randomized controlled trials, the reported yield in this study is encouraging for new technology and will require further exploration through larger investigations.

An additional observation was that the performance characteristics of robotic bronchoscopy did not appear to be affected by lesion orientation relative to the bronchus. The diagnostic yield of 70% for eccentric lesions is encouraging because this compares favorably to the yields of 30% to 40% reported in the literature in this patient population.¹⁸ Improvement in diagnostic yield for eccentric lesions has clinical significance, because eccentric lesions were documented in nearly 40% of patients in this study and in as many as 50% of patients in prior publications.¹⁹

The limitations of this study would be related primarily to the relatively small sample size. As a pilot and feasibility study, the specific aims were to investigate the feasibility of the use of the robotic system in humans safely and the ability to navigate the robotic endoscope to the targeted lesion. This study was designed with the use of the hypothesis that a diagnostic biopsy is a composite of successful navigation to the targeted lesion followed by successful biopsy of the targeted lesion. Without successful navigation and lesion localization, it would seem less likely that diagnostic biopsy specimens would be obtained. An additional limitation of this study would be the proposed clinical significance of successful lesion localization as it relates to impact on diagnostic yield. In this study, lesion localization was 96.2%, and the diagnostic yield was 74%; additional studies will investigate whether factors such as increased user experience, biopsy tools, or other factors may influence

TABLE 3] Results

Result	No./No. (%)	P Value
Lesion localization^a		
Overall	51/53 (96.2)	
Concentric	31/51 (60.8)	
Eccentric	20/51 (39.2)	
Diagnostic yield		
Overall radial endobronchial ultrasound view	40/54 (74.1)	
Concentric	25/31 (80.6)	.502
Eccentric	14/20 (70.0)	
Bronchus sign		
Present	24/32 (75.0)	>.999
Absent	16/22 (72.7)	
Lesion size, mm		
≤30	30/42 (71.4)	.710
>31	10/12 (83.3)	

^aRadial endobronchial ultrasound probe unavailable for one case.

TABLE 4] Diagnostic Cases by Disease

Disease	No. (%) ^a
Malignant	33 (61.1)
Non-small cell carcinoma	27 (50)
Small cell carcinoma	2 (3.7)
Other ^b	3 (5.6)
Not malignant	7 (13)
Inflammation	4 (7.4)
Pneumonia ^c	2 (3.7)
Granuloma	1 (1.9)

^aValues based on 54 total patients.

^bTwo neuroendocrine tumors; one lymphoma.

^cBased on pathology data, concomitant culture data, and resolution on follow-up imaging.

the discordance between lesion localization and diagnostic yield. Last, recent data suggest that false-positive R-EBUS images may be produced by focal atelectasis during bronchoscopy procedures and that the likelihood of atelectasis may increase with procedure duration.²⁰ Although this is an emerging area of interest, we maintain that R-EBUS imaging characteristics such as well-defined borders surrounding the targeted lesion and a R-EBUS imaging lesion diameter that corresponds with measurements by chest CT scanning minimizes the risk of false-positive image characterization.

Additionally, robotic bronchoscopy was performed routinely prior to convex EBUS staging of the mediastinum to further minimize the likelihood of the development of intraprocedural atelectasis.

Some strengths of this study that may improve generalizability of results include the multicentered nature of the study and prospectively designed protocol towards performing procedures that allowed us to evaluate specific aspects of robotic technology at multiple sites using a standardized approach. Also, although diagnostic yield was not a primary end point, we feel that the methods used to define diagnostic

specimens are an additional strength of the study and may be helpful with future investigations that are powered and designed to assess diagnostic yield and sensitivity of robotic platforms. Diagnostic criteria were designed to protect against any potential ambiguity or operator bias and required cytopathologic evidence that the targeted lesion had been biopsied successfully. In cases of malignancy, this was reported as a specific diagnosis of cancer. Specimens labeled “atypical” were considered not diagnostic. Nonmalignant cases required either a specific diagnosis such as “granuloma” or cytopathologic evidence of a process such as “inflammation” that demonstrated documented radiographic improvement within the 1-year follow up. Cases that demonstrated normal pulmonary elements on cytopathology with radiographic improvement on follow-up imaging were considered not diagnostic because there was no evidence that the targeted lesion had been sampled adequately.

In conclusion, the results of this study demonstrate the feasibility and safety of performing robotic bronchoscopy in patients with peripheral pulmonary lesions with the use of a prospectively designed, multicenter approach, with strict definitions of diagnostic and nondiagnostic biopsy specimens. Confirmation of lesion localization occurred in 96% of patients, with an observed adverse event rate comparable with conventional bronchoscopy. We believe that demonstrating safety and the ability to locate peripheral lesions is an integral first step in the evolution of this technology. Because of variability in the reported diagnostic yield of current guided bronchoscopic approaches, we propose that, to perform an appropriate assessment of robotic technology, additional studies that will address diagnostic yield and factors that influence this be performed in significantly larger, prospective comparative effectiveness trials with clearly defined end points.

Acknowledgments

Author contributions: A. C. C. and G. A. S. are the guarantors of the content of the manuscript, including the data and analysis. A. C. C., N. J. P., A. K. M., S. J. K., M. J. S., M. S. M., J. C., T. R. G., and G. A. S. each made substantial contributions to the conception or design of the work, the acquisition, analysis, or interpretation of data for the work, drafted and assisted in critical revisions to the work for important intellectual content, provided final approval of the version to be published, and are in agreement to be accountable for all aspects of the work in ensuring that questions related to the accuracy or integrity of any part of the work are appropriately investigated and resolved.

Financial/nonfinancial disclosures: The authors have reported to *CHEST* the following: A. C. C., N. J. P., A. K. M., S. J. K., M. J. S., M. S. M., J. C., and T. R. G. have received consulting fees and research support from Auris Health. G. A. S. has received research support from Auris Health

References

1. Gould MK, Tang T, Liu IL, et al. Recent trends in the identification of incidental pulmonary nodules. *Am J Respir Crit Care Med*. 2015;192(10):1208-1214.
2. Tanner NT, Yarmus L, Chen A, et al. Standard bronchoscopy with fluoroscopy vs thin bronchoscopy and radial endobronchial ultrasound for biopsy of pulmonary lesions: a multicenter, prospective, randomized trial. *Chest*. 2018;154(5):1035-1043.
3. Oki M, Saka H, Ando M, et al. Ultrathin bronchoscopy with multimodal devices for peripheral pulmonary lesions: a randomized trial. *Am J Respir Crit Care Med*. 2015;192(4):468-476.
4. Eberhardt R, Anantham D, Ernst A, et al. Multimodality bronchoscopic diagnosis of peripheral lung lesions: a randomized controlled trial. *Am J Respir Crit Care Med*. 2007;176(1):36-41.
5. Veronesi G. Robotic lobectomy and segmentectomy for lung cancer: results and operating technique. *J Thorac Dis*. 2015;7(suppl 2):S122-S130.
6. Chen AC, Gillespie CT. Robotic endoscopic airway challenge: REACH assessment. *Ann Thorac Surg*. 2018;106(1):293-297.
7. Chen AC, Pastis NJ, Machuzak MS, et al. Accuracy of a robotic endoscopic system in cadaver models with simulated tumor targets: ACCESS study. *Respiration*. 2020;99(1):56-61.
8. Yarmus L, Akulian J, Wahidi M, et al. A prospective randomized comparative study of three guided bronchoscopic approaches investigating pulmonary nodules: the PRECISION-1 study. *Chest*. 2020;157:694-701.
9. Rojas-Solano JR, Ugalde-Gamboa L, Machuzak M. Robotic bronchoscopy for diagnosis of suspected lung cancer: a feasibility study. *J Bronchol Interv Pulmonol*. 2018;25(3):168-175.
10. Chaddha U, Kovac SP, Manley C, et al. Robot-assisted bronchoscopy for pulmonary lesion diagnosis: results from the initial multicenter experience. *BMC Pulm Med*. 2019;19(1):243.
11. Rivera MP, Mehta AC, Wahidi MM. Establishing the diagnosis of lung cancer: Diagnosis and management of lung cancer, 3rd ed: American College of Chest Physicians evidence-based clinical practice guidelines. *Chest*. 2013;143(suppl 5):e142S-e165S.
12. Wang Memoli JS, Nietert PJ, Silvestri GA. Meta-analysis of guided bronchoscopy for the evaluation of the pulmonary nodule. *Chest*. 2012;142(2):385-393.
13. Chen AC, Chenna P, Loisel A, Massoni J, Mayse M, Misselhorn D. Radial probe endobronchial ultrasound for peripheral pulmonary lesions: a 5 year institutional experience. *Ann Am Thorac Soc*. 2014;11(4):578-582.
14. Eberhardt R, Anantham D, Ernst A, Feller-Kopman D, Herth F. Multimodality bronchoscopic diagnosis of peripheral lung lesions: a randomized controlled trial. *Am J Respir Crit Care Med*. 2007;176(1):36-41.
15. Gildea TR, Mazzone PJ, Karnak D, et al. Electromagnetic navigation diagnostic bronchoscopy: a prospective study. *Am J Respir Crit Care Med*. 2006;174(9):982-989.
16. Oki M, Saka H, Asano F, et al. Use of an ultrathin vs thin bronchoscope for peripheral pulmonary lesions: a randomized trial. *Chest*. 2019;156(5):954-964.
17. Silvestri GA, Bevil BT, Huang J, et al. An evaluation of diagnostic yield from bronchoscopy: the impact of clinical/radiographic factors, procedure type and degree of suspicion for cancer. *Chest*. 2020;157(6):1656-1664.
18. Yamada N, Yamazaki K, Kurimoto N, et al. Factors related to diagnostic yield of transbronchial biopsy using endobronchial ultrasonography with a guide sheath in small peripheral pulmonary lesions. *Chest*. 2007;132(2):603-608.
19. Chen AC, Loiseau A, Zhou L, Baty J, Misselhorn D. Localization of peripheral pulmonary lesions using a method of CT-anatomic correlation and radial probe endobronchial ultrasound confirmation. *Ann Am Thorac Soc*. 2016;13(9):1586-1592.
20. Casal RF, Sarkiss M, Jones AK, et al. Cone beam computed tomography-guided thin/ultrathin bronchoscopy for diagnosis of peripheral lung nodules: a prospective study. *J Thorac Dis*. 2018;10(12):6950-6959.