

Washington University School of Medicine

Digital Commons@Becker

Open Access Publications

8-7-2012

Antegrade endoscopic removal of retained urethral sling mesh in the bladder

Michael H. Johnson

Washington University School of Medicine in St. Louis

Genoa G. Ferguson

Washington University School of Medicine in St. Louis

Carl G. Klutke

Washington University School of Medicine in St. Louis

Follow this and additional works at: https://digitalcommons.wustl.edu/open_access_pubs

Please let us know how this document benefits you.

Recommended Citation

Johnson, Michael H.; Ferguson, Genoa G.; and Klutke, Carl G., "Antegrade endoscopic removal of retained urethral sling mesh in the bladder." *Journal of Endourology*. 26, 8. 980-982. (2012).

https://digitalcommons.wustl.edu/open_access_pubs/2731

This Open Access Publication is brought to you for free and open access by Digital Commons@Becker. It has been accepted for inclusion in Open Access Publications by an authorized administrator of Digital Commons@Becker. For more information, please contact vanam@wustl.edu.

Antegrade Endoscopic Removal of Retained Urethral Sling Mesh in the Bladder

Michael H. Johnson, M.D., Genoa G. Ferguson, M.D., and Carl G. Klutke, M.D.

Abstract

The midurethral sling has emerged as an effective, minimally invasive treatment for patients with stress urinary incontinence. Bladder penetration is a known complication that, if unrecognized, may result in retained intravesical mesh. This rare complication can cause patient discomfort as well as become a nidus for infection and bladder calculi. Because of the technique of sling passage, the site of retained sling material is often along the anterior bladder wall, making evaluation and treatment via traditional retrograde cystoscopy prohibitively difficult. We describe a novel and minimally invasive method to remove the sling material using antegrade access into the bladder in conjunction with holmium laser vaporization. In our series of six patients in whom retrograde cystoscopic treatment had failed, all were successfully treated with antegrade cystoscopy and reported improved urinary symptoms. This new technique provides a simple, minimally invasive, and effective method for removal of exposed sling mesh.

Introduction

STRESS URINARY INCONTINENCE, defined as uncontrollable leakage of urine with physical exertion, affects up to 25% of women in the United States with an estimated cost of \$12 billion in direct and indirect costs.^{1–3} Since the introduction of the tension-free vaginal tape in 1996, midurethral mesh slings have become the first-line treatment for stress urinary incontinence in women.^{4,5} Bladder penetration is a known complication, affecting 1.7% to 13.6% of patients.⁶ When recognized, treatment involves repositioning of the needle used to place the mesh sling. Unfortunately, unrecognized bladder penetration will result in exposed intravesical mesh, which can cause pelvic pain, dysuria, urinary urgency/frequency, as well as serve as a nidus for infection and stones.

Removal of intravesical foreign bodies is typically performed with retrograde cystoscopy. Likely locations for bladder penetration during midurethral sling placement are the 11 and 1 o'clock positions along the anterior bladder wall. This location can make retrograde cystoscopic treatment prohibitively difficult. Often, a 70-degree lens is needed to visualize the injury, but a 0- or 30-degree lens is needed to use endoscopic instruments. To this end, we developed an antegrade approach to visualize and manage exposed sling mesh.

Technique

Adequate general sedation is administered. The patient is placed in the dorsal lithotomy position with a moderate Trendelenberg position. Retrograde cystoscopy using a 30

degree lens ensures proper cystostomy placement. An 18-gauge spinal needle is placed percutaneously 3 cm superior to the symphysis pubis. Placement should be in the midline near the dome of the bladder, being mindful that a vesicular puncture near the exposed mesh will result in difficulty accessing the desired site. Once placed, an Amplatz super stiff 0.035-inch guidewire is placed through the needle, while visualizing the wire cystoscopically. The abdominal fascia is incised in a cruciform pattern using a fascial incising needle (Cook Medical) over the guidewire. Amplatz renal dilators are used to dilate the tract to accommodate a 24F sheath.

Once the bladder is accessed, the cystoscope with a 30-degree lens is used to inspect the bladder, identifying both ureteral orifices and the site of eroded mesh (Fig. 1). Visualizing the anterior bladder wall involves rotating the cystoscope 180 degrees. A urethral catheter can be placed, depending on the need for continuous irrigation during the procedure. Encrustations on the mesh are removed using holmium:yttrium-aluminum-garnet (Ho:YAG) laser lithotripsy with a 1000 micron fiber, 0.6 to 0.8 joules of energy, and a pulse rate of 6 to 8 Hz. Once the mesh is exposed, endoscopic scissors are used to cut out the majority of visible mesh (Fig. 2). The Ho:YAG laser is again used to treat any remaining mesh using the aforementioned settings and ensuring good contact between laser fiber and mesh. Bugbee electrocautery at 60 W is used over the erosion site to allow for reepithelialization. The antegrade access sheath is then removed and the insertion site dressed. The urethral catheter is

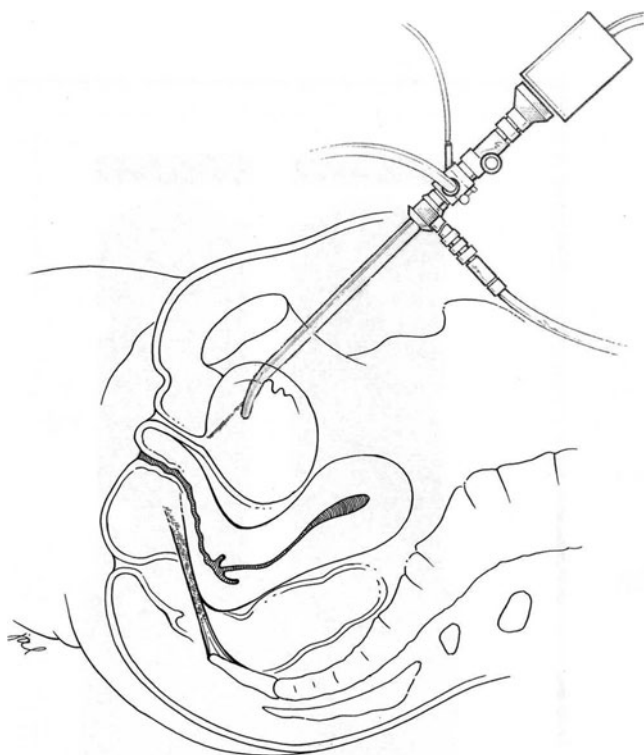


FIG. 1. Schematic of antegrade cystoscopy.

removed, if placed. The patient is then discharged home the same day, with oral antibiotics, anticholinergics, and analgesics.

Equipment

Obtaining antegrade access

- 23F rigid cystoscope
- 0.035" Amplatz super stiff guidewire
- Amplatz renal dilators
- Fascial incising needle
- 16F Foley urethral catheter

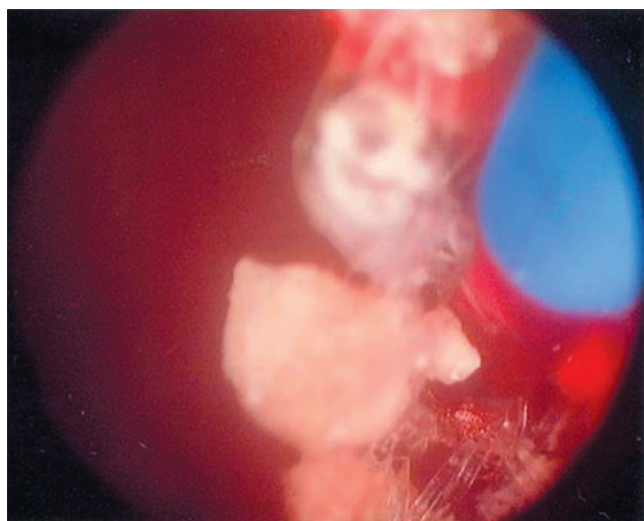


FIG. 2. Intraoperative mesh removal.

Excising exposed mesh

- Holmium:YAG laser with 1000 micron fiber
- Endoscopic scissors
- Endoscopic graspers
- Bugbee electrocautery

Role in Endourology

We identified six women from 2009 to 2011 with exposed intravesical midurethral sling mesh. The mean age of the patients was 53.7 years (range 38.0–66.7 y). All presented with pelvic pain and had been treated unsuccessfully using retrograde cystoscopy. Office cystoscopy verified the presence of mesh, which was located in the 11 and 1 o'clock positions along the anterior bladder wall. Using the antegrade approach, four of six (67%) patients were able to have complete removal of all mesh in one procedure, confirmed by flexible cystoscopy on postoperative visit. Two (33%) patients needed a second antegrade procedure. No patients needed more than two procedures. There were no intraoperative or postoperative complications.

Mean follow-up was 8.0 months (range 1.3–22.9 mos). Three of six (50%) patients stated that their urination was "better" compared with before surgery, while the other three of six (50%) patients stated they were "much better" after the procedure. Five of six (83%) patients reported that pain and lower urinary tract symptoms (LUTS) resolved. One of six (17%) patients reported that pain resolved but LUTS were unchanged.

Discussion

Synthetic mesh slings are widely used for stress urinary incontinence. Rates of exposed mesh range from 0% to 2% using these techniques and can be attributed to surgical approach and surgeon experience.^{7–9} Unfortunately, when unrecognized injury occurs, exposed intravesical sling mesh can cause bladder calculi and significant urinary symptoms.

Multiple endoscopic approaches have been reported. Compared with open intra-abdominal or transvaginal techniques, endoscopic approaches offer decreased blood loss, infection risk, and postoperative pain. Endoscopic approaches commonly use retrograde cystoscopic removal of the intravesical mesh and adherent calculi.^{10,11} Because of the mesh location, however, the affected area is often poorly visualized and subsequently inadequately treated. Alternate methods have been described using suprapubically placed laparoscopic instruments.^{12–15} Pure laparoscopic techniques necessitate multiple trocars penetrating the bladder. Combined laparoscopic/cystoscopic approaches use retrograde cystoscopy, which still provides suboptimal visualization. Both of these approaches do not take advantage of the full armamentarium of cystoscopic tools.

The antegrade cystoscopic approach we describe has advantages over the classic retrograde and laparoscopy-assisted approaches. The technique has been described and successfully applied to procedures at the bladder neck.¹⁶ The instrumentation is well known and does not necessitate familiarity with laparoscopic techniques. The angle of the cystoscope allows for direct and straightforward visualization of the eroded mesh along the anterior bladder wall. Accidental ureteral orifice injury is minimized, because these can

be seen easily through a suprapubic approach. Finally, continuous bladder irrigation through a urethral catheter maintains visualization that is unimpaired by intraoperative bleeding.

Despite its advantages, the antegrade approach has theoretical drawbacks. Placement of a suprapubic access tract carries risk for bowel injury. This is minimized by cystoscopic visualization during placement, but this approach should be cautioned in patients with previous abdominal surgeries or small capacity bladders. In this situation, suprapubic cystostomy via ultrasonographic guidance or Lowsley retractor should be considered.¹⁷ Patients with bleeding disorders or who need therapeutic anticoagulation are likewise suboptimal candidates for suprapubic cystostomy.

Conclusion

Patients with exposed intravesical mesh at or near the bladder neck should be strongly considered for antegrade cystoscopic removal. The procedure is well tolerated and safe. Further studies with larger patient populations and longer follow-up are needed to further investigate and develop this novel and effective procedure.

Disclosure Statement

No competing financial interests exist.

References

- Nygaard IE, Heit M. Stress urinary incontinence. *Obstet Gynecol* 2004;104:607–620.
- Fultz NH, Burgio K, Diokno AC, et al. Burden of stress urinary incontinence for community-dwelling women. *Am J Obstet Gynecol* 2003;189:1275–1282.
- Chong EC, Khan AA, Anger JT. The financial burden of stress urinary incontinence among women in the United States. *Curr Urol Rep* 2011;12:358–362.
- Ulmsten U, Henriksson L, Johnson P, Varhos G. An ambulatory surgical procedure under local anesthesia for treatment of female urinary incontinence. *Int Urogynecol J Pelvic Floor Dysfunct* 1996;7:81–86.
- Fritel X, Fauconnier A, Bader G, et al. Diagnosis and management of adult female stress urinary incontinence: Guidelines for clinical practice from the French College of Gynaecologists and Obstetricians. *Eur J Obstet Gynecol Reprod Biol* 2010;151:14–19.
- Ogah J, Cody JD, Rogerson L. Minimally invasive synthetic suburethral sling operations for stress urinary incontinence in women. *Cochrane Database Syst Rev* 2009;CD006375.
- Stav K, Dwyer PL, Rosamilia A, et al. Risk factors for trocar injury to the bladder during mid urethral sling procedures. *J Urol* 2009;182:174–179.
- McLennan MT, Melick CF. Bladder perforation during tension-free vaginal tape procedures: Analysis of learning curve and risk factors. *Obstet Gynecol* 2005;106:1000–1004.
- Daneshgari F, Kong W, Swartz M. Complications of mid urethral slings: Important outcomes for future clinical trials. *J Urol* 2008;180:1890–1897.
- Oh TH, Ryu DS. Transurethral resection of intravesical mesh after midurethral sling procedures. *J. Endourol* 2009;23:1333–1337.
- Mustafa M, Wadie BS. Bladder erosion of tension-free vaginal tape presented as vesical stone; management and review of literature. *Int Urol Nephrol* 2007;39:453–455.
- Chang PL, Sokol ER. Alternative method of suprapubic assistance in operative cystoscopy. *Int Urogynecol J* 2010;21:247–249.
- Yoshizawa T, Yamaguchi K, Obinata D, et al. Laparoscopic transvesical removal of erosive mesh after transobturator tape procedure. *Int J Urol* 2011;18:861–863.
- Ingber MS, Stein RJ, Rackley RR, et al. Single-port transvesical excision of foreign body in the bladder. *Urology* 2009;74:1347–1350.
- Rosenblatt P, Pulliam S, Edwards R, Boyles SH. Suprapubically assisted operative cystoscopy in the management of intravesical TVT synthetic mesh segments. *Int Urogynecol J Pelvic Floor Dysfunct* 2005;16:509–511.
- Klutke CG, Tiemann DD, Nadler RB, Andriole GL. Antegrade collagen injection for stress incontinence after radical prostatectomy: Technique and early results. *J Endourol* 1996;10:279–282.
- Zeidman EJ, Chiang H, Alacon A, Raz S. Suprapubic cystostomy using Lowsley retractor. *Urology* 1988;32:54–55.

Address correspondence to:

Carl Klutke, M.D.

Division of Urologic Surgery

Washington University School of Medicine

1040 North Mason, Suite 122

St. Louis, MO 63141

E-mail: klutkec@wustl.edu

Abbreviations Used

Ho: YAG = holmium:yttrium-aluminum-garnet
LUTS = lower urinary tract symptoms