

2005

Comparison of a novel endoscope holder and traditional camera assistant for laparoscopic simple nephrectomy in a porcine model

Sejal S. Quayle

Washington University School of Medicine in St. Louis

W. Collyer

Washington University School of Medicine in St. Louis

R. Vanlangedonck

Washington University School of Medicine in St. Louis

Jaime Landman

Washington University School of Medicine in St. Louis

Follow this and additional works at: https://digitalcommons.wustl.edu/open_access_pubs

Recommended Citation

Quayle, Sejal S.; Collyer, W.; Vanlangedonck, R.; and Landman, Jaime, "Comparison of a novel endoscope holder and traditional camera assistant for laparoscopic simple nephrectomy in a porcine model." *Journal of Endourology*.19,2. 218-220. (2005).
https://digitalcommons.wustl.edu/open_access_pubs/3118

This Open Access Publication is brought to you for free and open access by Digital Commons@Becker. It has been accepted for inclusion in Open Access Publications by an authorized administrator of Digital Commons@Becker. For more information, please contact engeszer@wustl.edu.

Comparison of a Novel Endoscope Holder and Traditional Camera Assistant for Laparoscopic Simple Nephrectomy in a Porcine Model

SEJAL S. QUAYLE, M.D., W. COLLYER, M.D., R. VANLANGENDONCK, M.D.,
and JAIME LANDMAN, M.D.

ABSTRACT

Purpose: To establish the feasibility of single-surgeon laparoscopy with application of a novel endoscope-holder device and to compare this technique with traditional assistant-driven laparoscopic camera control.

Materials and Methods: Bilateral simple nephrectomies were performed in six pigs. On one side, the operating surgeon employed the “scope holder” and performed the surgery without a laparoscopic assistant. On the contralateral side, an experienced camera operator was responsible for control of the laparoscopic field of vision in the traditional manner. The time required for hilar ligation and complete renal mobilization was documented. Pigs were sacrificed immediately after the procedure.

Results: The mean operative times for scope-holder and camera person-assisted nephrectomy were 20.7 minutes and 19.3 minutes, respectively. The time to hilar ligation in the scope-holder and camera-operator-assisted cohorts was 13 and 14.5 minutes, respectively. There were no significant differences in operative times or blood loss in the two groups. The operative surgeon perceived some increase in shoulder and neck pain with use of the scope holder.

Conclusions: This novel device provides a means for the operative surgeon to safely perform a laparoscopic nephrectomy alone without significantly increasing operative time or morbidity.

INTRODUCTION

IN 1901, KELLING¹ INTRODUCED a cystoscope into the abdomen of a living dog through a trocar, presaging the concept of laparoscopy.¹ It was nearly a century later when Clayman and associates² published their report of the first laparoscopic nephrectomy, before the techniques of laparoscopic surgery had been applied to complex ablative procedures in the field of urology.

The advantages of laparoscopic surgery for the patient have been well documented.³⁻⁶ However, there are some distant disadvantages to laparoscopic surgery: equipment costs are high, and performance requires an experienced camera operator who can provide appropriate views for the operating surgeon. It can be difficult for the camera operator, who is frequently less experienced than the surgeon, to anticipate the surgeon's desired

field of vision. Additionally, procedures that involve application of a flank position such as the nephrectomy or adrenalectomy necessitate positioning of the camera directly in front of the surgeon. This can cause the surgeon or the assistant to operate in an uncomfortable position for extended periods of time.

In this study, we compared traditional laparoscopy with an experienced assistant with laparoscopy using a novel endoscope holder in a porcine model.

MATERIALS AND METHODS

Endoscope holder

The holder has two components: a metal chest plate with stabilizing abdomen and chest straps that secure it to the body of the surgeon (Fig. 1A) and an adjustable movable arm (Fig. 1B).

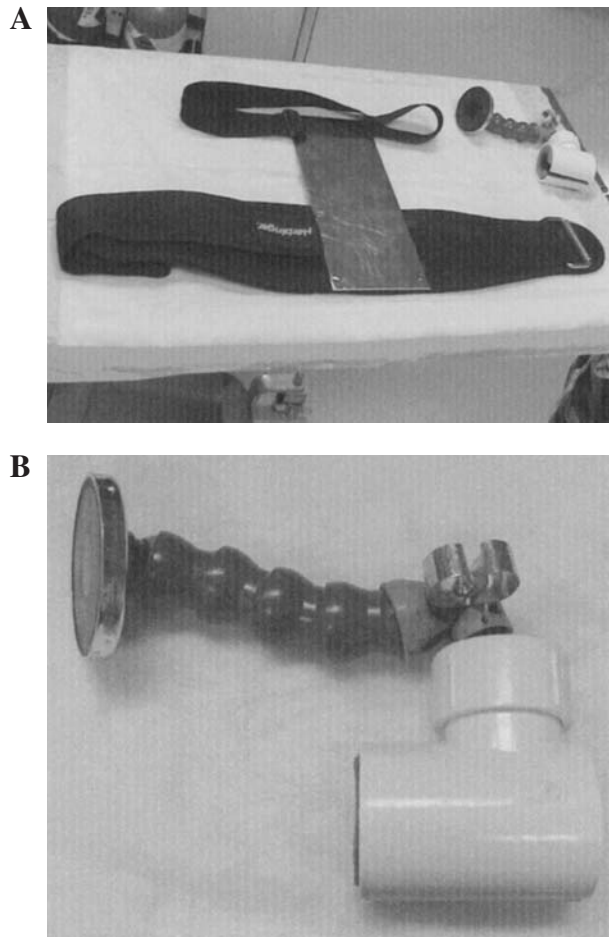


FIG. 1. Endoscope holder. (A) Metal plate component, which is worn beneath surgeon's gown. (B) Movable arm, which holds laparoscope and attaches magnetically to metal chest plate.

The chest plate is worn under the surgeon's gown. The movable arm, which can be sterilized, is affixed to the metal plate via a magnet. This arm can be moved anywhere on the metal plate to provide optimal camera position and maximum comfort for the surgeon. The "scope holder" weighs <1 pound.

The laparoscopic camera inserts into a padded sheath suspended from the device arm by a modified ball and socket joint. A clip on the arm stabilizes the laparoscope but allows full rotation of the lens. A 30° laparoscope can be rotated to the left or right by the surgeon to optimize viewing. Postural motion by the surgeon is also involved. The surgeon can either rotate his or her body to the right or step to the right to look left. To look to the right, the surgeon can either rotate his or her body to the left or step to the left. To look up, the surgeon can either lean forward slightly or step back slightly. To look down, the surgeon can either lean back slightly or step forward slightly. Bending the device arm down or sliding the entire arm down on the metal plate allows the surgeon to adjust the field of vision upward with minimal body movement. Similarly, bending the arm upward or sliding the entire arm upward on the metal plate shifts the field of vision downward (Fig. 2).

Methods

Permission for the study was gained from the Washington University Animal Studies Committee. After animals had fasted for 16 hours, a preanesthetic mixture of ketamine (20 mg/kg) and xylazine (2 mg/kg) was given intramuscularly. Atropine sulfate (0.01 mg/kg) and ceftriaxone sodium (3–5 mg/kg) were also administered intramuscularly. The trachea was intubated and mechanical ventilation performed throughout the procedure with the animal under 1% to 5% isoflurane anesthesia. Hydration was maintained with normal saline at 1 mL/kg of body weight per hour through a 20- to 22-gauge intravenous line.

Bilateral simple nephrectomies were performed in six pigs by a single surgeon (SSQ). The pig was initially placed in a left lateral decubitus position; and after completion of a simple nephrectomy, the trocar sites were closed, and the pig was moved to the right lateral decubitus position. An equal number of right and left nephrectomies were performed in each group. In each pig, the surgeon performed one nephrectomy with the scope holder and the contralateral side with the aid of an experienced camera operator (a laparoscopic surgery fellow). A 30° laparoscope was used for the surgery. A bipolar grasper (Aesculap, Melsungen, Germany) and ultrasonic shears (Ethicon Endosurgery, Cincinnati, OH) were employed for renal-vessel isolation and complete renal mobilization for each nephrectomy. The surgeon ligated the renal vein and

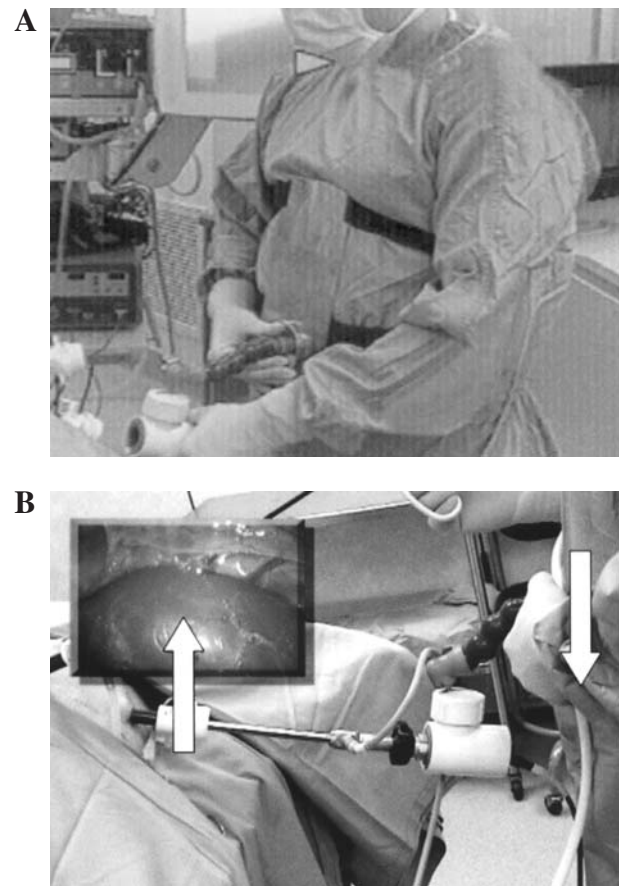


FIG. 2. Endoscope holder in use. (A) Surgeon wearing device. (B) With laparoscope in place.

artery with titanium clips in each case and divided the vessels with endoscopic scissors. The times to hilar ligation and to completion of the procedure were recorded for each case. The surgeon also noted the extent of muscle fatigue and overall body comfort in each case. Statistical analysis was performed by Student's *t*-test.

RESULTS

All 12 porcine nephrectomies were completed laparoscopically, six with an assistant and six with the scope holder. In all cases, the right-side nephrectomy was performed first, and we alternated use of the scope holder with the use of an assistant. The mean operative time for the scope-holder nephrectomy was 20.7 ± 4.9 minutes (SD), and the mean operative time for the camera person-assisted nephrectomy was 19.3 ± 3.1 minutes. The mean time to hilar ligation was 14.5 ± 5.2 minutes in the scope-holder group and $13 + 3$ minutes in the camera-operator group. Use of the standard *t*-test demonstrated no statistically significant differences in time to hilar ligation ($P = 0.55$) or total operative time ($P = 0.56$) in the two groups. The estimated blood loss was minimal with both procedures. A small renal-vein laceration occurred during one nephrectomy in the scope-holder group. However, hemostasis was easily achieved without an assistant, and the technical error was not attributed to poor visibility or discomfort from the scope-holder device.

The surgeon also documented muscle fatigue during scope-holder use. Primarily, there was mild fatigue in the sternocleidomastoid and trapezius muscle groups. No arm, back, hip, or leg discomfort was noted.

DISCUSSION

The scope holder is a novel instrument that allows the surgeon to function independently during laparoscopy. Several distinct advantages of the device can be appreciated: the potential reduction in cost without an assistant, the direct control of visual field by the operating surgeon, and the intuitive positioning of the camera in front of the surgeon.

Initially, the surgeon required some time to become comfortable using the scope holder, as evidenced by the gradual improvement in total operative time. As in traditional laparoscopy,⁷ the use of a pelvic trainer to practice use of the scope holder is likely to be helpful. In this study, the operating surgeon required only 2 hours of training on a laparoscopic trainer with the scope holder to become comfortable with the postural changes that elicited endoscope movement before performing the porcine nephrectomies. Application of the scope holder is intuitive and, as such, requires little training prior to application.

Although this study provided a direct comparison of the scope-holder technique and the traditional laparoscopic technique, it did have some limitations. The device was evaluated in a porcine model. Although the genitourinary anatomy is sim-

ilar to that of humans, differences in anatomy, including the shorter abdominal cavity and narrow torso, may have facilitated scope-holder use. However, we have begun preliminary human clinical application of the scope-holder device, and, to date, it has been applied to a transperitoneal laparoscopic adrenalectomy that was performed without difficulty or complication.

This study provides a positive initial experience with application of the scope-holder device. Comparison with traditional camera-operator control demonstrated no significant differences in blood loss or mean operative times. Although the surgeon did note some neck and shoulder discomfort, adjustments to the design of the device will improve surgeon comfort. Clinical application of the device is in progress.

CONCLUSION

The scope holder allows the surgeon to intuitively control the field of laparoscopic vision while coordinating the movement of his/her instruments. This device may also ease learning laparoscopy by allowing the surgeon to operate in a more comfortable and intuitive manner. Clinical application and evaluation are in progress.

REFERENCES

1. Kelling G. Die Tamponade der Bauchhöhle mit Luft zur Stillung lebensgefährlicher Intestinalablutungen. *Munch Med Wochenschr* 1901;48:1535–1538.
2. Clayman RV, Kavoussi LR, Soper NJ, et al. Laparoscopic nephrectomy: Initial case report. *J Urol* 1991;146:278–282.
3. Gill IS, Fergany A, Klein EA. Laparoscopic radical cystoprostatectomy with ileal conduit performed completely intracorporeally—The initial 2 cases. *Urology* 2000;56:26–30.
4. Guillonnet B, Vallancien G. Laparoscopic radical prostatectomy: The Montsouris technique. *J Urol* 2000;163:1643–1649.
5. Ehrlich RM, Gershman A, Fuchs G. Laparoscopic ureteral reimplantation for vesicoureteral reflux: Initial case reports. *J Endourol* 1993;7:171.
6. Cosson M, Rajabally R, Bogaert E, Querleu D, Crepin G. Laparoscopic sacrocolpopexy, hysterectomy and burch colposuspension: Feasibility and short-term complications of 77 procedures. *JSL* 2000;6:115–119.
7. Derossis AM, Bothwell J, Sigman HH, Fried GM. The effect of practice on performance in a laparoscopic simulator. *Surg Endosc* 1998; 12:1117–1120.

Address reprint requests to:

Jaime Landman, M.D.

Dept. of Urology

Washington University School of Medicine

4960 Children's Place

Campus Box 8242

St. Louis, MO

E-mail: landmanj@yahoo.com