

Washington University School of Medicine

Digital Commons@Becker

Open Access Publications

2003

The risk of a new retinal break or detachment following cataract surgery in eyes that had undergone repair of phakic break or detachment: A hypothesis of a causal relationship to cataract surgery

M. Gilbert Grand

Washington University School of Medicine in St. Louis

Follow this and additional works at: https://digitalcommons.wustl.edu/open_access_pubs

Please let us know how this document benefits you.

Recommended Citation

Grand, M. Gilbert, "The risk of a new retinal break or detachment following cataract surgery in eyes that had undergone repair of phakic break or detachment: A hypothesis of a causal relationship to cataract surgery." Transactions of the American Ophthalmological Society. 101, 329-364. (2003).
https://digitalcommons.wustl.edu/open_access_pubs/3308

This Open Access Publication is brought to you for free and open access by Digital Commons@Becker. It has been accepted for inclusion in Open Access Publications by an authorized administrator of Digital Commons@Becker. For more information, please contact vanam@wustl.edu.

THE RISK OF A NEW RETINAL BREAK OR DETACHMENT FOLLOWING CATARACT SURGERY IN EYES THAT HAD UNDERGONE REPAIR OF PHAKIC BREAK OR DETACHMENT: A HYPOTHESIS OF A CAUSAL RELATIONSHIP TO CATARACT SURGERY

BY M. Gilbert Grand MD

ABSTRACT

Purpose: To determine the risk of new retinal tear or detachment following cataract surgery in eyes that had undergone successful repair of phakic retinal tear or detachment.

Methods: A computerized search of records of patients evaluated at the Barnes Retina Institute from 1990 to 2000 for a diagnosis of phakic retinal tear or detachment was accomplished. The records of successfully treated patients were analyzed by type of tear or detachment, method of treatment, and development of sequential new tears or detachment. Eyes that subsequently underwent cataract surgery were classified by presence and location of intraocular lens as well as operative complications, including capsular rupture, vitreous loss, or retained lens fragments. The frequency of developing new tears or detachment was calculated.

Results: The 2,175 eyes identified were subdivided according to those that had undergone repair of retinal break ($n = 1,415$), subclinical retinal detachment ($n = 396$), or retinal detachment ($n = 364$). Of 371 eyes that underwent subsequent cataract surgery, 17 (4.6%) developed a new tear or detachment postoperatively. Factors indicative of higher postoperative risks included myopia, tear or detachment in the fellow eye, sequential onset of new breaks prior to cataract surgery, and complications of cataract surgery.

Conclusion: In patients who had undergone prior repair of retinal breaks or detachment, cataract surgery was associated with a 4.6% incidence of new breaks or detachment. Cataract surgery appears to be an independent risk factor for retinal tears or detachments. Dilated retinal examination following cataract surgery is advisable in patients who have previously undergone repair of a phakic retinal tear or detachment.

Trans Am Ophthalmol Soc 2003;101:329-364

HYPOTHESIS

It is widely recognized that the etiology of retinal detachment is multifactorial. A number of predisposing factors including age, refractive status, family history, prior trauma, and preexisting peripheral retinal pathology such as lattice degeneration, have been associated with an increased risk of retinal detachment. Of singular importance among the risk factors for detachment is aphakia/pseudophakia. Whereas the frequency of postoperative retinal detachment during the era of intracapsular surgery ranged as high as 3.6%, the current technique of extracapsular surgery with placement of a posterior chamber intraocular lens is associated with a much lower (0.9%) risk of retinal detachment. Yet despite these advances, the frequency of pseudophakic detachment

greatly exceeds the 1 in 10,000 (0.01%) risk of retinal detachment in the overall population.

A small number of reports have provided insight into the frequency of new retinal breaks or detachment following cataract surgery in eyes that have previously undergone phakic repair of retinal breaks or detachment. Regrettably, data from these reports, each containing a small number of eyes, are limited; and the calculated risk varies considerably among the studies. While these limited data are helpful in establishing that new breaks may occur, the small sample size has precluded more precise determination of the risk; and predisposing risk factors have not been clearly elucidated. Furthermore, these studies have not established whether a causal relationship to cataract surgery exists.

For eyes that remain phakic, the sequential onset of new breaks or detachment following initial successful repair of retinal breaks or detachment is a well-known phenomenon and occurs despite the method of repair utilized. The onset of these sequential breaks confounds

From the Washington University School of Medicine and Barnes Retina Institute, St Louis, Mo. This study was supported in part by the Retina Research and Development Foundation, St Louis.

the question of the etiology of new breaks or detachment following cataract surgery in eyes that have previously undergone successful repair of phakic breaks or detachment.

It is the goal of this study to evaluate a substantially larger number of eyes than previously reported, subdivided into those that underwent repair of phakic retinal breaks, phakic subclinical detachment, and phakic retinal detachment. It is anticipated that the data will allow calculation of the risk of new breaks or detachment following cataract surgery for each subgroup as well as for the entire study population and that it will allow identification of predisposing risk factors that may lead to the occurrence of new breaks or detachment. Furthermore, it is anticipated that the data will allow calculation of the risk of sequential onset of new breaks in previously treated eyes that remain phakic.

This study will examine the hypothesis that new tears or detachment occur at a higher than expected rate following cataract surgery in eyes that have undergone prior repair of retinal break or detachment compared to the historical rate of retinal breaks or detachment following cataract surgery in eyes without a history of prior phakic retinal repair as reported in the literature. Furthermore, it is hypothesized that the frequency and timing of onset of such breaks and detachments can be distinguished from the aforementioned sequential onset of new breaks in eyes that remain phakic, and that cataract surgery is in fact an independent risk factor for the development of new breaks or detachment.

INTRODUCTION

Recognition of retinal detachment, determination of its cause, and the development of surgical techniques for its repair have been among the most interesting challenges facing ophthalmologists for generations. As one examines the history of ophthalmology, it becomes apparent that our current approach to vitreoretinal pathology has emerged from the interdigitation of scientific theory and clinical experience with the sequential evolution of new diagnostic and surgical technology.

Observations of abnormalities of the red reflex predated the development of the ophthalmoscope.¹ However, it was shortly after the development of the Helmholtz ophthalmoscope that Coccia first observed a retinal break and made the association of retinal breaks with retinal detachment.² Thereafter numerous observations were made describing retinal breaks and detachment, and multiple theories regarding etiology of detachments were presented.

The development of technology for observation of the retina included modification of the original Helmholtz

ophthalmoscope, the development of a monocular indirect ophthalmoscope, and subsequent modifications that ultimately led to the electric binocular indirect ophthalmoscope.^{3,4} In a parallel fashion the technology for examining the anterior segment advanced during the same era and led to slit-lamp biomicroscopy.⁵ It is the combination of these techniques, slit-lamp biomicroscopy and binocular indirect ophthalmoscopy with scleral depression, that serves as the basis of modern diagnostic examination techniques for the evaluation of vitreoretinal pathology.⁴

Gonin is credited with establishing the pathogenesis of rhegmatogenous retinal detachment and initiating a method of surgical repair based on detailed examination of the retina, localization of retinal breaks, and treatment to the breaks.⁶ Gonin described the ignipuncture procedure, which consisted of localization of all breaks, external drainage of subretinal fluid, and cauterization of the retinal break(s).⁷ Since the establishment of Gonin's principles, the surgical management of rhegmatogenous retinal detachment has continued to evolve. However, among the enduring principles of retinal detachment repair are detailed examination, localization, and treatment of all breaks.

Early technically successful treatment of retinal detachment, first proposed by Gonin and then modified by others, consisted of methods to create chorioretinal adhesion combined with drainage of subretinal fluid. A variety of techniques to create adhesion were used, including the use of caustic chemicals, diathermy, and ultimately cryotherapy which is commonly used currently.^{8,9} Failure of reattachment following external drainage of subretinal fluid led to the realization that shortening the sclera might allow the retina to reapproach and contact the retinal pigment epithelium and become reattached.^{10,11} Surgical management then evolved from scleral shortening to scleral indentation, resulting in a ridge or buckling effect.¹¹ Subsequently, the advantages of indentation were recognized, and procedures were developed to create a ridge or buckle.¹² Custodis¹³ first described scleral buckling as a means of closing retinal breaks. His technique included transscleral diathermy, but he avoided drainage of subretinal fluid. Subsequently, Schepens^{14,15} described segmental and encircling buckles typically using lamellar scleral dissection beds with diathermy to create a chorioretinal adhesion combined with drainage of subretinal fluid. A variety of implant and explant materials have since been introduced, leading to the current common buckling techniques using episcleral hard or sponge silicone.¹⁶

While the first intravitreal gas injections were performed by Ohm,¹⁷ the work of Rosengren represented a major advance in the management of retinal detachment and was a precursor to current pneumatic techniques

including pneumatic retinopexy. Rosengren^{18,19} described the use of intravitreal air combined with diathermy of retinal breaks and external drainage of subretinal fluid. The use of intraocular gas tamponade was popularized by Norton. Norton²⁰ used gas in combination with drainage of subretinal fluid and cryopexy or as an adjunctive agent in the course of scleral buckling. Intraocular gas tamponade was subsequently used in combination with vitrectomy as a primary treatment for retinal detachment and then solely as an intravitreal injection combined with cryotherapy or laser as pneumatic retinopexy.^{21,22}

While recognition of vitreous traction as a mechanism for retinal detachment preceded the work of Gonin, instrumentation for intraoperative visualization and manipulation of the vitreous were not initially available. Cibis²³ was among the pioneering surgeons who developed techniques to cut vitreous bands and to strip vitreous membranes from the surface of the retina. Yet his techniques required visualization through the binocular indirect ophthalmoscope and demanded an unusual degree of surgical skill. It was the innovative work of Machemer^{24,25} that led to the modern era of vitreous surgery. Whereas initially vitrectomy was performed to restore clarity to the ocular media, the subsequent development of multiport systems, microinstrumentation, and wide-angle viewing allowed surgeons to relieve vitreoretinal traction, achieve internal drainage of subretinal fluid, and create chorioretinal adhesions, thus facilitating the repair of retinal detachments.

Currently, surgeons may choose to employ a wide variety of techniques to repair retinal detachments, including temporary plumbage with external balloons or intravitreal gas or more permanent buckles using segmental or encircling external elements. Vitrectomy can be used as an adjunct to scleral buckling or as a primary approach to the retina. Liquid fluorocarbons may be used to facilitate manipulation of the retina or to express subretinal fluid. Perfluorocarbon gases may be used for prolonged internal tamponade, and intravitreal silicone similarly may be used for even longer tamponade. Chorioretinal adhesions may be accomplished with cryopexy, laser photocoagulation, or transscleral diode laser application.

With these techniques, vitreoretinal surgeons have achieved high rates of success for the repair of retinal detachment.^{26,27} Despite this success, not all retinal detachments are repairable, and not all successfully repaired detachments regain normal central visual acuity.²⁸ Therefore, considerable attention has been applied to identify risk factors for retinal detachment in hopes of better understanding the pathogenesis of detachment and, more important, identifying eyes with a propensity for detachment with thoughts of preventive

therapy.

A number of risk factors have been recognized, including increasing age, myopia, peripheral retinal degeneration, detachment in the fellow eye, and surgical trauma, most commonly related to cataract surgery.²⁹ It has long been recognized that following cataract surgery, patients are at an increased risk of retinal detachment. Modifications of cataract surgical technique, such as the development of extracapsular surgery with posterior chamber intraocular lens implantation, has resulted in a reduced incidence of postoperative retinal detachment.^{30,31} Yet, despite these modifications, the incidence of retinal detachment is still substantially greater than in similar unoperated eyes.^{32,33}

Clinical experience has also shown that eyes that have experienced a retinal break or detachment are at risk of sequential onset of new breaks and, therefore, retinal detachments.^{34,35} While the development of new breaks was noted after primary treatment of breaks or detachment, it was their sudden onset following pneumatic retinopexy that has drawn attention to the issue of sequential development of retinal breaks.^{22,36,37}

Since aphakia/pseudophakia is a known independent risk factor for the development of retinal breaks and/or detachment in eyes without pre existing retinal pathology, and since phakic eyes that have undergone repair of retinal breaks or detachment may develop the sequential onset of new breaks despite remaining phakic, it is reasonable to expect that cataract surgery in eyes that have previously undergone successful repair of breaks or detachment will experience a higher risk of postoperative new breaks or detachment than eyes that have not required prior retinal treatment. While a number of small reports have attempted to evaluate this risk, the current study was designed to quantify the risk more comprehensively and to identify predisposing risk factors. It is hoped that confirmation and quantification of this risk will allow ophthalmologists to inform patients preoperatively of potential postoperative risks and will increase awareness of the need for postoperative recognition of symptoms and reevaluation of the retina. Furthermore, this study will attempt to compare the relationship of new postoperative retinal breaks or detachment following cataract surgery in eyes that have undergone successful repair of phakic breaks or detachment to the sequential onset of new breaks or detachment in phakic eyes that have undergone successful repair of tears or detachment but which did not undergo cataract extraction. In so doing, this study will attempt to determine whether or not cataract surgery per se represents an independent risk factor for the development of retinal tears or detachment in these patients.

METHODS

This is a retrospective, database study of patients evaluated for retinal tear or detachment. The data compiled for this study were derived from the collective patients of physicians of the Barnes Retina Institute or its predecessor, Retina Consultants, Ltd, a group of fellowship-trained vitreoretinal surgeons in a single group practice providing medical and surgical treatment for the care of patients with vitreoretinal disease. The standard operating procedure of this practice mandated that each patient encounter was coded as to diagnosis and treatment by the treating surgeon at the time of the encounter and entered immediately into the practice database. A computer search for all patients evaluated at the Barnes Retina Institute between January 1, 1990, and December 31, 2000, with a diagnosis of retinal tear or detachment was made in January 2001. Of those, only patients who presented with a phakic break, phakic subclinical retinal detachment, or phakic retinal detachment were studied. Eyes excluded included aphakes, pseudophakes, or those in which the repair of the phakic event had failed, leaving the eye with a chronic detachment. Only eyes with a rhegmatogenous tear or detachment were selected. Those eyes that had an exudative, tractional, or combined rhegmatogenous and tractional etiology were excluded. Eyes with a proliferative retinopathy, including those with proliferative diabetic retinopathy, branch vein occlusion, proliferative sickle retinopathy, or retinopathy of prematurity, were excluded. Similarly, eyes that had suffered penetrating trauma were excluded. Eyes treated for retinoschisis or schisis-related detachment were excluded. Eyes in which the tear or detachment occurred at the time of or as a consequence of vitreous surgery for another diagnosis, such as repair of a macular hole, delamination of epiretinal membranes, or submacular surgery, also were excluded. Tears or detachments associated with bacterial or fungal endophthalmitis or viral retinitis in immunocompromised patients were excluded. Additionally, eyes in which surgery was performed elsewhere or for which follow-up was not available were excluded.

Each identified record was retrieved and reviewed by the author, including details of initial examination, retinal drawings, operative notes, and, for those hospitalized, admission examination and the preoperative retinal drawing. Postoperative examinations, drawings, and reports were analyzed. Comparison of drawings, operative reports, and physicians' notes were used to be certain of the classification, number and location of breaks, and the presence of vitreous hemorrhage. Data regarding cataract surgery were generally available in the retina record, but in those instances (approximately 15%) when information

was not available, such data were obtained from the records of referring ophthalmologists.

A template was designed for data collection and ultimately computer-assisted analysis. Since the data were derived from the collective patients in a group practice, the investigator did not personally perform each preoperative or postoperative evaluation or surgical procedure. However, the investigator personally reviewed each patient chart, determined eligibility for the study population, and performed both data entry and data analysis.

For the purposes of this study, data collected included age, sex, laterality, refractive error recorded as spherical equivalent at the time of initial presentation with a tear or retinal detachment, initial Snellen acuity, type of break, number of breaks and location of break by quadrant, location of breaks by position anterior or posterior to the equator, presence of vitreous hemorrhage, and presence of vitreous detachment. Axial length measurements were not consistently available and therefore were not included in this analysis.

Subclinical detachments were defined as retinal breaks with subretinal fluid extending more than one disc diameter beyond the edge of the break, regardless of the position of the break in its relationship to the equator. Retinal breaks were subdivided according to type, including horseshoe tear, horseshoe tear in lattice, atrophic hole, atrophic holes in lattice, operculated breaks, and dialyses. A history of blunt trauma, family history of tear or detachment, and the presence of a retinal break or detachment in the fellow eye were noted. A positive family history was defined as first- or second-degree relatives with a history of retinal tear or detachment. The occurrence of a new break after primary repair and the timing of its onset were recorded. New breaks that developed following primary repair are described as the "sequential onset of new breaks" to distinguish them from breaks or retinal detachments that occurred following cataract surgery. The method of treatment for either breaks or subclinical detachment was subdivided into those eyes that had received photocoagulation, cryopexy, combinations of photocoagulation and cryopexy, or pars plana vitrectomy with gas tamponade. The method of treatment for retinal detachment was classified by method of repair and subdivided into scleral buckle, vitrectomy, or combined buckle and vitrectomy. Scleral buckles were further categorized into those for which the elements were encircling or segmental. The use of a temporary plombage, such as pneumatic repair, or external plombage with a Lincoff balloon, was noted. The use of adjuvants, such as gas or silicone, was recorded. The number of procedures required to reattach the retina was tabulated.

Eyes that underwent subsequent cataract surgery were subdivided into those that became aphakic or that

underwent implantation of an intraocular lens, and the position of the intraocular lens in the anterior chamber or posterior to the iris was noted. A subsequent YAG capsulotomy and the interval between cataract extraction and capsulotomy were noted. Complications of cataract surgery, including capsular rupture, vitreous loss, and retained lens fragments, were recorded.

Follow-up data included the sequential development of new breaks or detachment following initial repair in those eyes that remained phakic and the development of retinal breaks or detachment following cataract surgery in those that underwent subsequent cataract surgery. The interval between repair and sequential onset of a new break or detachment, location of the break, method of repair, and success of repair were noted. The development and time of onset of a new break or detachment following cataract surgery were recorded. Data regarding visual acuity were collected as Snellen acuity but then converted to decimal notations. Acuity was also converted to a logarithm of the minimum angle of resolution (LogMAR score). Intervals of follow-up after initial repair, cataract extraction, and subsequent repair of new breaks or detachment were calculated. For those patients who had sequential onset of new tears while still phakic, the date of the last treatment of a sequential break was used to calculate the interval between that date and cataract surgery or the final visit.

Data were analyzed with the assistance of biostatisticians from the Biostatistics Core affiliated with the Department of Ophthalmology and Visual Sciences, Washington University School of Medicine, St Louis, Mo. Analyses were performed with SAS statistical software, Version 8.1 (SAS Institute, Cary, NC).³⁸ Mean, median, and standard deviations were calculated for all continuous variables. The Kruskal-Wallis nonparametric test was used when comparing the distributions of continuous variables among two or more groups. The Fisher's exact test (FET) was used to compare the distributions of categorical variables. Kaplan-Meier life table analyses were performed to compare time of onset of retinal break for eyes that had undergone cataract surgery and those that had not, and 95% confidence intervals were calculated for the hazard ratio. A variable was considered to be statistically significant if the *P* value was less than .05. All statistical tests were two-tailed. The data were analyzed for the entire study population (*n* = 2,175) and for each individual subgroup: phakic breaks (*n* = 1,415); phakic subclinical detachment (*n* = 396); and phakic retinal detachment (*n* = 364).

The protocol was reviewed and consent for data retrieval was approved by the Human Studies Committee at Washington University School of Medicine, St Louis, Mo.

RESULTS

DEMOGRAPHICS OF STUDY SAMPLE

A total of 2,175 eyes of 1,820 patients met the entry criteria of the study. The study group of 2,175 eyes was further subdivided into three categories based on the underlying retinal findings at the time of entry into the study: phakic breaks (*n* = 1,415 eyes), phakic subclinical detachment (*n* = 396 eyes), and phakic retinal detachment (*n* = 364 eyes).

The study population consisted of 1,147 eyes of males (53%) and 1,028 eyes of females (47%). The right eye was affected in 1,138 (52%), and the left eye in 1,037 (48%). Three hundred fifty-five patients had bilateral retinal disease that met the entry criteria, and each of the 710 eyes was counted individually. Additionally, eyes of 160 patients had a retinal tear, subclinical detachment, or detachment involving the fellow eye; however, while the primary eye was eligible and included, those fellow eyes did not meet the entry criteria of the study and, therefore, were excluded.

The mean age for the entire study population was 55.7 years, with a range of 5 to 86 years. The median age was 59 years. Table I shows the distribution of eyes by age. The three subgroups showed similar patterns of age distribution to that of the entire study population (Figure 1). Patients with a phakic tear had a median age of 60 years, whereas patients with a subclinical detachment had a median age of 54.5 years and patients with retinal detachment had a median age of 53 years.

Refractive error at the time of initial presentation with a retinal tear or retinal detachment was recorded as a spherical equivalent. The median spherical equivalent was -1.0 D diopters (D) for the entire study group; for eyes with a phakic break the median spherical equivalent was -0.5 D; eyes with subclinical detachment had a median spherical equivalent of -2.5 D; and eyes with a phakic retinal detachment had a median spherical equivalent of -2.9 D. The distribution of refractive error for the entire study group was similar to that of eyes undergoing cataract surgery and is shown in Figures 2 and 3.

ONSET OF NEW RETINAL BREAKS OR DETACHMENT FOLLOWING CATARACT SURGERY

During the period of follow-up, 371 eyes of the study group underwent cataract surgery. Of these, 17 (4.6%) developed a new break (8) or detachment (9) following cataract surgery. Analysis by subgroup showed that new breaks or detachments occurred in 7 (4.1%) of 173 eyes with a previous phakic break; in 4 (6.8%) of 59 eyes with a previous phakic subclinical detachment; and in 6 (4.3%) of 139 eyes with a previous phakic retinal detachment (Table II). There was no statistically significant difference in the frequency of these new breaks or detachments by subgroup (*P* = .67) (FET).

TABLE I: DEMOGRAPHICS: PATIENT AGE

	ENTIRE STUDY	SUBGROUPS		
		PHAKIC BREAK	PHAKIC SC RD	PHAKIC RD
No.	2,175	1,415	396	364
Mean	55.7 yr	57.9 yr	52.0 yr	51.4 yr
Median	59.0 yr	60.0 yr	54.5 yr	53.0 yr
Range	5-86 yr	6-86 yr	6-85 yr	5-84 yr
SD	14.4	13.4	15.2	15.8

RD, retinal detachment; SC, subclinical.

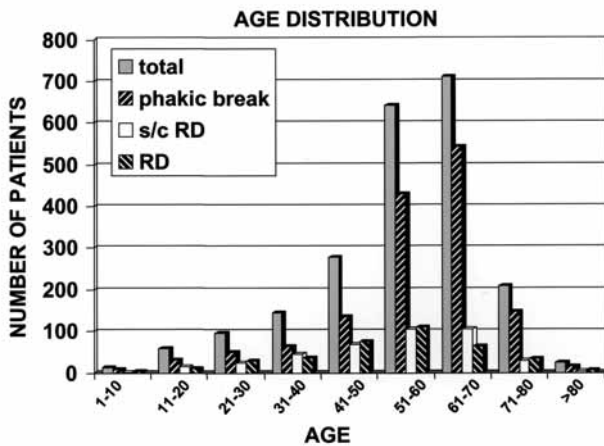


FIGURE 1

Age distribution of all eyes as well as for those eyes in the subgroups of phakic break, subclinical retinal detachment (s/c RD), and those with retinal detachment (RD).

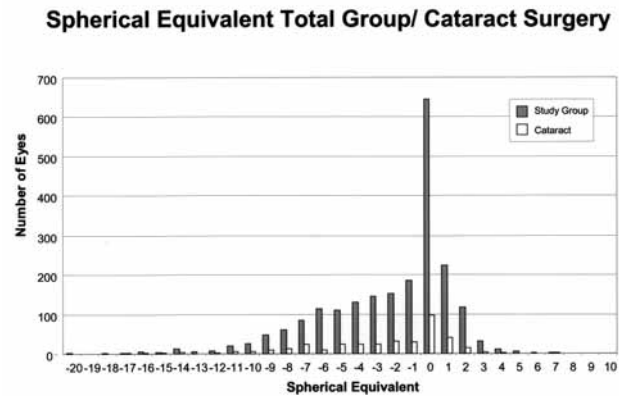


FIGURE 2

Spherical equivalents of all eyes in study group compared to distribution of spherical equivalents in eyes within the study group that subsequently underwent cataract surgery.

Percent Spherical Equivalent Whole Group and Cataract Surgery

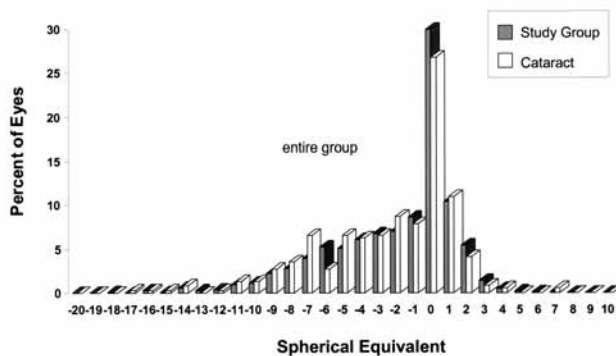


FIGURE 3

Percent spherical equivalents of entire group. Graph compares the percentage of eyes in entire study group with eyes that subsequently underwent cataract surgery.

The onset of a new retinal break or detachment following cataract surgery occurred at an average of 25.9 months, with a median of 17 months and a range of 1 to 107 months postoperatively (Table III). The new breaks or detachments that developed following cataract surgery occurred within 1 year for 35% of affected eyes and within 2 years for 71% of affected eyes. Only 24% of new breaks or detachments occurred at an interval of onset greater than 3 years (Table IV).

The development of a new retinal break or detachment was further analyzed to determine risk factors that might be related to an increased frequency of onset. Factors evaluated included age, gender, laterality, spherical equivalent, localization of breaks, vitreous hemorrhage, presence of posterior vitreous detachment, type of breaks, number of breaks, status of the fellow eye, family history, history of blunt nonpenetrating trauma, method of repair of break or detachment, number of operations, type of cataract surgery, complications of cataract surgery, presence of a YAG capsulotomy, type of lens implanted, and sequential onset of new breaks following the initial presenting break or detachment.

TABLE II: NEW BREAK OR RETINAL DETACHMENT FOLLOWING CATARACT SURGERY

	PHAKIC			TOTAL
	BREAK	SC RD	RD	
No. of eyes	173	59	139	371
PO tear	3	2	3	8
PO RD	4	2	3	9
Combined new break and RD	7	4	6	17
%	4.1%	6.8%	4.3%	4.6%

$P = .67$ Fisher's exact test.

PO, postoperative; RD, retinal detachment; SC, subclinical.

TABLE III: ONSET OF NEW BREAK OR RETINAL DETACHMENT FOLLOWING CATARACT SURGERY

Mean	25.9 mo
Median	17 mo
Range	1-107 mo

TABLE IV: ONSET OF NEW BREAK OR RETINAL DETACHMENT FOLLOWING CATARACT SURGERY (CUMULATIVE)

FOLLOW-UP	6 MO	1 YR	2 YR	3 YR	>3 YR
Cumulative No.	5	6	12	13	17
Cumulative %	29%	35%	71%	76%	100%

TABLE V: NEW BREAK OR RETINAL DETACHMENT FOLLOWING CATARACT SURGERY: GENDER

GENDER	NO.	%
Male	12/214	5.6%
Female	5/157	3.2%

$P = .32$ Fisher's exact test.

TABLE VI: NEW BREAK OR RETINAL DETACHMENT FOLLOWING CATARACT SURGERY: LATERALITY

EYE	CATARACT SURGERY	NEW BREAK/RD	%
OD	192	10	5.2%
OS	179	7	3.9%

$P = .62$ Fisher's exact test.

ANALYSIS OF POTENTIAL RISK FACTORS

Demographics

A new break or retinal detachment occurred in 12 (5.6%) of 214 male patients and in 5 (3.2%) of 157 female patients ($P = .32$) (Table V). A new break or detachment occurred in 10 (5.2%) of 192 right eyes and in 7 (3.9%) of 179 left eyes ($P = .62$) (Table VI). The median age for the entire study group was 59 years (Table I) and for the group that underwent cataract surgery ($n = 371$), 59 years. There was no statistically difference in the median age of patients who underwent cataract surgery and those who did not ($P = .50$). The median age of patients who experienced a new break or detachment following cataract surgery was 56 years (range, 15 to 83 years). For patients in whom no new break or detachment occurred after cataract surgery the median age was 59 years (range, 5 to

86 years) ($P = .22$) (Table VII).

Spherical Equivalent

Because measurement of axial length was not consistently available, refractive status was based on determination of

TABLE VII: NEW BREAK OR RETINAL DETACHMENT FOLLOWING CATARACT SURGERY: PATIENT AGE

	NO. OF EYES	AVE AGE	MEDIAN AGE
No new break or RD	354	58.8 yr	59.0 yr
New break or RD	17	52.4 yr	56.0 yr

$P = .22$ Kruskal-Wallis.

the spherical equivalent at the time of initial presentation with a retinal break or detachment. The spherical equivalent of eyes that subsequently experienced a new break or detachment following cataract surgery was compared to that of the entire group of eyes. For the 17 eyes that experienced a new retinal break or detachment following cataract surgery, the median refractive error as measured by spherical equivalent at the time of initial presentation was -3.5 D with a standard deviation of 6.1 D. This is compared to 354 eyes that underwent cataract surgery but had no postoperative new break or detachment for whom the median spherical equivalent at the time of initial presentation was -1.8 D with a standard deviation of 3.8 D ($P = .34$) (Table VIII). In comparison, the median spherical equivalent for the entire study group was -1.0 D with a standard deviation of 3.8 D. While there appears to be a trend indicating that higher degrees of myopia at the time of initial presentation measured as spherical equivalent were associated with new retinal breaks or detachment following cataract surgery, these data did not achieve statistical significance. ($P = .21$) (KW) (Table IX).

Location of Breaks

The location of initial retinal breaks was identified in all

eyes. Forty-eight percent of patients had a tear located in the superotemporal retinal quadrant, 26% in the inferotemporal quadrant, 19% in the superonasal quadrant, and 8% in the inferonasal quadrant.

The location of the tear was available in 13 of 17 eyes that underwent cataract surgery and experienced new retinal breaks or detachment. Of these, 4 occurred in the superotemporal quadrant, 4 occurred inferotemporally, 3 occurred superonasally, and 2 occurred inferonasally. Eight of the 13 eyes (62%) developed new breaks in the temporal retina compared to the entire study group, in which 74% had presented initially with breaks in the temporal retina (Table X).

The location of retinal breaks in relation to the equator was also analyzed (Table XI). A total of 328 study eyes were identified for which a break was located posterior to the equator. Of these, 58 underwent cataract surgery, and only 1 of 58 (1.7%) experienced a postsurgical new retinal break or detachment. In comparison, 17 (4.6%) of 371 of all eyes that underwent cataract surgery subsequently developed a new break or detachment. A posterior location of the initial retinal break was not statistically associated with the development of new retinal breaks or detachments following cataract surgery ($P = .49$).

TABLE VIII: NEW BREAK OR RETINAL DETACHMENT FOLLOWING CATARACT SURGERY: REFRACTIVE ERROR AS SPHERICAL EQUIVALENT

	NO.	MEAN	MEDIAN	SD
No new break or RD	354	-2.6	-1.8	3.8
New break or RD	17	-3.4	-3.5	6.1

$P = .34$ Kruskal-Wallis.

TABLE IX: NEW BREAK OR RETINAL DETACHMENT FOLLOWING CATARACT SURGERY: REFRACTIVE ERROR AS SPHERICAL EQUIVALENT

	NO.	MEAN	MEDIAN	SD
Entire study group	2,135	-2.2	-1.00	3.8
New break or RD	17	-3.4	-3.5	6.1

$P = .21$ Kruskal-Wallis.

TABLE X: LOCATION OF NEW BREAKS

	INITIAL EVENT	NEW BREAK*
Sup Tem	48%	31%
Inf Temp	26%	31%
Combined	74%	62%
Sup Nasal	19%	23%
Inf Nasal	8%	15%
Combined	27%	38%

*Data available for 13 of 17 eyes.

TABLE XI: NEW BREAK OR RETINAL DETACHMENT FOLLOWING CATARACT SURGERY: LOCATION BREAK POSTERIOR TO EQUATOR

NO. OF EYES	CATARACT SURGERY	NEW BREAK/RD	%
328	58	1	1.7

Vitreous Hemorrhage

An analysis was carried out to determine whether the presence of blood in the vitreous at the time of initial presentation with a retinal tear or detachment was related to the development of a new break or retinal detachment following cataract surgery. A total of 586 eyes were noted to have vitreous hemorrhage at the time of the initial retinal break or detachments; of these, 71 eyes ultimately underwent cataract surgery. Five of the 71 eyes (7%) that underwent cataract surgery and that had blood in the vitreous at the time of the initial retinal break or detachment subsequently developed a new retinal break or detachment. In comparison, 12 of 300 eyes (4%) that underwent cataract surgery and that had no blood present in the vitreous at the time of the initial presentation subsequently developed a new retinal break or detachment. There was no statistically significant difference in these values ($P = .34$) (Table XII).

Posterior Vitreous Detachment

An analysis was undertaken to determine if the presence of a vitreous detachment (PVD) diagnosed by the ophthalmoscopic appearance of a Weiss ring was related to the subsequent development of a new retinal break or detachment following cataract surgery. Of 371 eyes that underwent cataract surgery, 218 had a PVD and 6 (2.8%) developed a new retinal break or detachment postoperatively. Of the 153 eyes that underwent cataract surgery and that did not have a PVD, 11 (7.2%) developed a new retinal break or detachment postoperatively. These data suggest that the absence of a PVD may predispose an eye to develop a retinal break or detachment following cataract surgery. However, while these values are suggestive, they approach but do not achieve statistical significance ($P = .07$) (Table XIII).

Type of Retinal Break

An analysis was carried out to determine if the type of break present at the initial event would be of significance in predicting the development of new retinal breaks or detachments following cataract surgery. Of the 371 eyes that underwent cataract surgery, data describing the type of break were available on 367 (Table XIV). Of these, 207 had a horseshoe tear, and 11 (5.3%) of these suffered a new retinal break or detachment following cataract surgery. Fifty-

two eyes were noted to have horseshoe tears associated with lattice degeneration and of these 1 (1.9%) suffered a new retinal break or detachment following cataract surgery. Combining these groups, a total of 259 eyes had horseshoe tears and 12 (4.6%) suffered a new retinal break or detachment. Operculated tears were noted in 44 eyes, and 1 (2.3%) experienced a new retinal break or detachment following cataract surgery. No eye of the 23 with atrophic holes developed a new retinal break or detachment; however, two eyes with atrophic holes in lattice degeneration (9.5%) suffered a new retinal break or detachment. A total of 2 of 44 (4.5%) with atrophic holes of any sort developed a new retinal break or detachment. A retinal dialysis was noted in 20 eyes, and of these 2 (10%) experienced a new retinal break or detachment following cataract surgery. A comparison of horseshoe tears versus atrophic holes revealed no statistically significant difference; as 12 of 259 eyes (4.6%) that developed a horseshoe tear as the configuration of their retinal break suffered a subsequent new retinal break or detachment, whereas 2 of 44 eyes (4.5%) with atrophic holes experienced a new retinal break or detachment ($P = 1.00$; FET). Overall, there was no statistically significant relationship between the type of initial phakic retinal tear and subsequent development of new breaks or detachments following cataract surgery.

Number of Breaks

The number of breaks present at the time of initial presentation was available for 358 of 371 eyes that subsequently underwent cataract surgery (Table XV). One hundred ninety-five eyes had a single break at the time of their initial presenting event, and of these 9 (4.6%) ultimately developed a new retinal break or detachment following cataract surgery. Four of 82 eyes (4.9%) that had two breaks at the time of their initial presentation developed a new retinal break or detachment following cataract surgery. Five or more breaks were initially present in 21 eyes, and of these 1 (4.8%) developed a new retinal break or detachment following cataract surgery (Table XV). Of those eyes that had one or two breaks at the time of their initial presentation, 13 of 277 (4.7%) developed a new retinal break or detachment, whereas for those eyes with three or more breaks at the time of initial presentation 4 of 81 (4.9%) developed a new retinal break or

TABLE XII: NEW BREAK OR RETINAL DETACHMENT FOLLOWING CATARACT SURGERY: BLOOD IN VITREOUS AT INITIAL REPAIR

	NO. OF EYES	NEW BREAK/RD	%
No blood	300	12	4%
Blood	71	5	7%

$P = .34$ Fisher's exact test.

TABLE XIII: POSTOPERATIVE NEW BREAK OR RETINAL DETACHMENT FOLLOWING POSTERIOR VITREOUS DETACHMENT

	CATARACT SURGERY	NEW BREAK/RD	%
Yes PVD	218	6	2.8%
No PVD	153	11	7.2%

$P = .07$ Fisher's exact test.

TABLE XIV: NEW BREAK OR RETINAL DETACHMENT FOLLOWING CATARACT SURGERY: TYPE OF INITIAL BREAK*

TYPE	NO. OF EYES	NEW BREAK/RD	%
HST	207	11	5.3%
HST + lattice	52	1	1.9%
Operculated tear	44	1	2.3%
Atrophic hole	23	0	0.0%
Atrophic hole in lattice	21	2	9.5%
Dialysis	20	2	10%
Total	367	17	4.6%

$P = .33$ Fisher's exact test.

HST, horseshoe tear.

*Data available for 367 of 371 eyes.

detachment ($P = 1.00$; FET)(Table XVI). Therefore, there was no statistically significant relationship between the number of tears present at the time of initial phakic presentation and the subsequent development of new breaks or detachment following cataract surgery.

The majority of eyes (9/17) (53%) that experienced a new retinal break or detachment following cataract surgery were those that had only one break at the time of their initial presentation. Thirteen of 17 (76%) eyes with new retinal breaks or detachments following cataract surgery occurred in eyes with one or two tears at the time of their initial presentation, and only 4 of 17 (24%) new retinal breaks or detachments occurred in eyes with three or more breaks at the time of initial presentation.

Fellow Eye

The presence of a retinal break or detachment in the fellow eye was also analyzed. Of the 2,175 eyes studied, 873 (40%) had a retinal break or detachment in the fellow eye. Of these, 191 (22%) ultimately underwent cataract surgery, and 14 of 191 (7.3%) developed a new retinal

TABLE XV: NEW BREAK OR RETINAL DETACHMENT FOLLOWING CATARACT SURGERY:

INITIAL EVENT NO. OF BREAKS	CATARACT SURGERY (n)	NEW BREAK/RD	
1	195	9	4.6%
2	82	4	4.9%
3	40	3	7.5%
4	20	0	0%
5	21	1	4.8%
Total	358	17	4.7 %

*Data available for 358 of 371 eyes.

break or detachment postoperatively. There was no known break or retinal detachment in the fellow eye of 1,302 (60%) of 2,175 study eyes. Of these, 180 underwent cataract surgery and 3 (1.7%) of 180 developed a new retinal break or detachment following cataract surgery. These values were statistically significant ($P = .01$) (Table XVII). Therefore, the presence of a retinal break in the fellow eye of a patient who initially presented with a phakic break or detachment in the study eye was a significant risk factor for development of a new break or retinal detachment following cataract surgery in the study eye.

One may question if inclusion in the study group of both eyes in patients with bilateral eligible tears or detachment caused a significant change in the incidence of post-operative new retinal breaks or detachment. A total of 873 eyes in the study had a history of retinal break or detachment in the fellow eye. However, because of other characteristics, such as pre existing aphakia or pseudophakia, not all fellow eyes were eligible for inclusion in this study. The study group included 710 eyes of 355 patients who were treated for bilateral phakic events. Of these, 146 eyes underwent cataract surgery and 7 of 146 (4.8%) developed a new event postoperatively. Of the remaining 225 eyes

TABLE XVI: NEW BREAK OR RETINAL DETACHMENT FOLLOWING CATARACT SURGERY: NO. BREAKS PRIMARY EVENT*

NO. OF BREAKS PRIMARY EVENT	NO. OF EYES	NEW BREAK/RD	%
1-2	277	13	4.7%
>3	81	4	4.9%

$P = 1.00$ Fisher's exact test.

*Data available for 358 of 371 eyes.

TABLE XVII: NEW BREAK OR RETINAL DETACHMENT FOLLOWING CATARACT SURGERY: FELLOW EYE

	n	CATARACT SURGERY	NEW BREAK/RD	%
Break in fellow eye	873	191	14	7.3%
No break in fellow eye	1,302	180	3	1.7%

$P = .01$ Fisher's exact test.

that did not have a fellow eye in the study and that underwent cataract surgery, 10 (4.4%) developed a new retinal break or detachment postoperatively. These values were not statistically significant ($P = 1.00$; FET). Therefore, the incidence of new retinal breaks or detachment following cataract surgery in eyes that were bilaterally represented in the study did not differ significantly from those eyes with unilateral involvement in the remainder of the study group.

Family History

A family history of retinal break or detachment was elicited for 141 eyes. Twenty-nine of these eyes underwent cataract surgery, and 2 of these (6.9%) developed a new retinal break or detachment following cataract surgery. Of eyes for which there was no family history of retinal break or detachment, 342 underwent cataract surgery. Of these, 15 (4.4%) developed a new retinal break or detachment following cataract surgery. While suggestive, these values were too small to be statistically significant ($P = .63$) (XVIII). Therefore, in this population a family history of retinal break or detachment was not shown to be a risk factor for new breaks or detachment following cataract surgery.

TABLE XVIII: FAMILY HISTORY OF RETINAL BREAK OR DETACHMENT

	CATARACT SURGERY	NEW BREAK/RD	%
Positive family history	29	2	6.9%
No family history	342	15	4.4%

$P = .63$ Fisher's exact test.

Blunt, Nonpenetrating Trauma

The history of traumatically induced tear or detachment was present in 112 eyes, of which 10 underwent cataract surgery. None developed a new retinal break or detachment following removal of the cataract. Therefore, these data showed no relationship between blunt, nonpenetrating trauma at the time of initial presentation and the subsequent development of new breaks or detachment following cataract surgery. However, the number that underwent cataract surgery was too small for statistical analysis.

Type of Treatment of Phakic Break or Subclinical Retinal Detachment

The relationship of treatment type to the development of new retinal breaks or detachment was analyzed. A total of 173 eyes presented initially with a phakic retinal tear and subsequently underwent cataract surgery. Of these, 7 of 173 (4%) developed a new retinal break or detachment following cataract surgery. Three of 41 eyes (7.3%) that were treated with laser and 4 of 120 eyes (3.3%) treated with cryo developed a new retinal break or detachment following cataract surgery ($P = .61$) (Table XIX). Of 57 eyes that initially presented with a subclinical retinal detachment and underwent cataract surgery, 10 were treated with laser photocoagulation and none developed a new retinal break or detachment. Four of 37 eyes (11%) treated with cryopexy ultimately developed a new retinal break or detachment following cataract surgery. There was no statistically significant difference in these values ($P = .56$) (Table XX).

Because these two groups, retinal break and subclinical retinal detachment, are similar in their retinal findings

TABLE XIX: NEW BREAK OR RETINAL DETACHMENT FOLLOWING CATARACT SURGERY: PHAKIC BREAKS (n = 173)

	TYPE OF TREATMENT					TOTAL
	LASER	CRYO	BOTH	PPV/AFX	UNKNOWN	
No. of eyes	41	120	11	0	1	173
New break/RD	3	4	0	0	0	7
%	7.3%	3.3%	0	0	0	4%

$P = .61$ Fisher's exact test.

AFX, air-fluid exchange; Cryo, cryopexy; PPV, pars plana vitrectomy.

TABLE XX: NEW BREAK OR RETINAL DETACHMENT FOLLOWING CATARACT SURGERY: SUBCLINICAL DETACHMENT (n = 57)

	TYPE OF TREATMENT			
	LASER	CRYO	BOTH	UNKNOWN
No. of eyes	10	37	9	1
New break or RD	0	4	3	0
%	0	11%	33%	0

$P = .56$ Fisher's exact test.

Cryo, cryopexy.

and are numerically of small size, data regarding treatment was combined for analysis. Combining the groups of eyes that presented initially with a phakic break and those that had a phakic subclinical detachment, 3 of 51 eyes (5.9%) treated with laser developed a new retinal break or detachment following cataract surgery; whereas 8 of 157 eyes (5.1%) treated with cryopexy developed a new retinal break or detachment following cataract surgery. These values did not reach statistical significance ($P = .73$) (Table XXI). Therefore, these data did not indicate a significant relationship between the type of treatment for an initial phakic break or subclinical retinal detachment and the subsequent development of a new break or retinal detachment following cataract surgery.

Method of Repair of Retinal Detachment

The method of repair for the 139 eyes ($n = 139$) that presented with a phakic retinal detachment as their primary event was analyzed. Six of 139 eyes were managed by pneumatic retinopexy, and none experienced a new retinal break or detachment following cataract surgery. Four (6.5%) of 62 eyes treated by means of scleral buckling developed a new retinal break or detachment following cataract surgery. One of 9 (11.1%) managed by pars plana vitrectomy alone developed a new retinal break or detachment following cataract surgery. One of 62 eyes (1.6%) managed by a combination of scleral buckling and vitrectomy developed a new retinal break or detachment following cataract surgery. These values did not reach statistical significance ($P = .28$) (Table XXII).

Eyes that underwent scleral buckling with or without combined vitrectomy were compared with eyes treated by

vitrectomy alone. Five of 124 eyes (4%) that underwent a scleral buckle or scleral buckle in combination with vitrectomy ultimately developed a new retinal break or detachment following cataract surgery. In contrast, one of 9 eyes (11.1%) managed by vitrectomy alone developed a subsequent new retinal break or detachment following cataract surgery. These values did not reach statistical significance ($P = .35$). Eyes that underwent vitrectomy alone or vitrectomy plus scleral buckle were compared with eyes treated by a buckle alone. Two of 71 eyes (2.8%) managed by vitrectomy or vitrectomy in combination with scleral buckle developed a retinal tear or detachment following cataract surgery, as compared to 4 of 62 (6.5%) eyes managed by scleral buckling alone that developed a new retinal break or detachment following cataract surgery. These values did not reach statistical significance ($P = .42$) (Table XXIII).

Of the 124 eyes treated with scleral buckling, 109 underwent an encircling procedure and 3 (2.8%) developed a new retinal break or detachment following cataract surgery. Two of 11 eyes (18.2%) that were treated by means of a segmental buckle alone developed a subsequent new retinal break or detachment following cataract surgery. The difference is so large that it is suggestive; yet the number of eyes treated with a segmental buckle is small and, therefore, the values approach but do not reach statistical significance ($P = .07$; FET) (Table XXIV).

Data regarding the number of retinal repair operations required at the time of the initial presenting event were available for 135 of 139 eyes with a phakic retinal detachment. A single operation was required in 104 of 135 eyes (77%); two operations were required in 19 eyes

TABLE XXI: NEW BREAK OR RETINAL DETACHMENT FOLLOWING CATARACT SURGERY: BREAK PLUS SUBCAPSULAR DETACHMENT

	LASER	CRYO	BOTH
No. of eyes	51	157	22
New break or RD	3	8	0
%	5.9%	5.1%	0

$P = .73$ Fisher's exact test.

Cryo, cryopexy; RD, retinal detachment; SC, subclinical.

TABLE XXII: NEW BREAK OR RETINAL DETACHMENT FOLLOWING CATARACT SURGERY: PHAKIC RETINAL DETACHMENT ($n = 139$)

	TYPE OF TREATMENT			
	PNEUMATIC	SBP	PPV	SBP + PPV
No. of eyes	6	62	9	62
New break or RD	0	4	1	1
%	0	6.5%	11%	1.6%

$P = .28$ Fisher's exact test.

PPV, pars plana vitrectomy; SBP, scleral buckling procedure.

TABLE XXIII: SURGICAL PROCEDURE FOR RETINAL DETACHMENT

	NO.	NEW BREAK/RD	%	P VALUE*
SBP or SBP + VIT	124	5	4.0%	$P = .35$
VIT alone	9	1	11.1%	
VIT +SBP or VIT	71	2	2.8%	$P = .42$
SBP alone	62	4	6.5%	

*Fisher's exact test.

SBP, scleral buckling procedure; VIT, vitrectomy.

TABLE XXIV: NEW BREAK OR RETINAL DETACHMENT FOLLOWING CATARACT SURGERY: PHAKIC RETINAL DETACHMENT ACCORDING TO TYPE OF BUCKLE (n = 124)*

BUCKLE PROCEDURE	NO. OF EYES	NEW BREAK/RD	%
Encircling	109	3	2.8%
Segmental	11	2	18.2%

$P = .07$ Fisher's exact test.

*Data available for 120 of 124 eyes.

(14%); three operations were required in 11 eyes (8%); and four operations were required in 1 eye.

Results were evaluated to determine whether the number of operations needed to repair the initial retinal detachment influenced the development of a new retinal break or detachment following cataract surgery; 5 of 104 eyes (4.8%) that had undergone one operation at the time of repair of the initial detachment; 1 of 19 eyes (5.3%) that had undergone two operations at the time of repair of the initial detachment developed new retinal breaks or detachment following cataract surgery. These values were not statistically significant ($P = 1.0$). No new breaks or detachments occurred in eyes requiring more than two operations to repair a primary retinal detachment (Table XXV). Therefore, the data do not show a statistically significant relationship between the type of repair of initial phakic retinal detachment or the number of operations required to repair the initial retinal break or detachment and the subsequent development of new breaks or

retinal detachment following cataract surgery.

Complications of Cataract Surgery

The occurrence of reported complications at the time of cataract surgery was also evaluated. Eleven eyes suffered complications of cataract surgery and, of these, 2 (18.2%) developed a new retinal break or detachment. In contrast, new retinal breaks or detachment occurred in 15 of 360 eyes (4.2%) with no reported complications of cataract surgery. The difference is so large that it suggests a relationship between complications of cataract surgery and the subsequent development of new breaks or detachment following cataract surgery, yet the numbers are small; therefore, the values approach but do not reach statistical significance ($P = .09$; FET) (Table XXVI).

YAG Capsulotomy

One hundred twenty-five of 371 eyes underwent a YAG capsulotomy following cataract surgery and, of these, five

TABLE XXV: NO. OF OPERATIVE PROCEDURES TO REPAIR PRIMARY RETINAL DETACHMENT

	1	2	3	4	UNKNOWN
No. of eyes	104	19	11	1	4
New break or RD	5	1			
%	4.8%	5.3%			

$P = 1.00$ Fisher's exact test.

TABLE XXVI: NEW BREAK OR RETINAL DETACHMENT FOLLOWING CATARACT SURGERY:
COMPLICATIONS OF CATARACT SURGERY

	NO. OF EYES	NEW BREAK/RD	%
Complications	11	2	18.2%
No complications	360	15	4.2%

$P = .09$ Fisher's exact test.

(4.0%) experienced a new retinal break or detachment. Two hundred forty-six eyes had no YAG capsulotomy during the period of follow-up, and, of these, 12 (4.9%) experienced a new retinal break or detachment following cataract surgery. The difference in these values is not statistically significant ($P = .8$; FET) (Table XXVII). Therefore, for this study population, the data do not demonstrate a significant relationship between YAG capsulotomy and the subsequent development of new breaks or detachment following cataract surgery.

Type of Implant

The vast majority of patients in this study underwent posterior chamber lens implantation. Data regarding lens status were available in 370 of 371 eyes. Of 350 eyes that underwent posterior chamber lens implantation, 16 (4.6%) developed a new retinal break or detachment following cataract surgery. The study group included only 13 eyes that received an anterior chamber lens implant. None had a new retinal break or detachment following cataract surgery. One of seven eyes (14.3%) that was left aphakic developed a new retinal break following cataract surgery. While the data suggest that aphakia may be a risk factor for

retinal breaks or detachment following cataract surgery, no statistically significant difference was present among these three groups ($P = .37$) (FET) (Table XXVIII).

Sequential Onset of Breaks

In order to determine if eyes that underwent cataract surgery were unique in regard to the development of sequential tears, those eyes undergoing cataract surgery were compared to the entire study group. For the entire study group, 157 (7.2%) of 2,175 eyes experienced the sequential onset of a new break following the initial presenting break or detachment. A new break occurred sequentially following the initial break or detachment in 129 (7.2%) of 1,804 eyes that did not undergo subsequent cataract surgery and in 28 (7.5%) of 371 eyes that did undergo cataract surgery. There was no statistically significant difference in these values ($P = .83$). Therefore, the group of eyes that underwent subsequent cataract surgery did not differ significantly in regard to the onset of sequential retinal breaks during the time when they were phakic from the remainder of the study group.

The occurrence of new breaks sequentially after repair of the initial retinal break or detachment was noted in 157

TABLE XXVII: NEW BREAK OR RETINAL DETACHMENT FOLLOWING CATARACT SURGERY:
YAG CAPSULOTOMY

	NO. OF EYES	NEW BREAK/RD	%
Cataract surgery + YAG	125	5	4.0%
Cataract surgery without YAG	246	12	4.9%

$P = .8$ Fisher's exact test.

TABLE XXVIII: NEW BREAK OR RETINAL DETACHMENT FOLLOWING CATARACT SURGERY:
LOCATION OF IOL IMPLANT*

	PC IOL	AC IOL	APHAKE
No. of eyes	350	13	7
New break/RD	16	0	1
%	4.6%	0	14.3%

$P = .37$ Fisher's exact test.

AC anterior chamber; IOL, intraocular lens; PC, posterior chamber.

*Data available for 370 of 371 eyes.

The Risk of a New Retinal Break or Detachment Following Cataract Surgery

eyes. Of these, 28 underwent cataract surgery and 3 of 28 (10.7%) experienced a new retinal break or detachment following cataract surgery. Three hundred forty-three eyes of 2,018 that did not suffer a sequential new break following the initial break or detachment underwent cataract surgery. Of these, 14 (4.1%) of 343 developed a new retinal break or detachment following cataract surgery. Therefore, the occurrence of a sequential new break following the initial presenting retinal break or detachment treated prior to cataract surgery was associated with a 10.7% incidence of new retinal breaks or detachment following cataract surgery as compared to eyes in which sequential new breaks did not occur prior to cataract surgery, of which 4.1% subsequently developed a new retinal break or detachment following cataract extraction. While the data suggest that the occurrence of sequential new breaks while phakic may increase the risk of new breaks or detachment following cataract surgery, the numbers are too small to yield statistical significance ($P = .13$) (Table XXIX).

The median onset of a sequential new break following the primary break or detachment was 8 weeks with a range of 1 to 1,352 weeks. For eyes that had a phakic break, the median onset of a sequential new retinal break

or detachment was 6 weeks; for those with a subclinical detachment, 30 weeks; and those with a retinal detachment, 13 weeks (Table XXX). Forty percent of new-onset sequential breaks occurred within 4 weeks of the initial retinal break or detachment; 53% occurred within 8 weeks; 66% in the first 6 months; 75% in the first year; and 83% within 2 years (Table XXXI). In only 21 eyes (14%) did a sequential tear occur at three or more years after the primary retinal break or detachment.

RELATIONSHIP OF POST-CATARACT-SURGERY NEW BREAKS OR RETINAL DETACHMENT TO SEQUENTIAL ONSET OF BREAKS IN EYES REMAINING PHAKIC

A Kaplan-Meier life table analysis was performed to compare the time to break formation in eyes that had undergone cataract surgery to those that had not undergone such surgery. For the cataract surgery group the follow-up time started at the date of surgery and lasted either until a new retinal break or detachment occurred or, if there were no new breaks, until the date of the last visit. For those eyes that did not undergo cataract surgery, the follow-up time began with the date of last treatment and lasted until a new break or until the last visit.

TABLE XXIX: RISK OF NEW BREAK OR RETINAL DETACHMENT IN EYES WITH SEQUENTIAL ONSET OF NEW BREAKS AFTER PRIMARY EVENT

	NO. OF EYES	CATARACT SURGERY	POSTOP NEW BREAK/RD	%
No new break preop	2,018	343	14	4.1%
New break preop	157	28	3	10.7%
Total	2,175	371	17	4.6%

$P = .13$ Fisher's exact test.

TABLE XXX: ONSET OF SEQUENTIAL NEW BREAKS (WEEKS*) AFTER PRIMARY EVENT PRIOR TO CATARACT SURGERY

	MEDIAN
All eyes	8.0
Break	6.0
SC RD	30.0
RD	13.0

RD, retinal detachment; SC, subcapsular.

*Range, 1 to 1,352 weeks (26 years).

TABLE XXXI: ONSET OF SEQUENTIAL NEW BREAK OR RETINAL DETACHMENT AFTER PRIMARY EVENT*†

	4 WK	8 WK	12 WK	26 WK	1 YR	2 YR	3 YR
Cumulative No.	59	78	85	97	110	122	126
Cumulative %	40%	53%	58%	66%	75%	83%	86%

*Data available for 147 of 157 eyes.

†21 eyes (14%) onset >3 yr.

Of the 371 eyes that underwent cataract surgery, 331 had data on follow-up time. Seventeen of 331 (5.1%) had onset of a new break after cataract surgery. Of the 1,804 eyes that did not undergo cataract surgery, 1,794 had follow-up data. Within this group 121 of 1,796 (6.7%) developed a sequential tear.

The mean onset of retinal break formation for the 17 of 331 eyes that underwent cataract surgery was 25.8 months with a median of 17 months following cataract surgery. In comparison, the mean onset of sequential break formation for the 121 of 1,796 eyes that did not undergo cataract surgery was 15.2 months with a median of 1.8 months (Table XXXII).

A Kaplan-Meier plot shows the proportion of eyes in the two groups that developed a retinal break (Figure 4). The plot indicates that the rate of new breaks was higher in the group of eyes that developed sequential tears but remained phakic compared to the rate of post-cataract surgery breaks in operated eyes. Additionally, the plot demonstrates a shorter interval of onset of new break formation in eyes that remained phakic than in eyes that underwent cataract surgery. A log-rank test to compare the two curves indicated there was no statistical significance between these two groups ($P = .12$). However, this analysis does not ideally isolate cataract surgery as an independent risk factor.

ANALYSIS OF CATARACT SURGERY AS AN INDEPENDENT RISK FACTOR

In order to attempt to isolate the impact of cataract surgery as an independent risk factor, a second Kaplan-Meier life table analysis was performed. The median period of follow-up for eyes that underwent cataract surgery prior to such cataract surgery was 33 months. This was selected for the starting point for data analysis both for eyes having undergone cataract surgery and for those remaining phakic. Those phakic eyes followed for less than 33 months were excluded as were sequential-onset new breaks that occurred prior to 33 months. Follow-up time for these groups is shown in Table XXXIII. The values for the “no cataract surgery” group have been calculated by first subtracting the median follow-up time for the “cataract surgery” group (33 months). Only no cataract surgery eyes with a positive adjusted follow-up time are included. This results in the number of eyes in the no cataract surgery group being reduced from 1,794 to 649.

The mean onset of retinal break formation for the 17 of 331 eyes that underwent cataract surgery was 25.8 months with a median onset of 17 months following cataract surgery. In comparison, the mean onset of sequential new breaks for the 15 of 649 eyes that did not undergo cataract surgery was 61.0 months with a median of 30.5 months

TABLE XXXII: KAPLAN-MEIER ANALYSIS: TIME TO TEAR (MONTHS)

GROUP	NO. OF EYES	MEAN	SD	MEDIAN	MINIMUM	MAXIMUM
Cataract surgery	17	25.8	29.8	17.0	1.0	107.0
No cataract surgery	121	15.2	39.4	1.8	0.2	310.9

$P = .12$ log-rank test.

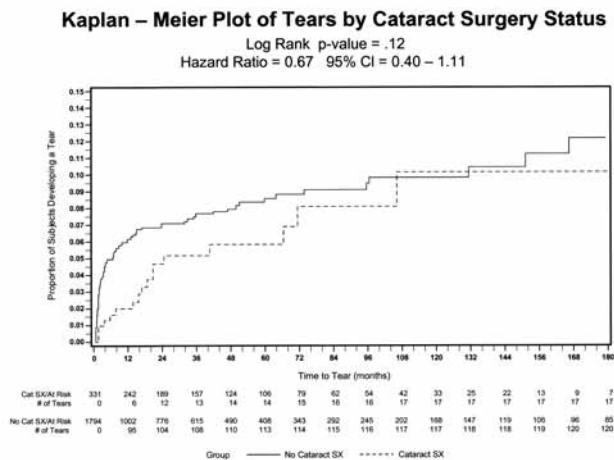


FIGURE 4

Kaplan-Meier plot showing time of onset of sequential new tear formation following initial presenting event compared to time of onset of new break or detachment following cataract surgery.

(Table XXXIV). A Kaplan-Meier plot shows the proportion of eyes in the two groups that developed a retinal break (Figure 5). The plot indicates that the rate of new breaks or detachment was higher in the group of eyes that underwent cataract surgery compared to the rate of sequential new tears in the group that remained phakic. Additionally, the plot demonstrates a shorter interval of onset of new breaks in eyes that underwent cataract surgery compared to those that remained phakic. These curves are statistically different (log-rank P value = .003). Therefore, the data demonstrate that cataract surgery as an isolated event was causally related to the onset of new retinal breaks or detachment.

FOLLOW-UP

The median follow-up for all patients in the study from the time of the last treatment of the initial presenting event to the patient's last visit was 26.4 months. For eyes

The Risk of a New Retinal Break or Detachment Following Cataract Surgery

TABLE XXXIII: FOLLOW-UP TIME (MONTHS): NO CATARACT SURGERY VERSUS CATARACT SURGERY GROUPS*

GROUP	MEAN	SD	MEDIAN	MINIMUM	MAXIMUM
No cataract surgery (n = 649)	66.4	69.9	43.0	0.0	426.0
Cataract surgery (n = 331)	48.3	49.1	33.0	0.9	258.0

*Values for the “no cataract surgery” group have been calculated by first subtracting the median follow-up time for the “cataract surgery group” (33 mo). Only “no cataract surgery” eyes with a positive adjusted follow-up time have been included. This results in the number of eyes for the “no cataract surgery” group to be reduced from 1,794 to 649.

TABLE XXXIV: TIME TO TEAR (MONTHS): NO CATARACT SURGERY VS CATARACT SURGERY GROUPS*

GROUP	MEAN	SD	MEDIAN	MINIMUM	MAXIMUM
No cataract surgery (n = 15)	61.0	73.6	30.5	1.0	277.9
Cataract surgery (n = 17)	25.8	29.8	17.0	1.0	107.0

P = .003 log-rank test.

*Follow-up time for “no cataract surgery” group adjusted by subtracting 33 months.

with a phakic retinal break the median follow-up was 25.3 months; for eyes with a subclinical retinal detachment, 26.4 months; and for those eyes with a retinal detachment as the primary event, 38.6 months (Table XXXV).

The median interval between the last treatment and cataract surgery for the entire study group was 33.5 months. For eyes that underwent repair of a phakic break the median interval prior to cataract surgery was 52.8 months. For eyes with a subclinical retinal detachment the median interval prior to cataract surgery was 37.6 months, and for those that had a retinal detachment the

median interval was 20.3 months (Table XXXVI).

The length of follow-up for eyes that underwent cataract surgery was calculated from the date of cataract surgery to the final visit. For all eyes the median follow-up was 34.5 months. For those eyes with a phakic break as the primary event prior to undergoing cataract surgery, the median follow-up was 36 months; for eyes with a subclinical retinal detachment 44.6 months; and for eyes with a retinal detachment 33 months (Table XXXVII).

The length of follow-up of eyes from date of cataract surgery to final visit was analyzed both for those that experienced a new retinal break or detachment and for those that did not. The mean length of follow-up for eyes that experienced a new break or detachment was 43.8 months with a median of 33.5 months. Eyes that did not experience a new retinal break or detachment were followed somewhat longer, with a mean follow-up of 50.2 months and a median of 35.0 months (Table XXXVIII).

The length of follow-up for eyes that had a new retinal break or detachment following cataract surgery compared to the entire group of eyes was analyzed as well. For the 17 eyes that developed a new retinal break or detachment following cataract surgery, the mean follow-up was 43.8 months with a median of 33.5 months. The mean follow-up for the remaining 2,155 eyes was 58.4 months with a median of 26.4 months (Table XXXIX).

Eyes that did develop a new break or detachment following cataract surgery were followed for an average of 16.6 months with a median follow-up of 12 months, measured from the date of developing the new retinal break or detachment to their last visit. (Table XL).

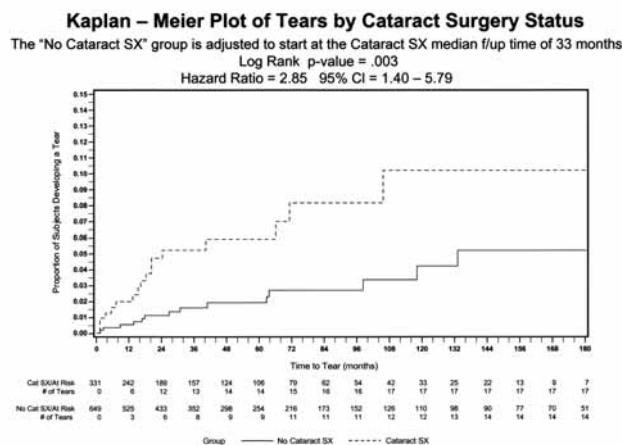


FIGURE 5

Kaplan-Meier plot of tears by cataract surgery status showing time of onset of sequential new tears following initial presenting event in eyes that remained phakic compared to time of onset of new break or detachment in eyes that underwent cataract surgery.

TABLE XXXV: LENGTH OF FOLLOW-UP (MONTHS): ENTIRE STUDY AND SUBGROUPS

	MEAN	MEDIAN	SD
Entire study	58.7	26.4	78.9
Break	55.9	25.3	76.8
SC RD	55.1	26.4	70.0
RD	73.2	38.6	93.2

RD, retinal detachment; SC, subclinical.

TABLE XXXVI: INTERVAL LAST TREATMENT TO CATARACT SURGERY (MONTHS): ENTIRE STUDY AND SUBGROUPS

	MEAN	MEDIAN	RANGE	SD
Entire study	76.3	33.5	1-455	93.0
Break	90.1	52.8	1-352	96.6
SC RD	63.9	37.6	1-310	73.9
RD	64.8	20.3	2-455	93.5

RD, retinal detachment; SC, subclinical.

$P < .08$ Kruskal-Wallis.

TABLE XXXVII: INTERVAL CATARACT SURGERY TO FINAL VISIT (MONTHS*)

	MEAN	MEDIAN	SD
Entire study	49.9	34.5	49.7
Break	49.9	36.0	49.4
SC RD	55.3	44.6	48.0
RD	47.8	33.0	50.9

$P = .30$ Kruskal-Wallis.

RD, retinal detachment; SC, subclinical.

*Range, 1-261 months (21 years).

TABLE XXXVIII: NEW BREAK OR RETINAL DETACHMENT FOLLOWING CATARACT SURGERY: LENGTH FOLLOW-UP (MONTHS) CATARACT SURGERY TO FINAL VISIT

	NO. OF EYES	MEAN	MEDIAN	SD
No new break/RD	314	50.2	35.0	50.4
New break/RD	17	43.8	33.5	34.7

$P = .85$ Kruskal-Wallis.

TABLE XXXIX: NEW BREAK OR RETINAL DETACHMENT FOLLOWING CATARACT SURGERY: LENGTH FOLLOW-UP NEW BREAK/RETINAL DETACHMENT VS REMAINDER ENTIRE GROUP*

	NO. OF EYES	MEAN	MEDIAN	SD
No new break/RD	2,155	58.4	26.4	79.0
New break/RD	17	43.8	33.5	34.7

$P = .45$ Kruskal-Wallis.

*Data available for 2,172 of 2,175 eyes.

TABLE XI: NEW BREAK OR RETINAL DETACHMENT FOLLOWING CATARACT SURGERY: LENGTH OF FOLLOW-UP ONSET OF NEW BREAK/RETINAL DETACHMENT TO FINAL VISIT

Average	16.6 mo
Median	12 mo
Range	1-63 mo

To determine if the unequal interval of follow-up (median cataract surgery eyes, 34.5 months; median non-cataract surgery eyes, 26.4 months) was responsible for a significant difference in the rate of onset of new breaks or detachments in eyes that underwent cataract surgery compared to those that did not, subjects with a follow-up or time-to-tear interval greater than 26.4 months were treated as censored at 26.4 months. Data analysis at 26.4 months showed there were 13 new breaks or retinal detachments in the cataract surgery group and 104 sequential-onset new breaks in the group that did not undergo cataract surgery. Data analysis showed that 5.2% developed tears or retinal detachment in the cataract surgery group compared to 7.1% of sequential-onset new breaks in eyes that did not undergo cataract surgery. The log-rank test comparing these groups was not significant ($P = .07$).

VISUAL RESULTS

Initial visual acuity was defined as the acuity measured at the time of the patient's presentation with the initial phakic retinal break or detachment. Initial mean visual acuity, measured as Snellen acuity and converted to decimal notation, was 0.55 (20/36) for all eyes undergoing

cataract surgery. For those eyes that developed a new retinal break or detachment following cataract surgery, the mean initial acuity was 0.41 (20/49) compared to an initial acuity of 0.55 (20/36) for eyes in which no new retinal break or detachment occurred. At the time of the final visit, mean visual acuity for all eyes undergoing cataract surgery was 0.63 (20/32); for eyes that developed a new break or detachment 0.65 (20/31); and for eyes with no new break or detachment 0.63 (20/32). The final mean and median visual acuity surpassed the initial acuity for all patients undergoing cataract surgery as well as for patients who developed a new break or detachment following cataract surgery (Table XLI).

Initial mean visual acuity calculated as logMAR for all patients undergoing cataract surgery was 0.43 compared to a mean final visual acuity of 0.28. For all eyes that developed a new retinal break or detachment following cataract surgery, the mean initial visual acuity measured as logMAR was 0.56 compared to a final visual acuity of 0.30. For those that did not develop a new retinal break or detachment following cataract surgery, the initial mean logMAR was 0.43 compared to a final of 0.28 (Table XLII).

The distribution of initial and final visual acuity for all patients undergoing cataract surgery and for those with or without new retinal break or detachment is shown in Figures 6, 7, and 8.

DISCUSSION

PART I: ETIOLOGY OF RHEGMATOGENOUS RETINAL DETACHMENT AND ASSOCIATED RISK FACTORS

On the basis of pathogenic mechanism, retinal detach-

TABLE XLI: INITIAL AND FINAL VISUAL ACUITY DECIMAL*

INITIAL VA DECIMAL					FINAL VA DECIMAL			
	NO. OF EYES	MEAN	SD	MEDIAN	NO. OF EYES	MEAN	SD	MEDIAN
Overall	370	0.55	0.31	0.50	367	0.63	0.27	0.67
No new break/RD	353	0.55	0.32	0.67	354	0.63	0.27	0.67
New break/RD	17	0.41	0.27	0.40	17	0.65	0.29	0.80

*Initial data available for 370 of 371 eyes, final data for 367 of 371 eyes.

TABLE XLII: INITIAL AND FINAL VISUAL ACUITY LOGMAR

INITIAL VA LOGMAR					FINAL VA LOGMAR			
	NO. OF EYES	MEAN	SD	MEDIAN	NO. OF EYES	MEAN	SD	MEDIAN
Cataract surgery*	370	0.43	0.51	0.30	367	0.28	0.33	0.18
No new break/RD	353	0.43	0.51	0.18	354	0.28	0.32	0.18
New break/RD	17	0.56	0.50	0.40	17	0.30	0.46	0.10

*Initial data available for 370 of 371 eyes, final data for 367 of 371 eyes.

**PERCENT DISTRIBUTION SNELLEN VISUAL ACUITY
ALL EYES WITH CATARACT SURGERY**

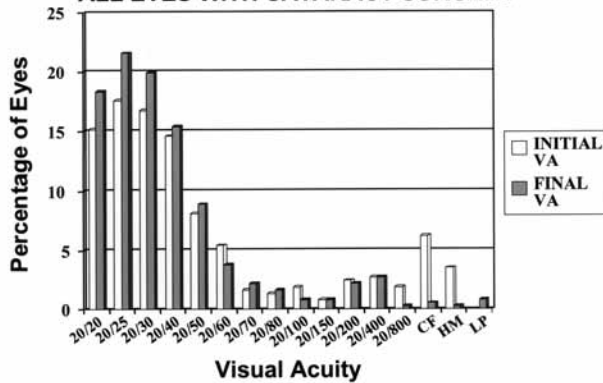


FIGURE 6

Percent distribution of Snellen visual acuity for all eyes that underwent cataract surgery. This graph compares the distribution of initial vision at the time of the presenting event to the final vision at the time of last visit after cataract surgery.

**PERCENT DISTRIBUTION SNELLEN VISUAL ACUITY
NO NEW BREAK/RD AFTER CATARACT SURGERY**

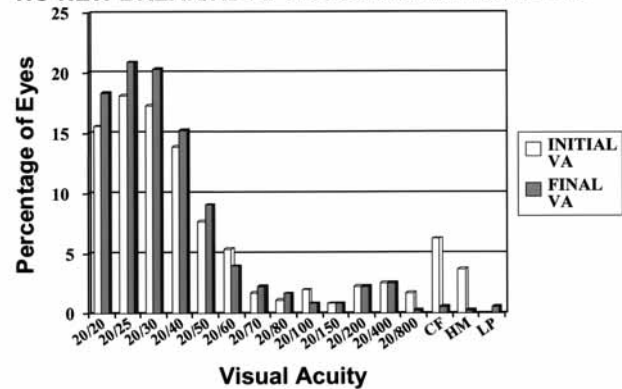


FIGURE 7

Bar graph depicts percent distribution of Snellen visual acuity in those eyes that underwent cataract surgery but did not develop a new break or detachment postoperatively. Graph shows the distribution of initial visual acuity, measured at the time of presentation with the initial event, compared to final visual acuity at the time of last follow-up visit.

**PERCENT DISTRIBUTION SNELLEN VISUAL ACUITY
NEW BREAK/RD AFTER CATARACT SURGERY**

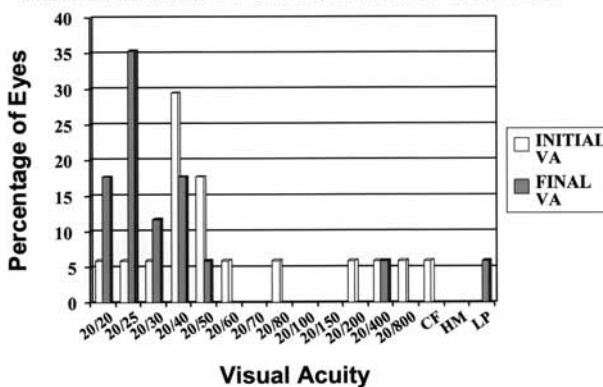


FIGURE 8

Distribution of visual acuity for those patients who develop new breaks or detachment following cataract surgery. Graph shows the distribution of vision obtained at the time of patient's initial visit with the presenting event compared to acuity at the time of final visit.

ments are broadly categorized as rhegmatogenous, exudative, tractional, or as a combination of etiologies.³⁹ Eyes in this study were limited to a rhegmatogenous etiology. Rhegmatogenous retinal detachment is the result of a combination of factors, including the development of one or more breaks in the integrity of the retina in combination with partial liquefaction of the vitreous gel.⁴⁰ Liquid vitreous in the absence of a break or the presence of a break in the absence of vitreous liquefaction is not sufficient to result in detachment. The development of a retinal break may be triggered by liquefaction of the vitreous, which leads sequentially to posterior vitreous detachment, which may then result in traction at sites of vitreoretinal adhesion, precipitating breaks in the sensory retina. In

other instances, atrophic holes unrelated to vitreous traction may be present in isolation or in association with lattice degeneration, and the retina will remain attached until liquefaction of the overlying vitreous occurs. Traumatically induced breaks, such as dialyses, occur as a consequence of a sudden avulsion of the vitreous base with associated tearing of the retina followed by progressive vitreous liquefaction that results in the gradual onset of retinal detachment.⁴¹⁻⁴³ Dialysis-related detachments may incrementally increase in size as progressively more liquefaction of vitreous develops. In fact, the degree of liquefaction limits the size of all rhegmatogenous retinal detachments regardless of the number, size, or type of the retinal breaks. Also, despite the coincident presence of both a break and liquefaction of the vitreous, and regardless of the type of break, other factors may be needed to contribute to the onset of retinal detachment, such as traction, even if subtle, at the margin of retinal breaks and/or the movement or streaming of liquid vitreous associated with eye movements.^{40,44}

Clinical experience shows us that the risk of developing a rhegmatogenous retinal detachment is related to a variety of factors. Increasing age, axial myopia, detachment in the fellow eye, family history of detachment, presence of subclinical detachment, trauma, lattice degeneration, and aphakia or pseudophakia as isolated events or in combination are factors associated with an increased risk of retinal detachment.⁴⁵ In addition, a number of hereditary entities are associated with an increased risk of retinal detachment, including Wagner-Jansen syndrome,⁴⁶ Stickler's syndrome,⁴⁷ and Marfan syndrome.⁴⁸ It is evident that liquefaction of the vitreous and vitreous detachment accompanied by peripheral vitreoretinal

traction or atrophic holes are common denominators that coexist in patients with these risk factors or hereditary syndromes.

Both clinical observation and histopathologic analysis have shown that liquefaction of the vitreous is related to age.⁴⁹⁻⁵² Eisner⁵¹ reported that clinical examination showed vitreous liquefaction to be present in 9% of patients younger than 20 years, but in 90% of patients who were 40 years of age or older. In a pathologic study, Foos and Wheeler⁴⁹ showed that the percentage of eyes with 50% vitreous liquefaction increased so that by age 70 years, more than 70% of eyes had 50% liquefaction. It remains unclear why such liquefaction occurs; however, a number of factors may play a role in its development. Prominent among these is refractive error. Myopic eyes develop vitreous liquefaction earlier in life than do emmetropic or hyperopic eyes.^{50,53,54} Liquefaction of the vitreous may occur secondary to or may be accelerated by traumatic insult to the eye, including surgical trauma.^{55,56} Intraocular inflammation following procedures such as cataract surgery and other inflammatory conditions (eg, uveitis), may be associated with liquefaction of the vitreous gel.⁵⁷ Systemic conditions, such as diabetes with associated retinopathy, appear to predispose to liquefaction and vitreous detachment at an earlier age.

The development of progressive liquefaction appears to predispose to the detachment of the posterior cortical surface of the hyaloid gel from the retina, and it is this posterior vitreous detachment which may result in tractional forces that cause retinal breaks. Studies by both Foos⁴⁹ and O'Malley⁵⁸ showed a correlation between the degree of vitreous liquefaction and the development of vitreous detachment. In a pathologic study, Foos⁴⁹ reported that increased degrees of vitreous liquefaction and increased prevalence of vitreous detachment were associated with age.

Liquefaction of the vitreous or vitreous detachment in isolation without concomitant breaks in the retina may cause visual symptoms of photopsia and floaters, but it is the presence of associated retinal breaks that allows separation of the sensory retina from the underlying retinal pigment epithelium to occur. Atrophic breaks may occur independently of vitreous detachment. However, posterior vitreous detachment has the potential to create traction at points of vitreoretinal adherence and result in retinal break formation.⁵⁹

The vitreous is normally adherent peripherally to the vitreous base and posteriorly at the margins of the optic nerve. However, the cortical vitreous may also be unusually adherent to blood vessels, to foci of prior inflammation or to zones of lattice degeneration; and traction in these areas may result in the development of retinal breaks and lead to retinal detachment.^{59,60} Most commonly

it is the adherence of the vitreous to the retina at the posterior margin of the vitreous base that precipitates breaks both in phakic or aphakic/pseudophakic eyes, leading to retinal detachment.^{61,62} Small breaks in the vitreous base are typically the cause of retinal detachment in aphakic or pseudophakic eyes. Pseudophakic as well as aphakic eyes are more likely to experience vitreous liquefaction and posterior vitreous detachment and, thus, are at increased risk of vitreous traction leading to break formation.^{55,56,61} Overall, eyes that develop a posterior vitreous detachment have a 10% to 15% incidence of retinal break formation.⁶³⁻⁶⁵ Furthermore, those eyes in which the acute posterior vitreous detachment is associated with hemorrhage can have an even greater risk of retinal tear formation.⁶³⁻⁶⁵

Axial myopia is a known precursor of retinal detachment. Several series have shown an increased incidence of retinal detachment in myopic patients.^{54,66-68} Vitreous liquefaction and posterior vitreous detachment occur earlier in life in myopic patients, and these events appear to be related to the degree of myopia.^{53,54,69} Singh and associates⁵³ found a progressively higher incidence of posterior vitreous detachment in eyes ranging from hyperopic to emmetropic to myopic, and the incidence increased further in eyes with greater than 6 D of myopia. It has long been recognized that a posterior vitreous detachment in a myopic eye is more likely to be associated with a retinal tear than a vitreous detachment in a nonmyopic eye,^{63,64} perhaps because of peripheral thinning of the retina or to associated peripheral pathology such as lattice degeneration.

Lattice degeneration is also a recognized precursor of retinal detachment.⁶⁰ While lattice degeneration may occur in emmetropic or hyperopic eyes, it is more prevalent in myopic eyes measured either by refractive error or axial length.⁷⁰⁻⁷² These studies also suggest that the prevalence of lattice increases with increasing degrees of myopia.^{70,72} Lattice degeneration is associated with two histopathologic abnormalities: zones of excavation of the retina and an unusually prominent adherence of the vitreous at the margin of the excavation.⁷³ Atrophic holes within the lattice in conjunction with vitreous liquefaction may lead to retinal detachment.

Alternatively, vitreoretinal traction at the time of vitreous detachment may result in retinal tears. Retinal breaks created in this fashion have persistent traction on their margins and, because of the presence of liquid vitreous, may rapidly lead to detachment of the retina. In an autopsy series, atrophic holes were present in 25% and marginal tears were present in 1.4% of eyes with lattice degeneration.⁷⁴ In a clinical series, Byer^{75,76} reported marginal tears in 1.5% of eyes with lattice degeneration. An indicator of the role of lattice in the development of

retinal detachment is the high frequency of lattice, occurring in 20% to 32% of eyes with retinal detachment.⁶⁰

Cataract surgery is also a recognized precursor of retinal detachment. The overall incidence of retinal detachment in phakic eyes is approximately 1 in 10,000 (0.01%); however, the rate of detachment following cataract extraction varies from approximately 0.25% to 3.6%, depending upon the type of surgery performed.⁷⁷⁻⁸¹ Alterations in the vitreous appear to be the primary factor in the development of aphakic or pseudophakic retinal detachments. Following cataract surgery there is increased liquefaction of the vitreous, which allows the presence of liquid vitreous to have access to a retinal break. In both autopsy studies and clinical series, the incidence of posterior vitreous detachment increases after surgical aphakia. Studies by Heller and associates⁸² and Foos⁸⁶ of autopsy eyes showed a dramatically higher incidence of posterior vitreous detachment in aphakic eyes. While most occurred within the first year, an increased incidence occurred with longer duration of follow-up after cataract surgery.⁸² In a series of eyes that had an extracapsular cataract procedure with an intact posterior capsule, McDonnell found a lower incidence of posterior vitreous detachment compared to eyes that had an intracapsular procedure or those in which an extracapsular procedure with capsulotomy had been performed.⁸³ There is abundant evidence from clinical studies that posterior vitreous detachment occurs more frequently in aphakic eyes than in phakic eyes. Similar studies comparing aphakia with extracapsular surgery and implantation of a posterior chamber intraocular lens do not seem to exist. Yet we know that the incidence of retinal detachment following extracapsular cataract surgery is higher than in patients left phakic and increases further after YAG laser capsulotomy.³²

Hovland's study of aphakic eyes showed that tears occur at the time of vitreous detachment and rarely occur thereafter in eyes that have already sustained a vitreous detachment.⁸⁴ Additionally, vitreous tractional forces can occur in the absence of vitreous detachment in instances such as in eyes that, following cataract surgery, have vitreous incarcerated in the wound or adherent to anterior segment structures. Subsequent contraction of the vitreous or surgical manipulation of the vitreous may result in posterior traction at sites of vitreoretinal adhesion and result in retinal break formation.⁸⁵ Alternatively, atrophic holes may predate a posterior vitreous detachment and allow retinal detachment to occur in an insidious fashion as increased amounts of liquid vitreous become available to access the retinal break.

While intracapsular cataract surgery is currently rarely performed in the United States, nevertheless patients who have undergone such surgery still present to

ophthalmologists. Alterations in the anterior hyaloid following intracapsular surgery are frequent, with rupture of the anterior hyaloid occurring in as many as 33% of eyes, often within a few weeks or months of surgery.⁸⁶⁻⁸⁹ Rupture of the anterior hyaloid may not necessarily result in posterior vitreous detachment or retinal detachment.⁹⁰ However, incarceration of the vitreous in the anterior segment surgical wound has been associated with a higher incidence of retinal detachment.⁹¹ Vitreous incarceration can also occur with a later postoperative onset, such as in eyes that develop a wound leak or wound dehiscence.

The clinical findings in eyes with pseudophakic detachments mirror those in eyes with aphakic detachments. While breaks of any size may occur, pseudophakic detachments are commonly caused by tiny breaks at the posterior aspect of the vitreous base and appear to be the result of vitreous traction at the time of posterior vitreous detachment. Hawkins⁹² showed that small retinal breaks occurred at the posterior margin of the vitreous base in the majority of aphakic retinal detachments. Eyes with pseudophakic detachments commonly have multiple small breaks and an extensive area of detachment, often including the macula, with the most frequent location of breaks in the superior half of the fundus.^{27,54,93} The study of Cousins and associates²⁷ showed that the characteristics of retinal detachments were basically similar, regardless of the location of the implant in the posterior chamber, anterior chamber, or iris-suspended. Multiple studies have demonstrated that the majority of pseudophakic retinal detachments occur in the first postoperative year, and approximately 70% occur within the first 2 years after cataract surgery.^{27,54,79,93} However, Meredith and Maumenee⁹⁴ in a series of eyes with intracapsular surgery, showed a 0.9% annual rate of retinal detachment through follow-up of 6 years. Multiple series have shown delayed onset of aphakic detachment; and in Cousins' series of eyes with pseudophakic detachments, 18% to 36% of patients, depending on the position of the intraocular lens, had onset of detachment at an interval greater than 24 months.²⁷

Posterior capsulotomy has been shown to be associated with an increased risk of pseudophakic retinal detachment.³² Wilkinson and colleagues⁹⁵ analyzed 1,500 eyes that underwent phacoemulsification and found an incidence of 3.3% of retinal detachment in those that had a primary capsulotomy. Studies by Hurite and Lempert,⁹⁶ Percival,⁹⁷ and Coonan and associates³⁰ showed an increased incidence of retinal detachment in pseudophakic eyes that underwent capsulotomy compared to those in which the capsule remained intact. The incidence was greatest in eyes that underwent primary capsulotomy.⁹⁶ Powell and coworkers⁹⁸ found a statistically significant increased incidence of retinal detachment in eyes that had

suffered capsular rupture and anterior vitrectomy at the time of extracapsular cataract surgery. Tielsch and associates⁹⁹ found the risk of retinal detachment to be 11 times higher in eyes that suffered capsular rupture at the time of extracapsular surgery.

While the advent of extracapsular surgery was associated with a decreased incidence of retinal detachment, such surgery often requires secondary capsulotomy. Currently, most secondary posterior capsulotomies are performed using the Nd:YAG laser rather than a surgical incision. In patients who have undergone an extracapsular cataract extraction with an intact capsule, the subsequent performance of Nd:YAG capsulotomy is associated with an increased risk of detachment.^{95,99,102} In contrast, maintenance of an intact posterior capsule appears to reduce the frequency of retinal detachment.^{30,31}

While the interval between capsulotomy and retinal detachment has been shown to be quite variable, many series have demonstrated that approximately 75% of detachments occur within 6 months of capsulotomy.^{101,103} However, retinal detachment has been reported to occur as long as 13 years following capsulotomy.¹⁰³ While multiple theories have been proposed to explain the development of detachment after secondary capsulotomy, including anterior displacement of the vitreous or laser disruption of the vitreous, it seems reasonable to speculate that capsulotomy renders the eye aphakic in the sense that structural changes occur in the vitreous analogous to those changes that occur in aphakic eyes and lead to posterior vitreous detachment with the potential for vitreoretinal traction and consequent retinal break formation.

While the overall incidence of detachment following secondary capsulotomy is small, nevertheless it remains an important issue, since the number of eyes that require capsulotomy is substantial. Hollick and associates¹⁰⁴ reported that posterior capsular opacification occurred in 10% to 56% of eyes undergoing extracapsular surgery with posterior chamber lens implantation, depending on the type of lens implanted. The incidence of posterior capsular opacification three years after surgery in that study was 10% for polyacrylic lenses, 40% for silicone lenses, and 56% for PMMA lenses. The percentage of eyes in which visual acuity was reduced enough to require Nd:YAG capsulotomy was 0% for eyes with a polyacrylic lens, 14% for silicone, and 26% for PMMA in this study. Similarly, Olson and Crandall¹⁰⁵ noted capsular opacification and the need for subsequent capsulotomy to be more frequent in eyes with a PMMA lens compared to those with a silicone intraocular lens. Hayashi and associates¹⁰⁶ also noted that posterior capsular opacification occurred more commonly in eyes containing a PMMA lens compared to eyes with either a silicone or an acrylic lens. Kim and colleagues¹⁰⁷ found that posterior capsular opaci-

fication occurred more rapidly in eyes with a silicone intraocular lens than in those with a PMMA lens. The development of visually significant posterior capsular opacification appears to be, in part, dependent on duration, as shown by Baratz and associates,¹⁰⁸ who noted that the frequency of Nd:YAG laser capsulotomy was 6% at 1 year following surgery and increased to 38% at 9 years following surgery.

Apple, in a histopathologic study, found that posterior capsular opacification may be related both to type of lens material and to lens design and that foldable lenses were associated with a lower frequency of capsular opacification.^{109,110} Attempts have been made to reduce the rate of capsular opacification by means of altered surgical technique, changes in lens design and material, and the use of pharmacologic agents. Yet opacification still occurs, and therefore eyes continue to require Nd:YAG capsulotomy.¹¹¹ Javitt and associates,¹¹² in an extensive review of Medicare cases, found that eyes that had undergone extracapsular cataract surgery and subsequent Nd:YAG capsulotomy had a 3.9-fold increased risk of retinal break or detachment. They concluded that because of the statistically significant increase in risk, capsulotomy should be delayed until the opacification warranted the increased risk of retinal break or detachment. In a subsequent study, Tielsch and associates⁹⁹ showed that Nd:YAG capsulotomy was associated with a significantly elevated risk of retinal detachment. Their data also demonstrated that axial length, myopia, capsular rupture during surgery and a history of retinal detachment or lattice degeneration were independent risk factors for retinal detachment.⁹⁹

Complications at the time of cataract surgery, specifically vitreous loss, result in a higher incidence of retinal detachment for eyes with surgery performed using either an intracapsular or a classic extracapsular technique.¹¹³ Bobrow¹¹⁴ reported that the rate of vitreous loss associated with phacoemulsification is lower than with standard extracapsular cataract surgery. Wilkinson and coworkers⁹⁵ reported that 14% of eyes that suffered vitreous loss at the time of phacoemulsification developed retinal detachment compared to only 3.1% of eyes that did not have vitreous loss at the time of surgery. Vitreous incarceration or loss at the time of surgery appears to be associated with posterior separation of the hyaloid and thus initiates the process of peripheral vitreoretinal traction with resultant break formation and detachment of the retina.

As previously discussed, myopic eyes, regardless of lens status, have increased liquefaction of the vitreous and a higher frequency of posterior vitreous detachment.⁵³ However, combinations of myopia and aphakia appear to be an added risk. Curtin^{66,115} and others have reported a relationship between axial myopia and retinal detachment. Jaffe⁶⁴ and others have shown an increased

frequency of retinal tears in myopic eyes that develop a posterior vitreous detachment. Perkins⁶⁸ and Cambiaggi¹¹⁶ showed a relationship between the degree of myopia and retinal detachment.

The type of surgery performed has been shown to be related to the onset of retinal detachment in myopes. In patients who have undergone an extracapsular cataract extraction with an intact capsule, the subsequent performance of Nd:YAG capsulotomy is associated with an increased risk of detachment.^{95,99-102} In contrast, maintenance of an intact posterior capsule appears to reduce the frequency of retinal detachment.^{30,31} Jaffe and associates³¹ compared the rate of retinal detachment in myopic eyes that underwent intracapsular cataract surgery without vitreous loss and found the incidence of retinal detachment to be 5.7% compared to eyes that underwent extracapsular surgery and which maintained an intact posterior capsule, for which the rate of retinal detachment was 0.7%.

There has been speculation that the implantation of an intraocular lens at the time of cataract surgery would eliminate the risk of retinal detachment in myopic eyes. Clayman and associates¹¹⁷ reported a 5% risk of detachment in eyes with axial length greater than 25 mm compared to a 0.7% risk in eyes with an axial length less than 25 mm. However, that series consisted of eyes that had undergone intracapsular surgery with implantation of an iris-supported intraocular lens. Lindstrom¹¹⁸ studied eyes that had undergone extracapsular surgery with posterior chamber lens implantation and found a 9.6% incidence of retinal detachment in myopic eyes but in none of 54 eyes without myopia.

Olson and Olson¹¹⁹ found retinal detachment to be related to axial length equal to or greater than 24 mm. Kraff and Sanders,¹²⁰ in a study of 4,329 eyes that underwent extracapsular cataract surgery with posterior chamber lens implant, found that eyes with axial myopia equal to or greater than 25 mm, were three times more likely to develop retinal detachment (3.6%) compared to eyes with axial length less than 25 mm (1.1%). Furthermore, the combination of axial myopia and an open capsule increased the risk of retinal detachment to 6.2%. However, a number of recent studies have shown a relatively low incidence of detachment following extracapsular surgery with posterior chamber lens implantation. Nissen and associates¹²¹ reported that 1.7% of patients with axial myopia of 25.5 mm or greater suffered retinal detachment after extracapsular surgery. Alldredge and colleagues¹²² reported a series of 80 eyes with 7 D or more of myopia, including 64 eyes with axial length equal to or greater than 25 mm, and found no instance of retinal detachment during a mean follow-up of 43 months. However, the extensive data of Tielsch and associates⁹⁹

showed that axial myopia was an independent risk factor for the development of retinal detachment following extracapsular surgery or phacoemulsification. In this study, myopia of greater than -4.00 D was associated with a threefold greater risk of retinal detachment than hyperopia of +2.00 D or more. The study also showed an eightfold greater risk of detachment in eyes with axial length equal to or greater than 26 mm compared to eyes with axial length less than 22 mm.

An additional risk factor for development of retinal detachment is the presence of retinal detachment in the patient's fellow eye. Benson and colleagues¹²³ reviewed 185 patients with an aphakic retinal detachment in one eye and found that the incidence of retinal detachment in the fellow phakic eye while remaining phakic was 7%. However, the second eye had a 26% incidence of retinal detachment after it became aphakic. This study clearly demonstrated that patients with an aphakic detachment in one eye were unique and that the fellow eye was at greater than expected risk of retinal detachment even if left phakic and at substantial risk if the eye became aphakic. Similar findings were reported by Folk and Burton,¹²⁴ who noted a 1.2% incidence of retinal detachment in the phakic fellow eye of patients with a unilaterally aphakic retinal detachment and a 17% risk in the second eye after it underwent cataract surgery. Smith and associates⁷⁹ reported that of 44 eyes with a pseudophakic detachment in one eye, there was a 6.9% incidence of detachment in the fellow eye. However, the status of the lens in the fellow eye was not reported. The study of Tielsch and associates⁹⁹ of eyes that had undergone extracapsular cataract surgery showed that a history of retinal detachment in either eye was an independent risk factor for the development of postoperative retinal detachment. In Smiddy's review of treated retinal breaks, treatment failure occurred at greater frequency in patients who had peripheral retinal abnormalities, such as a prior scleral buckle, lattice degeneration, or a retinal break in the fellow eye.³⁵

PART II: SEQUENTIAL ONSET OF NEW BREAKS AND NEW EVENTS FOLLOWING CATARACT SURGERY

The development of new-onset sequential retinal tears following successful repair of either a primary tear or a retinal detachment has long been recognized. New breaks have been documented to occur following both photocoagulation and cryopexy. Robertson and Norton¹²⁵ reported the onset of new breaks in 7% of patients after cryopexy and in 5% after photocoagulation, and Boniuk and associates³⁴ reported that new tears developed in 4% of eyes following cryotherapy and in 13% of eyes after photocoagulation. In a review of the natural history of retinal tears, Davis¹²⁶ found new tears in 7.5% of patients.

Goldberg⁷⁷ reported the onset of new tears in 10% of patients following cryopexy or photocoagulation. Smiddy and associates³⁵ reviewed 171 eyes treated for retinal breaks and found the onset of new breaks without detachment in 9% and a new break causing retinal detachment in an additional 5%. In that study, the risk of treatment failure was higher in aphakic or pseudophakic eyes or in those patients whose fellow eye had peripheral retinal disease, such as a prior scleral buckle, lattice, or retinal break. Rachal and Burton¹²⁷ reviewed the results of surgical repair of 1,088 eyes with a retinal detachment managed by buckling to determine the cause of failure of reattachment. In that series, 8% of failed eyes were attributed to the onset of new retinal breaks. Colyear and Pischel¹²⁸ reported that new breaks occurred in 7% of eyes following scleral buckling, and Lincoff and colleagues¹²⁹ reported an incidence of 4%.

The issue of postoperative new-onset retinal breaks became particularly important following the popularization of pneumatic retinopexy as a primary technique for repair of retinal detachment. In Hilton's report describing the first 100 cases managed by him and his colleagues, 7% of eyes developed new retinal tears following pneumatic repair.²² Dryer³⁶ reported the onset of new tears following intravitreal gas injection administered on the first postoperative day in a patient who had undergone scleral buckling. In this patient multiple new retinal tears unassociated with lattice occurred within 2 days of the gas injection, leading Dryer to theorize that movement of the bubble caused traction on the vitreous inferiorly and resulted in the formation of the breaks. Poliner and associates³⁷ reported two patients who acutely developed new retinal breaks located in the inferior quadrants in eyes following pneumatic retinopexy. Tornambe and Hilton¹³⁰ reported a multicenter trial comparing pneumatic retinopexy with scleral buckling. In that study, new retinal breaks occurred in both treatment groups, with an incidence of 13% after scleral buckling and 23% after pneumatic retinopexy. Grizzard and associates¹³¹ reviewed the cause of failure in eyes treated by pneumatic retinopexy and found the initial cause of failure to be new or missed breaks in 15% of eyes. Hilton and colleagues¹³² reviewed 26 published reports, including 1,274 eyes treated by pneumatic retinopexy, and found a 13% incidence of new breaks.

Since cataract surgery is an independent risk factor for the development of subsequent retinal detachment, it is logical to speculate that cataract surgery performed in eyes that have undergone prior treatment for either retinal breaks, subclinical detachment, or phakic detachment would be associated with increased risk of postoperative development of new peripheral retinal breaks or retinal detachment. Boniuk and associates³⁴ reviewed the use of

xenon photocoagulation and cryosurgery in 922 eyes with lattice, retinal breaks, or schisis. Of these, 24 eyes subsequently underwent cataract surgery, and 3 (13%) developed postoperative retinal detachment. Boniuk treated 367 eyes for lattice degeneration, and 2 of 10 eyes (20%) so treated that subsequently underwent cataract surgery developed retinal detachment. Of 474 eyes treated for retinal breaks, 12 underwent cataract surgery; 1 (8%) developed a postoperative retinal detachment.

During the era of intracapsular cataract surgery, Ackerman and associates¹³³ evaluated 73 eyes that had undergone cataract surgery following repair of retinal detachment. The majority of Ackerman's patients were treated with an encircling buckling element made of either silicone or polyethylene tubing. A minority of patients underwent what Ackerman described as a trap-door procedure, presumably a lamellar scleral dissection; some patients were treated with retinopexy only as the primary procedure. Ninety-three percent of the eyes remained attached during the follow-up of 6 months. In Ackerman's series, 3 of 73 eyes (4.1%) developed a recurrent retinal detachment within 1 month of cataract surgery. One was successfully repaired; however, the remaining two eyes developed proliferative vitreoretinopathy and persistent detachment. Fifty-nine percent of Ackerman's eyes experienced visual improvement following cataract surgery. In Ackerman's series of 73 cataract procedures, there was a high incidence—13 in 73 (18%)—of unplanned extracapsular cataract extraction. No lens implantations were performed. Ackerman concluded that the presence of a prior successfully repaired detachment did not preclude subsequent cataract surgery and that in patients who had successful retinal repair, cataract surgery was likely to result in visual improvement as well as to allow better visualization of the retina in order to determine the potential for recurrent retinal detachment or intrusion of buckling elements. Ackerman's data did not include refractive status of the eye, findings in the fellow eye, or the family history.

Pischel¹³⁴ and colleagues evaluated 58 eyes that had previously undergone retinal reattachment surgery and subsequently underwent intracapsular cataract extraction. In their series, 10 eyes had been managed by an encircling procedure, 17 had undergone segmental scleral resection, 27 had been treated by means of diathermy and drainage, and 2 were treated with photocoagulation alone. Intracapsular surgery was performed in most patients with the use of a cryoprobe, while 10 patients underwent forceps removal using a tumbling technique. Of the 58 eyes, 9 (16%) developed a recurrent retinal detachment. In Pischel's series, some of the recurrences consisted of a small peripheral break, manageable by means of photocoagulation, while others had a total retinal detachment.

Eight of the 9 (89%) detachments were successfully repaired, and 1 (11%) developed "vitreous retraction" and failed to reattach. The interval between cataract surgery and recurrent detachment ranged from 5 to 66 months, with an average of 57 months. Thirty-seven eyes achieved vision of 16/20 or better. In this small series of patients, Pischel noted that 5 of the 8 eyes with recurrent detachments were myopic, ranging from -6.00 to -12.00 D; and two of the recurrences developed in eyes with a history of retinal detachment in the fellow eye.

Tatapudi and colleagues¹³⁵ studied a series of 14 eyes that underwent cataract surgery following repair of retinal detachment. Twelve of 14 eyes (86%) underwent intracapsular surgery, and 2 of 14 (14%) had unplanned extracapsular cataract extraction. Tatapudi found the retina to remain attached in 9 of 14 (64%), while redetachment occurred in 5 of 14 (36%). Tatapudi reported that two of the redetachments occurred in eyes in which initial retinal repair failed but was apparently unrecognized. Two others apparently developed new tears, and one is described as developing proliferative vitreoretinopathy. In this series, Tatapudi reported that approximately 50% of patients maintained vision of 6/60 or better following cataract surgery. The series does not describe the refractive error of these patients or the presence or absence of vitreoretinal pathology in the fellow eye, nor does it report the interval of onset of detachment following cataract surgery.

In summary, in the era of intracapsular cataract surgery during which some eyes underwent unplanned extracapsular procedures, the incidence of postoperative redetachment in eyes that had undergone prior treatment of phakic retinal tears or detachment varied from 4.1% to 36%.

During the subsequent era of planned extracapsular surgery, Davison¹³⁶ reviewed his experience with a series of 3,120 extracapsular cataract extractions with posterior chamber lens implantation procedures to determine the frequency of subsequent retinal detachment. In this series, there were 47 eyes that had previously undergone repair of a phakic retinal tear (26) or detachment (21). None of these eyes developed retinal tear or detachment postoperatively following cataract surgery. In the entire series, the incidence of pseudophakic detachment or tear was 0.8% and 0.9%, respectively. Patients in this series were followed for approximately 1 year.

Smiddy and colleagues¹³⁷ described a series of 31 eyes of 27 patients who underwent extracapsular cataract surgery with (68%) or without (32%) intraocular lens implant following phakic repair of a retinal detachment by means of scleral buckling. In this series, 1 in 31 eyes (3.2%) developed a retinal detachment following cataract extraction. The investigators speculate that it may have

been chronically present and predated the cataract surgery but was unrecognized preoperatively. In this series, 85% of patients attained visual acuity of 20/40 or better. Smiddy attributed the low frequency of post-cataract retinal detachment to planned extracapsular surgical technique and theorized that a better technique of primary retinal detachment repair may also have reduced the risk of redetachment following cataract extraction. Smiddy's patients had an average interval of 121 months after repair of retinal tear or retinal detachment prior to cataract surgery; and he speculated that if spontaneous sequential tears would occur, they would have been likely to develop in that interval prior to cataract surgery. It is noteworthy that in Smiddy's series, 55% of patients were high myopes defined as myopia equal to or greater than -4.00 D. Smiddy's patients had an average follow-up of 24 months.

Ruiz and colleagues¹³⁸ reviewed the results of cataract surgery in 29 eyes of 28 patients who had undergone a previous phakic scleral buckling operation. The operative procedure included an extracapsular cataract extraction with posterior chamber lens implantation in 27 eyes and an anterior chamber implant in 2 eyes that had developed a posterior capsular tear at the time of surgery. Of these 29 eyes, 1 (3.4%) with a posterior chamber intraocular lens developed a recurrent retinal detachment. Fifty-two percent of eyes attained visual acuity of 20/40 or better. The single retinal detachment in this series occurred 15 months following cataract surgery, and another recurrence in the same eye developed 17 months later. In Ruiz's series, many patients had high risk factors for retinal detachment, including 19% who had repair of retinal detachment in the fellow eye and 59% with axial length equal to or greater than 25 mm. In this study, the mean follow-up after cataract surgery was 44 months.

Kerrison and associates¹³⁹ reviewed the results of cataract surgery performed using phacoemulsification in 47 eyes that had undergone prior scleral buckling. Forty-two of 47 eyes had a posterior chamber intraocular lens implant at the time of surgery. During a mean follow-up of 2.3 years, no patient experienced a recurrent retinal detachment. Kerrison's series included eyes with high risk factors including 13 of 47 (28%) with high myopia and 9 of 47 (19%) with detachment in the fellow eye. Final visual acuity was 20/40 or better in 72.3% of these patients. The investigators concluded that the risk of redetachment following cataract surgery with phacoemulsification is low. Eyes in this series had a mean follow-up of 2.3 years.

Eshete and colleagues¹⁴⁰ recently described 34 eyes of 32 patients that underwent phacoemulsification and lens implantation following a scleral buckling procedure. One (3%) of 34 eyes developed a new retinal break postopera-

tively. Final visual acuity equal to or greater than 20/40 was achieved in 85% of eyes, and the investigators concluded that phacoemulsification and intraocular lens implantation can be performed safely after scleral buckling surgery. However, it is noteworthy that in this series, the mean follow-up after cataract surgery was only 20 months.

In a series reported by Tielsch and associates⁹⁹ there was no statistically significant difference in the development of subsequent retinal detachment whether the type of cataract surgery was phacoemulsification or extracapsular cataract extraction. However, capsular rupture complicating cataract surgery was a significant risk factor for developing subsequent retinal detachment.⁸¹

In summary, a review of past experience reported in the literature demonstrates a paucity of data regarding the issue of risk of cataract surgery in eyes that have undergone prior successful repair of phakic break or retinal detachment. Two series provide a total of 38 eyes that underwent cataract surgery following treatment of breaks. It appears that cataract surgery for 12 of these patients was performed using an intracapsular technique, and for 26 planned extracapsular cataract surgery was employed. With regard to eyes with prior retinal detachment, a total of 145 eyes from three reported series using intracapsular or unplanned extracapsular surgery without implant of intraocular lens reveals a wide incidence of recurrent detachment ranging from 4.1% to 36%. The data are limited, and, additionally, the wide variation in frequency of postoperative breaks or detachment further limits our ability to predict risk accurately. Compiling the five small studies previously described, a total of 162 eyes with prior repair of retinal detachment that subsequently underwent cataract surgery using planned extracapsular technique with implantation of an intraocular lens have been reported. In these five small series the incidence of postoperative new breaks ranged from 0% to 3.4%.

PART III: COMPARISON OF PRESENT STUDY TO REVIEW OF LITERATURE

This current report of a single-office study significantly expands the prior literature by providing data from 371 eyes that underwent cataract surgery following successful repair of a phakic tear or detachment. These data are subdivided into 139 eyes with prior retinal detachment, 173 eyes with prior phakic break, and an additional 59 eyes with prior phakic break plus subclinical retinal detachment.

This study was conducted in a retrospective fashion and therefore is subject to some biases inherent in any retrospective review of data. Among the potential biases are those of referral and case selection. The author was solely responsible for selection of each case, applying the

exclusion criteria previously mentioned. Observer bias is minimized, as patients were initially evaluated by several retinal surgeons functioning within a group of retinal specialists. The author has attempted to verify the data by comparing notes for each examination as well as inpatient and outpatient records for each patient to determine consistency. Visual acuity was measured by technicians, eliminating bias from the investigator. Sampling errors may exist, since the study data were collected over a 10-year period, during which subtle changes in surgical technique may have occurred.

Since eyes enrolled in the study were under continued observation by the physicians of Barnes Retina Institute and/or its predecessor, Retina Consultants, Ltd, in most cases the opportunity to document cataract surgery was available either from patient history or exam at the time of the next retinal examination or by correspondence from the cataract surgeon with subsequent confirmation by examination performed by physicians in this group practice. Nevertheless, it is possible that some eyes may have undergone cataract surgery since their last retinal examination and not have been recognized or included appropriately in this statistical evaluation. Furthermore, all eyes were not examined immediately prior to cataract surgery. The preoperative status regarding the presence of retinal breaks or detachment was based on the last recorded retinal examination prior to cataract surgery. Therefore, it is conceivable that some eyes may have developed unrecognized retinal breaks or detachment prior to intervention with cataract surgery and that some of these eyes may have presented postoperatively following cataract surgery with recognizable retinal breaks or detachment arising from this preexisting pathology. It is logical to assume that such events would likely be rare and limited to asymptomatic breaks or detachments in a population selected because of prior retinal breaks, since such patients would likely be acutely aware of and report symptoms associated with new-onset vitreoretinal pathology. Unreported complications of cataract surgery also may have occurred and, while the length of follow-up in this study is significant, with longer follow-up, additional new retinal breaks or detachments might have occurred. Additionally, because the frequency of new retinal breaks or detachment is low, a rather substantial study size would be required to achieve adequate data for analysis, and thus there are limitations to statistical analyses that may be applied.

This study represents the largest collection of eyes that subsequently underwent cataract surgery after successfully repaired phakic retinal events. The data demonstrate that postoperative tears or detachments following cataract surgery occur at a higher rate in eyes that had undergone prior repair of phakic break or retinal

detachment compared to historical data describing the risk of retinal break or detachment after cataract surgery in the general population. Furthermore, the study provides statistically relevant evidence to demonstrate risk factors that may or may not predispose some eyes to develop new retinal breaks or detachment following cataract surgery.

The data presented herein are relevant to contemporary practice in that patients were treated using current techniques of planned extracapsular surgery and lens implantation. Three hundred and fifty (94%) of 371 eyes in this series had a posterior chamber implant, while only 4% had anterior chamber lens implants, and 2% were left aphakic. Despite the use of present-day techniques, this study demonstrated an incidence of 4.6% of a new retinal break or detachment following cataract surgery, greatly exceeding the incidence of retinal detachment following cataract surgery in the general population (0.9%).⁸¹ Additionally, there is consistency among the subgroups, with the incidence of retinal breaks or detachment ranging from 4.1% in patients with prior phakic breaks to 6.8% in patients with breaks and subclinical detachment. The technique of cataract surgery included posterior chamber lens implantation in 94% of eyes; however, it was not further subdivided into those that underwent extracapsular cataract extraction with expression of the nucleus versus phacoemulsification, since the data of Tielsch and associates showed no significant statistical difference in the incidence of retinal detachment related to technique of performing extracapsular surgery.⁹⁹ Data analysis shows that the median age of patients in this study—59 years—was consistent with the prior literature. Patients with previous retinal detachment were younger (median age, 53 years), and patients with prior phakic breaks older (median age, 60 years). There was no statistically significant difference in the median age of patients in the three subgroups. The distribution of age was similar in all subgroups. The median age for eyes undergoing cataract surgery was 59 years, and this was identical to the median age of the entire study population.

Eyes that developed new retinal breaks or detachment were analyzed to determine risk factors that might predispose to this outcome. There was no significant difference in age, gender, or laterality. The location of breaks posterior to the equator or the presence of vitreous hemorrhage at the time of the initial phakic event was not significant, nor was a history of prior blunt, nonpenetrating trauma or retinal detachment in the immediate family. It is interesting that the number of breaks present at the time of the initial event was not related to the development of new retinal breaks or detachment following cataract surgery, as one could speculate that larger numbers of breaks might indicate a more severe vitreo-

retinal pathologic relationship or that the risk of subtle proliferative vitreoretinopathy might be present. Additionally, one might suspect that tears associated with traction, such as horseshoe tears or horseshoe tears in lattice, could be indicative of a predisposition to future breaks. However, there was no higher risk associated with such tears. Operculated tears, presumably free of traction, had a low incidence of new retinal breaks or detachment, as did atrophic holes. While a history of trauma, per se, was not associated with a higher risk, those eyes with an initial dialysis did in fact have a higher but not statistically significant incidence of new retinal breaks or detachment following cataract extraction. For groups of eyes with breaks or breaks and subclinical detachment, the method of treatment, whether photocoagulation or cryopexy, was unrelated to the development of new retinal breaks or detachment following cataract surgery.

While this study presents the largest series of its kind to date, the final number of eyes with new retinal breaks or detachment following cataract surgery is small. Because of the scarcity of these findings and the large standard deviations seen in the data, it is difficult to demonstrate statistical significance for many of the proposed risk factors. Nevertheless, certain trends appear to be evident and may be of importance prognostically.

While measurements of axial length were not available, an attempt to quantify refractive error was made using the patient's spherical equivalent. In an attempt to reduce the impact of lens-induced myopia associated with some developing cataracts, the spherical equivalent was measured at the time of the initial presentation into the study. In this study, the data show an obvious trend toward increased degrees of myopia at initial presentation in patients who experienced new retinal breaks or detachment postoperatively. The median spherical equivalent for the entire study group was -1.00 D and for all eyes that underwent cataract surgery -1.75 D. However, for those eyes that experienced a new retinal tear or detachment postoperatively, the median presenting spherical equivalent was -3.50 D. This finding is consistent with the previous literature regarding retinal detachments in myopic, aphakic, or pseudophakic eyes.

There was, in fact, a statistically significant increased risk in patients with retinal tear or detachment in the fellow eye. This also is consistent with the literature that demonstrates a higher risk of both phakic and aphakic events in the second eye of patients with detachment in their first eye. Not all fellow eyes met the entry criteria for eligibility in the study. However, it is noteworthy that 710 (33%) of 2,175 eyes in the entire study population were in patients with bilateral disease. Yet when these eyes were examined in isolation, the frequency of new retinal breaks or detachment following cataract surgery

was virtually identical to that in eyes with unilateral involvement.

The data from this study suggest that eyes that experienced sequential onset of new breaks after treatment of the initial break or detachment are at greater risk of new retinal break or detachment following cataract surgery. Overall, in the entire study group, the sequential onset of new breaks occurred in 7.2% of eyes. This rate of sequential new tear formation is consistent with that previously reported in the literature. Twenty-eight of 157 eyes that had developed sequential new breaks underwent cataract surgery. Of these, 3 of 28 (10.7%) experienced a new retinal break or detachment following cataract surgery. In comparison, 343 eyes of 2,018 that did not experience a sequential new retinal break underwent cataract surgery and, of these, 14 of 343 (4.1%) developed a new retinal break or detachment following cataract surgery. While these numbers did not achieve statistical significance, the data suggest that eyes with the sequential development of new tears while remaining phakic have an underlying predisposition to develop new retinal breaks or detachment precipitated by the additional intervention of cataract surgery.

It is noteworthy that 2.8% of eyes with a posterior vitreous detachment (PVD) compared to 7.2% of eyes without a PVD experienced a new break or detachment following cataract surgery. Because the numbers are small, while there appears to be a trend toward an increased risk in eyes without a PVD, the difference approached but did not achieve statistical significance ($P = .07$). One could speculate that eyes that had a preexisting PVD had already experienced vitreoretinal traction related to that event and were at less future risk of such traction creating a new break than were eyes in which a PVD had not yet occurred. Those eyes without a PVD might be prone to develop a PVD following cataract surgery, and the resultant vitreoretinal traction could then precipitate the formation of a new retinal break. While this is an interesting speculation and may provide insight into the development of new breaks postoperatively, it should be remembered that the diagnosis of PVD by means of ophthalmoscopy or biomicroscopy is not always accurate.¹⁴¹ Surgical experience gained during vitrectomy in eyes undergoing attempts to repair macular abnormalities has shown the difficulty in establishing the existence of a PVD preoperatively. Eyes with an apparent Weiss ring may still have cortical vitreous attached to the retina at the time of vitrectomy surgery; as a corollary, some eyes will have complete separation of the cortical vitreous without an obvious Weiss ring on biomicroscopy. Furthermore, the extent of separation of the posterior cortical vitreous may vary considerably. Hence, these data should be interpreted with caution. It seems reasonable

to consider an attached hyaloid as a potential risk factor for postoperative new breaks or detachment, but the presence of a PVD cannot be considered to eliminate such postoperative risk based on the data from this study.

In reviewing the method of primary repair of retinal detachment, the data showed a trend toward increased risk in eyes treated with segmental buckles compared to encircling elements. This conclusion is not surprising, since encircling is designed to reduce traction at the vitreous base and since aphakic or pseudophakic eyes typically present with breaks at the vitreous base. While the database is too small to allow multivariate analysis, the data from this study also suggest that vitrectomy in combination with scleral buckling in the treatment of a primary event may be associated with a lower risk of new breaks or detachment following cataract surgery. It seems reasonable to speculate that such a surgical approach minimizes future risk of vitreoretinal traction and may therefore decrease the potential for new breaks or detachment following cataract surgery.

While only a few eyes were left aphakic, a higher percentage of these eyes developed new breaks or detachment postoperatively. While this finding was not statistically significant, it is consistent with the prior ophthalmic literature, which has shown a higher incidence of retinal detachment in aphakic eyes than in eyes that remain phakic or become pseudophakic. It seems particularly important that the risk of new break or detachment was dramatically higher (18%) in eyes that had complicated cataract surgery. This increased incidence in such eyes again is consistent with prior reports of cataract surgery in otherwise normal eyes.⁹¹

A Kaplan-Meier life table analysis was performed to compare the frequency and time of onset of a new retinal break or detachment in eyes that had undergone cataract surgery to the development of sequential new tears in those that had not undergone cataract surgery. The Kaplan-Meier life table analysis, which looked at all eyes in the study population but without matched periods of follow-up, provided data that appeared contradictory (Table XX) (Figure 4). On initial inspection, the data appeared to indicate a lower rate of new breaks or retinal detachment following cataract surgery when compared to the rate of sequential new breaks in eyes that remained phakic and, thus, suggested a "protective effect" of cataract surgery. Yet the time of onset of new breaks for the two groups was different, and this disparity suggests that cataract surgery may have played a causative role in the development of the new breaks or detachment.

Upon further analysis of these data, it is apparent that this Kaplan-Meier life table analysis was derived from data that did not allow appropriate comparison of eyes that underwent cataract surgery and those that remained

phakic, because the period of follow-up was different for these two groups.

Following repair of initial presenting phakic breaks or detachment, all eyes in this study population were at risk of sequential onset of new breaks. The group of eyes that underwent subsequent cataract surgery did not differ significantly in regard to the onset of sequential retinal breaks during the time they were phakic from the remainder of the study group ($P = .83$). For those eyes that remained phakic, all sequential new breaks were tabulated. Prior to undergoing cataract surgery, some phakic eyes also experienced the sequential onset of new breaks. However, these events were not included in the data for the initial Kaplan-Meier analysis, as those eyes were segregated into the cataract surgery group and only new retinal breaks or detachments that occurred following cataract surgery were tabulated for that group. Therefore, a number of new breaks occurring in eyes in the cataract surgery group were eliminated, since these breaks occurred following initial repair of the presenting phakic event but before the onset of cataract surgery.

In order to isolate the impact of cataract surgery as a potential risk factor, one must calculate data during a period of follow-up beginning at the same point in time for both those eyes undergoing cataract surgery and those eyes that remained phakic. Inspection of the data reveals that for eyes that underwent cataract surgery, such surgery was performed at a median interval of follow-up of 33 months following treatment of the last phakic break or detachment. Therefore, in order to make an analysis of comparable groups, the median period of follow-up prior to cataract surgery for eyes that underwent cataract surgery was selected as the starting point for data analysis for both groups. Data were collected both for eyes that remained phakic and for those undergoing cataract surgery. Those phakic eyes that had been followed for less than 33 months were therefore eliminated from the analysis, as were sequential-onset new breaks that occurred prior to 33 months of follow-up in eyes that remained phakic. The number of eyes in the no cataract surgery group changed from 1,794 to 649. These 649 eyes were then compared to the 331 eyes that subsequently underwent cataract surgery and for which follow-up data was available. Follow-up time for both groups is shown in Table XXXIII, and the time to tear in Table XXXIV. Seventeen (5.1%) of 331 eyes that underwent cataract surgery had onset of a new break or detachment following cataract surgery. Of the 649 eyes that did not undergo cataract surgery, 15 eyes (2.3%) developed a sequential tear. A Kaplan-Meier Plot (Figure 5) of these data was generated. Eyes that underwent cataract surgery had a higher frequency of onset of new retinal breaks or detachment compared to the frequency of sequential new breaks

in those eyes that remained phakic. Additionally, those new breaks or detachments following cataract surgery occurred at shorter mean or median intervals than the onset of sequential new breaks in eyes remaining phakic. These differences were statistically significant. Therefore, the data derived during a similar time of follow-up suggests that cataract surgery as an isolated event was causally related to the onset of new retinal breaks or detachment. This evidence supports the hypothesis that the development of new breaks or detachment following cataract surgery did not simply represent the expected rate of sequential onset of new breaks or retinal detachment in phakic patients but that it was related to the independent intervention of cataract surgery.

It is reassuring that visual acuity in eyes improved following cataract surgery and that, despite the need for reparative surgery, the onset of postoperative new breaks or retinal detachment did not statistically alter the likelihood of such improvement.

CONCLUSION

In summary, data from this study show that the rate of new retinal breaks or retinal detachment following cataract surgery in eyes that have previously undergone successful repair of phakic retinal break or detachment is 4.6% overall and that similar rates occurred in each of the three subgroups studied. This percentage significantly exceeds the currently reported rate of retinal detachment after cataract surgery in the overall population (0.9%).⁸¹ Furthermore, this percentage exceeds those noted in multiple prior reports containing a small number of eyes that underwent cataract surgery after repair of retinal detachment. It is noteworthy that some prior reports had a limited length of follow-up; however, eyes that underwent cataract surgery in this study were followed for a mean of 49.9 months (median, 34.5 months). While Meredith and Maumenee's⁹⁴ data indicated that in their series 50% of aphakic detachments occurred within the first year of cataract surgery, there was a 0.9% annual continued risk of retinal detachment during the follow-up interval of 6 years. Therefore, while longer follow-up may reveal additional eyes that might develop postoperative retinal breaks or detachment, the interval of follow-up achieved in this study should be sufficient to include the vast majority of such eyes.

In this study, the rate of developing new onset sequential breaks or detachment following primary repair was 7.2%, which is consistent with previously published reports. The rate of onset of phakic sequential breaks was similar both in eyes that underwent cataract surgery and in those that did not. The timing of onset of sequential

tears indicates that while there was a wide range of onset extending to greater than 3 years, more than 50% of these breaks occurred within 8 weeks of treating the primary event; 75% occurred within 1 year; and 83% within 2 years. Only 14% occurred after 3 years of follow-up.

In this study, the median interval calculated from the date of last treatment of a primary event or sequential tear to the date of cataract surgery was 33.5 months. It therefore seems reasonable to conclude that if additional new breaks or detachments would occur due to the same mechanism as that causing sequential onset of breaks while the eye remained phakic, the interval of follow-up in this study was sufficiently long for their detection prior to cataract surgery.

In this study, the 17 eyes with new breaks or detachment following cataract surgery developed these breaks or detachments at a median onset of 17 months following such surgery, with a mean of 25.8 months. Of the 17 eyes, 35% developed a new break or detachment within 1 year and 70% within 2 years of cataract surgery. The timing of such events is similar to prior published reports describing the onset of pseudophakic retinal detachment in the general population. Additionally, the late onset of some of these pseudophakic breaks or detachments is similar to previous reports. A Kaplan-Meier life table analysis shows the rate of developing new breaks or detachments and the onset of such breaks, comparing those eyes that remained phakic and those that underwent cataract surgery (Figure 5). Following cataract surgery, the rate of occurrence of new breaks or detachments exceeded and the interval of onset was shorter than that in eyes that developed sequential tears while remaining phakic. Statistical testing revealed a significant difference in these two groups ($P = .003$).

Based on this Kaplan-Meier life table analysis, it seems reasonable to conclude that in this study the new breaks or detachments that occurred following cataract surgery were different in their etiology than those new breaks that developed sequentially in eyes that remained phakic. Therefore, the data lend credibility to the hypothesis that cataract surgery is an independent risk factor for the development of new breaks or detachments in eyes that had previously undergone repair of phakic breaks or detachments.

Retinal surgeons and comprehensive ophthalmologists should be aware of the risk of postoperative new breaks or retinal detachments following cataract surgery in eyes that have undergone prior successful repair of phakic breaks or detachments. Patients need to be informed of these risks and to be instructed regarding symptoms and the need to report promptly to their comprehensive ophthalmologist or retinal surgeon should such symptoms develop. In eyes suspected of higher risk,

such as those with retinal tear or detachment in the fellow eye, sequential onset of retinal breaks, or complications of cataract surgery, it may be prudent to reevaluate the retina routinely at regular intervals postoperatively. Since careful scrutiny and possible treatment may be required postoperatively, it is reasonable to consider alterations in surgical technique of cataract extraction and lens implantation to maximize the chance of adequate pupillary size and area of clear capsule in order to facilitate retinal examination, including scrutiny of the far retinal periphery. Additionally, the implantation of an intraocular lens with a large optic and structural characteristics that facilitate and do not interfere with a vitreoretinal surgical approach would seem appropriate, should subsequent repair of retinal detachment be required.

ACKNOWLEDGMENTS

The author sincerely thanks Michael Kass MD, Robert Drews MD, and James Bobrow MD, for their inspiration, advice, encouragement, and support of this endeavor. The author gratefully acknowledges the assistance of Mae Gordon PhD, and Brad Wilson MA, who labored tirelessly in the statistical evaluation of the data. The author sincerely thanks P. Kumar Rao MD, and Daniel P. Joseph MD PhD, for their help in designing the structure of the database and for their assistance in data retrieval and analysis. The author appreciates the efforts of Debbie Kirk in retrieving and collating records, of David Yates who prepared tables and figures, and Marilyn Lavac, Deborah Shine, Carol Ann Morrow, and Carolyn Cunniff for their skill and patience in the preparation of this manuscript.

REFERENCES

1. Rucker CW. *A History of the Ophthalmoscope*. Whiting Printers, Rochester, MN, pg 17.
2. Coccus A. Uber die Auswendung des Augen-Spiegels Netzanlage eines Neuen. *Instruments*. Leipzig, Germany: Immanuel Muller; 1953:131.
3. Schepens CL. A new ophthalmoscope demonstration. *Trans Am Acad Ophthalmol Otolaryngol* 1947;51:298-301.
4. Schepens CL. Progress in detachment surgery. *Trans Am Acad Ophthalmol Otolaryngol* 1951;55:607.
5. Berliner ML. *Biomicroscopy of the Eye*. Vol 1. New York: Hoeber; 1943:14-63.
6. Duke-Elder S, Dobree JH. Detachment and folding of the retina. In: Duke-Elder S, ed. *Diseases of the Retina*. St. Louis, Mo: Mosby; 1967:772; *System of Ophthalmology*, vol 10.
7. Gonin J. The treatment of detached retina by searing the retinal tears. *Arch Ophthalmol* 1930;4:621-625.
8. Pischel DK. Detachment of the retina—its present operative treatment. *Am J Ophthalmol* 1933;16:1091-1101.

9. Pischel DK. Diathermy operation for retinal detachments; comparative results of different types of electrodes. *Trans Am Ophthalmol Soc* 1944;42:543-567.
10. Bordley WE. The scleral resection (eyeball shortening) operation. *Trans Am Ophthalmol Soc* 1949;47:462-497.
11. Hruba K. Penetrating and Lamellar scleral resection. In: Schepens CL, Regan CDJ, eds. *Controversial Aspects of the Management of Retinal Detachment*. Boston: Little, Brown & Co; 1965:91.
12. Chamlin M, Rubner K. Lamellar undermining. A preliminary report on a technique of scleral buckling for retinal detachment. *Am J Ophthalmol* 1956;41:633-638.
13. Custodis E. Scleral buckling without excision and with polyviol implant. In: Schepens CL, ed. *Importance of the Vitreous Body in Retina Surgery With Special Emphasis on Reoperations*. St Louis, Mo: Mosby; 1960:175.
14. Schepens CL. Prognosis and treatment of retinal detachment. *Am J Ophthalmol* 1953;36:1739.
15. Schepens CL. New England Ophthalmological Society 409th meeting; December 17, 1952. *Am J Ophthalmol* 1954;38:410.
16. Lincoff HA, Baras I, McLean J. Modifications to the Custodis procedure for retinal detachment. *Arch Ophthalmol* 1965;73:160-163.
17. Ohm J. Über die Behandlung der Netzhaut Absolving durch operative Entleerung der subretinden Flüssigkeit und Einspiritzung von Luft in der Glaskörper. *Arch f Ophthalmol* 1911;79:442-450.
18. Rosengren B. Über die Behandlung der Netzhautablosung mittelst Diathermie und Luftinjektion in den Glaskörper. *Acta Ophthalmol* 1938;16:3-42.
19. Rosengren B. 300 cases operated upon for retinal detachment; methods and results. *Acta Ophthalmol* 1952;30:117-122.
20. Norton EWD. Intraocular gas in the management of selected retinal detachment. *Trans Am Acad Ophthalmol Otolaryn* 1973;77:85-98.
21. Escoffery RF, Olk RJ, Grand MG. Trans pars plana vitrectomy in primary rhegmatogenous retinal detachment. *Am J Ophthalmol* 1985;99:275-281.
22. Hilton GF, Kelly NE, Salzano TC. Pneumatic retinopexy: a collaborative report of the first 100 cases. *Ophthalmology* 1987;94:307-314.
23. Cibis PA. *Vitreoretinal pathology and surgery in retinal detachment*. St Louis, Mo: Mosby; 1965:199-251.
24. Machemer R, Buettner H, Norton EWD. Vitrectomy: a pars plana approach. *Trans Am Acad Ophthalmol Otolaryngol* 1971;75:813-820.
25. Machemer R, Parel JM, Buettner H. A new concept for vitreous surgery. I. Instrumentation. *Am J Ophthalmol* 1972;73:1-7.
26. Wilkinson CP. Pseudophakic retinal detachments. *Retina* 1985;5(1):1-4.
27. Cousins S, Boniuk I, Okun E, et al. Pseudophakic retinal detachment in the presence of various IOL types. *Ophthalmology* 1986;93:198-208.
28. Isernhagen RD, Wilkinson CP. Recovery of visual acuity following the repair of pseudophakic retinal detachment. *Trans Am Ophthalmol Soc* 1988;86:291-306.
29. Michels RG, Wilkinson CP, Rice TA. *Retinal Detachment*. St Louis, Mo: Mosby; 1990:101-193.
30. Coonan P, Fung WE, Webster RG, et al. The incidence of retinal detachment following extracapsular cataract extraction. A ten-year study. *Ophthalmology* 1985;92:1096-1101.
31. Jaffe NS, Chapman HM, Jaffe MS. Retina detachment in myopic eyes after intracapsular and extracapsular cataract extraction. *Am J Ophthalmol* 1984;97:48-52.
32. Javitt JC, Tielsch JM, Canner JK, et al. National outcomes of cataract extraction: increased risk of retinal complications associated with Nd:YAG laser capsulotomy. The Cataract Patient Outcomes Research Team. *Ophthalmology* 1992;99:1487-1497.
33. Javitt JC, Street DA, Tielsch JM, et al. National outcomes of cataract extraction: retinal detachment and endophthalmitis after outpatient cataract surgery. The Cataract Patient Outcomes Research Team. *Ophthalmology* 1994;101:100-105.
34. Boniuk I, Okun E, Johnston GP, et al. Xenon photocoagulation vs cryotherapy and the prevention of retinal detachment. *Mod Probl Ophthalmol* 1974;12:81-92.
35. Smiddy WE, Flynn HW Jr, Nicholson DH, et al. Results and complications in treated retinal breaks. *Am J Ophthalmol* 1991;112:623-631.
36. Dreyer RF. Sequential retinal tears attributed to intraocular gas. *Am J Ophthalmol* 1986;102:276-278.
37. Poliner L, Grand MG, Schoch LH, et al. New retinal detachment as a complication of pneumatic retinopexy. *Ophthalmology* 1987;94:315-318.
38. SAS Institute Inc. *SAS/STAT User's Guide*, Version 8.1, Cary, NC.
39. Duke-Elder S, Dobree JH. Detachment and folding of the retina. In: Duke-Elder S, ed. *Diseases of the Retina*. St Louis, Mo: Mosby; 1967:774-775; *System of Ophthalmology*, vol 10.
40. Michels RG, Wilkinson CP, Rice TA. *Retinal Detachment*. St Louis, Mo: Mosby; 1990:464-470.
41. Cox MS, Schepens CL, Freeman HM. Retinal detachment due to ocular contusion. *Arch Ophthalmol* 1966;76:678-685.
42. Tasman W. Peripheral retinal changes following blunt trauma. *Trans Am Ophthalmol Soc* 1972;70:190-198.
43. Hagler WS, North AW. Retinal dialyses and retinal detachment. *Arch Ophthalmol* 1968;79:376-388.
44. Rosengren B, Esterlin S. Hydrodynamic effects in the vitreous space accompanying eye movements: significance for the pathogenesis of retinal detachment. *Ophthalmologica* 1976;173:513-524.
45. Michels RG, Wilkinson CP, Rice TA. *Retinal Detachment*. St Louis, Mo: Mosby; 1990:101-234.
46. Jansen LM. Degeneration hyaloideo-retinalis hereditaria. *Ophthalmologica* 1962;144:458-464.
47. Stickler GB, Belan PG, Farrell FJ. Hereditary progressive arthro-ophthalmopathy. *Mayo Clin Proc* 1965;40:433-455.
48. Maumenee IH. The eye in the Marfan syndrome. *Trans Am Ophthalmol Soc* 1981;79:684-733.
49. Foos RY, Wheeler NC. Vitreoretinal juncture. Synchysis senilis and posterior vitreous detachment. *Ophthalmology* 1982;89:1502-1512.

50. Sebag J. Aging of the vitreous. *Eye* 1987;1:254-262.
51. Eisner G. Gross anatomy of the vitreous body (author's translation). *Graefes Arch Clin Exp Ophthalmol* 1975;193:33-56.
52. Larsson L, Osterlin S. Posterior vitreous detachment. A combined clinical and physiochemical study. *Graefes Arch Clin Exp Ophthalmol* 1985;223:92-95.
53. Singh A, Paul SD, Singh K. The clinical study of the vitreous body (in emmetropia and refractive errors). *Oriental Arch Ophthalmol* 1970;8:11-17.
54. Curtin BJ. *The Myopias*. New York: Harper & Row; 1985:183.
55. Osterlin S. Vitreous changes after cataract extraction. In: Freeman HM, Hirose T, Schepens CC, eds. *Vitreous Surgery and Advances in Fundus Diagnosis and Treatment*. New York: Appleton-Century-Crofts; 1977:15.
56. Foos RY. Posterior vitreous detachment. *Trans Acad Ophthalmol Otolaryngol* 1972;76:480-497.
57. Reeser FH, Aaberg TM. Physiology of the vitreous humor. In: Records RE, ed. *Physiology of the Human Eye and Visual System*. Hagerstown, Md: Harper & Rowe; 1979:261.
58. O'Malley P. The pattern of vitreous syneresis. A study of 800 autopsy eyes. In: Irvine AR, O'Malley C, eds. *Advances in Vitreous Surgery*. Springfield, Ill: Charles C Thomas; 1976:17.
59. Sebag J. *The Vitreous: Structure, Function and Pathology*. New York: Springer-Verlag; 1989:125-131.
60. Byer NE. Lattice degeneration of the retina. *Surv Ophthalmol* 1979;23:213-248.
61. Foos RY. Vitreous base, retinal tufts, and retinal tears: pathogenetic relationships. In: Powett RC, Regan CDJ, eds. *Retina Congress*. New York: Appleton-Century-Crofts; 1974:259.
62. Sebag J. *The Vitreous: Structure, Function and Pathology*. New York: Springer-Verlag; 1989:135-138.
63. Lindner B. Acute posterior vitreous detachment and its retinal complications. A clinical biomicroscopic study. *Acta Ophthalmol Suppl* 1966;87:1-108.
64. Jaffe NS. Complications of acute posterior vitreous detachment. *Arch Ophthalmol* 1968;79:568-571.
65. Tasman WS. Posterior vitreous detachment and peripheral retinal breaks. *Trans Am Acad Ophthalmol Otolaryngol* 1968;72:217-224.
66. Schepens CL, Marden D. Data on the natural history of retinal detachment. Further characterization of certain unilateral nontraumatic cases. *Am J Ophthalmol* 1966;61:213-226.
67. Bohringer HR. Statistisches zu Haufigkeit und Risiko der Netzhautablosung. *Ophthalmologica* 1956;131:331-334.
68. Perkins ES. Morbidity from myopia. *Sightsav Rev* 1979;49:11-19.
69. Goldmann H. The diagnostic value of biomicroscopy of the posterior parts of the eye. *Br J Ophthalmol* 1961;45:449-460.
70. Karlin DB, Curtin BJ. Axial length measurements and peripheral fundus changes in the myopic eye. In: Pruett RC, Regan CDJ, eds. *Retina Congress*. New York: Appleton-Century-Crofts; 1974:629.
71. Hyams SW, Newmann E. Peripheral retina in myopia; with particular reference to retinal breaks. *Am J Ophthalmol* 1969;53:300-306.
72. Cambiaggi A. Research on the role of myopic chorioretinal changes in the pathogenesis of retinal detachment. *Ophthalmologica* 1968;156:124-132.
73. Schepens CL. Diagnostic and prognostic factors as found in preoperative examination. *Trans Am Acad Ophthalmol Otolaryngol* 1952;56:398-418.
74. Straatsma BR, Ziegen PD, Foos RY, et al. Lattice degeneration of the retina. *Trans Am Acad Ophthalmol Otolaryngol* 1974;78:OP87-113.
75. Byer NE. Clinical study of lattice degeneration of the retina. *Trans Am Acad Ophthalmol Otolaryngol* 1965;69:1064-1081.
76. Byer NE. Changes in and prognosis of lattice degeneration of the retina. *Trans Am Acad Ophthalmol Otolaryngol* 1974;78:OP114-125.
77. Goldberg MF. Clear lens extraction for axial myopia. An appraisal. *Ophthalmology* 1987;94:571-582.
78. Kelley JS, Doxanas MT. Retinal detachment following cataract surgery with capsulorhexis. *Trans Am Ophthalmol Soc* 1995;93:391-397.
79. Smith PW, Stark WJ, Maumenee AE, et al. Retinal detachment after extracapsular cataract extraction with posterior chamber intraocular lens. *Ophthalmology* 1987;94:495-504.
80. Nielsen NE, Naeser K. Epidemiology of retinal detachment following extracapsular cataract extraction: a follow-up study with an analysis of risk factors. *J Cataract Refract Surg* 1993;19(6):675-680.
81. Javitt JC, Vitale S, Conner JK, et al. National outcomes of cataract extraction. I. Retinal detachment after inpatient surgery. *Ophthalmology* 1991;98:895-902.
82. Heller MD, Straatsma BR, Foos RY. Detachment of the posterior vitreous in phakic eyes and aphakic eyes. *Modern Probl Ophthalmol* 1972;10:23-36.
83. McDonnell DJ, Patel A, Green WR. Comparison of intracapsular and extracapsular cataract surgery: histopathologic study of eyes obtained postmortem. *Ophthalmology* 1985;92:1208-1225.
84. Hovland KR. Vitreous findings in fellow eyes of aphakic retinal detachment. *Am J Ophthalmol* 1978;86:350-353.
85. McDonnell PJ, de la Cruz FC, Green WR. Vitreous incarceration complicating cataract surgery: a light and electron microscopic study. *Ophthalmology* 1986;93:247-253.
86. Harrington DO. Late changes in the vitreous following uncomplicated intracapsular cataract extraction. *Am J Ophthalmol* 1952;35:1177-1184.
87. Irvine SR. A newly defined vitreous syndrome following cataract surgery. Interpreted according to recent concepts of the structure of the vitreous. *Am J Ophthalmol* 1953;36:599-619.
88. Kirsch RE, Steinman W. Spontaneous rupture of the anterior hyaloid membrane following intracapsular cataract surgery. *Am J Ophthalmol* 1954;37:657-665.
89. Jaffe NS, Light DS. Vitreous changes produced by cataract surgery: a study of 1,058 aphakic eyes. *Arch Ophthalmol* 1966;76:541-553.

90. Friedman Z, Newmann E. Posterior vitreous detachment after cataract surgery in non-myopic eyes and the resulting retinal lesions. *Br J Ophthalmol* 1975;59:451-454.
91. Norton EW, Machemer R. New approach to the treatment of selected retinal detachments secondary to vitreous loss at cataract surgery. *Am J Ophthalmol* 1971;72:705-707.
92. Hawkins WR. Aphakic retinal detachment. *Ophthalmic Surg* 1975;6:66-74.
93. Ho PC, Tolentino FI. Pseudophakic retinal detachment: surgical success rate with various types of IOLs. *Ophthalmology* 1984;91:847-852.
94. Meredith TA, Maumenee AE. A review of one thousand cases of intracapsular cataract extractions: I: complications. *Ophthalmic Surg* 1979;10:32-41.
95. Wilkinson CP, Andersen, LS, Little JH. Retinal detachment following phacoemulsification. *Ophthalmology* 1978;85:151-156.
96. Hurite FG, Lempert SL. Intracapsular intraocular lenses and extracapsular cataract surgery. *Int Ophthalmol Clin* 1982;22:103-133.
97. Percival SP. Long term complications from extracapsular cataract surgery. *Trans Ophthalmol Soc UK* 1985;104:915-918.
98. Powell SK, Olson RJ. Incidence of retinal detachment after cataract surgery and neodymium: YAG laser capsulotomy. *J Cataract Refract Surg* 1965;21:132-135.
99. Tielsch JM, Legro MW, Cassard SD, et al. Risk factors for retinal detachment after cataract surgery. A population-based case-control study. *Ophthalmology* 1996;103:1537-1545.
100. McPherson AR, O'Malley RE, Bravo J. Retinal detachment following late posterior capsulotomy. *Am J Ophthalmol* 1983;95:593-597.
101. Winslow RL, Taylor BC. Retinal complications following YAG laser capsulotomy. *Ophthalmology* 1985;92:785-789.
102. Ober RR, Wilkinson CP, Fiore JV, et al. Rhegmatogenous retinal detachment after neodymium-YAG laser capsulotomy in phakic and pseudophakic eyes. *Am J Ophthalmol* 1986;101:81-89.
103. Ficker LA, Vickers S, Capon MR, et al. Retinal detachment following Nd:YAG posterior capsulotomy. *Eye* 1987;1:86-89.
104. Hollick EJ, Spalton DJ, Ursell PG. The effect of polymethylmethacrylate silicone and polyacrylic intraocular lenses on posterior capsular opacification three years after cataract surgery. *Ophthalmology* 1999;106:49-54.
105. Olson RJ, Crandall AS. Silicone versus polymethylmethacrylate intraocular lenses with regard to capsular opacification. *Ophthalmic Surg Lasers* 1998;29:55-58.
106. Hayashi H, Hayashi K, Nakao F, et al. Quantitative comparison of posterior capsule opacification after polymethylmethacrylate, silicone, and soft acrylic lens implantation. *Arch Ophthalmol* 1998;116:1579-1582.
107. Kim MJ, Lee HY, Joo CK. Posterior capsule opacification in eyes with silicone or polymethylmethacrylate intraocular lens. *J Cataract Refract Surg* 1999;25:251-255.
108. Baratz KH, Cook BE, Hodge DO. Probability of Nd:YAG laser capsulotomy after cataract surgery in Olmstead County, Minnesota. *Am J Ophthalmol* 2001;131:161-166.
109. Apple DJ, Peng O, Visessook N, et al. Eradication of posterior capsule opacification: documentation of a marked decrease in Nd:YAG laser posterior capsulotomy rates noted in an analysis of 5,416 pseudophakic human eyes obtained postmortem. *Ophthalmology* 2001;108:505-518.
110. Apple DJ. Influence of intraocular lens material and design on postoperative intracapsular cellular reactivity. *Trans Am Ophthalmol Soc* 2000;98:257-283.
111. Flach AJ, Dolan BJ. Incidence of postoperative posterior capsular opacification following treatment with diclofenac 0.1% and ketorolac 0.5% ophthalmic solutions: three-year randomized, double-masked, prospective clinical investigation. *Trans Am Ophthalmol Soc* 2000;98:101-105.
112. Javitt JC, Tielsch JM, Canner JK, et al. National outcomes of cataract extraction: increased risk of retinal complications associated with Nd:YAG laser capsulotomy. *Ophthalmology* 1992;99:1487-1497.
113. Vail D. After-results of vitreous loss. *Am J Ophthalmol* 1965;59:573-586.
114. Bobrow JC. Visual outcomes after anterior vitrectomy: comparison of ECCE and phacoemulsification. *Trans Am Ophthalmol Soc* 1999;97:281-295.
115. Curtin BJ. *The Myopias*. New York: Harper & Rowe; 1985:337.
116. Cambiaggi A. Myopia and retinal detachment. Statistical study of some of their relationships. *Am J Ophthalmol* 1964;58:642-650.
117. Clayman HM, Jaffe NS, Light DS, et al. Intraocular lenses, axial length and retinal detachment. *Am J Ophthalmol* 1981;92:778-780.
118. Lindstrom RL. Retinal detachment in axial myopia. *Dev Ophthalmol* 1987;14:37-41.
119. Olson G, Olson RJ. Update on a long-term prospective study of capsulotomy and retinal detachment rates after cataract surgery. *J Cataract Refract Surg* 2000;26:1017-1021.
120. Kraff MC, Sanders DR. Incidence of retinal detachment following posterior chamber intraocular lens surgery. *J Cataract Refract Surg* 1990;16:477-480.
121. Nissen KR, Fuchs J, Goldschmidt E, et al. Retinal detachment after cataract surgery in myopic eyes. *J Cataract Refract Surg* 1998;24:772-776.
122. Alldredge CD, Elkins B, Alldredge OC Jr. Retinal detachment following phacoemulsification in highly myopic cataract patients. *J Cataract Refract Surg* 1998;24:777-780.
123. Benson WE, Grand MG, Okum E. Aphakic retinal detachment. Management of the fellow eye. *Arch Ophthalmol* 1975;93:245-249.
124. Folk JC, Burton TC. Bilateral aphakic retinal detachment. *Retina* 1983;3:1-6.
125. Robertson DM, Norton EW. Causes of failure in prophylactic treatment of retinal breaks. *Modern Probl Ophthalmol* 1974;12:74-80.
126. Davis MD. The natural history of retinal breaks without detachment. *Trans Am Ophthalmol Soc* 1973;71:343-372.
127. Rachal WF, Burton TC. Changing concepts of failures after retinal detachment surgery. *Arch Ophthalmol* 1979;97:480-483.
128. Colyear BH, Pischel DK. Causes of failure in retinal detachment surgery. *Arch Ophthalmol* 1956;56:274-281.

129. Lincoff H, Kreissig I, Goldbaum M. Causes of failure in retinal detachment and prophylactic retinal detachment surgery. Reasons for failure in nondrainage operations. *Modern Probl Ophthalmol* 1974;12:40-48.
130. Tornambe PE, Hilton GF. Pneumatic retinopexy. A multicenter, randomized, controlled clinical trial comparing pneumatic retinopexy with scleral buckling. The Retinal Detachment Study Group. *Ophthalmology* 1989;96:772-783.
131. Grizzard WS, Hilton GF, Hammer ME, et al. Pneumatic retinopexy failures. Cause, prevention, timing and management. *Ophthalmology* 1995;102:929-936.
132. Hilton GF, Tornambe PE, Brinton DA, et al. The complications of pneumatic retinopexy. *Trans Am Ophthalmol Soc* 1990;88:191-207.
133. Ackerman AL, Seelenfreund MH, Freeman HM, et al. Cataract extraction following retinal detachment surgery. *Arch Ophthalmol* 1970;84:41-44.
134. Pischel DK, Atkins RE, Roth FD. Results in cataract surgery after retinal detachment surgery. *Modern Probl Ophthalmol* 1977;18:489-493.
135. Tatapudi S, Abraham ML, Badrinath SS. Cataract extraction after retinal detachment surgery. *Indian J Ophthalmol* 1981;29:455-458.
136. Davison JA. Retinal tears and detachments after extracapsular cataract surgery. *J Cataract Refract Surg* 1988;14:624-632.
137. Smiddy WE, Michels RG, Stark WJ, et al. Cataract surgery after retinal detachment surgery. *Ophthalmology* 1988;95:3-7.
138. Ruiz RS, Saatci OA. Extracapsular cataract extraction with intraocular lens implantation after scleral buckling surgery. *Am J Ophthalmol* 1991;111:174-178.
139. Kerrison JB, Marsh M, Stark WJ, et al. Phacoemulsification after retinal detachment surgery. *Ophthalmology* 1996;103:216-219.
140. Eshete A, Bergwerk KL, Masket S, et al. Phacoemulsification and lens implantation after scleral buckling surgery. *Am J Ophthalmol* 2000;129:286-290.
141. Green WR, Sebag J. Vitreoretinal interface. In: Ryan SJ, ed. *Retina*. St Louis, Mo: Mosby;2000:1909.

