

2016

Natriuretic peptide receptor-C is up-regulated in the intima of advanced carotid artery atherosclerosis

Mohamed A. Zayed
Washington University School of Medicine in St. Louis

Scott D. Harring
Washington University School of Medicine in St. Louis

Dana R. Abendschein
Washington University School of Medicine in St. Louis

Chandu Vemuri
Washington University School of Medicine in St. Louis

Dongsi Lu
Washington University School of Medicine in St. Louis

See next page for additional authors

Follow this and additional works at: https://digitalcommons.wustl.edu/open_access_pubs

Please let us know how this document benefits you.

Recommended Citation

Zayed, Mohamed A.; Harring, Scott D.; Abendschein, Dana R.; Vemuri, Chandu; Lu, Dongsi; Detering, Lisa; Liu, Yongjian; and Woodard, Pamela K., "Natriuretic peptide receptor-C is up-regulated in the intima of advanced carotid artery atherosclerosis." *Journal of Medical & Surgical Pathology*. 1, 3. pii. 131. (2016). https://digitalcommons.wustl.edu/open_access_pubs/5772

This Open Access Publication is brought to you for free and open access by Digital Commons@Becker. It has been accepted for inclusion in Open Access Publications by an authorized administrator of Digital Commons@Becker. For more information, please contact vanam@wustl.edu.

Authors

Mohamed A. Zayed, Scott D. Haring, Dana R. Abendschein, Chandu Vemuri, Dongsu Lu, Lisa Detering, Yongjian Liu, and Pamela K. Woodard

Natriuretic Peptide Receptor-C is Up-Regulated in the Intima of Advanced Carotid Artery Atherosclerosis

Mohamed A Zayed¹, Scott D Haring², Dana R Abendschein³, Chandu Vemuri¹, Dongsi Lu⁴, Lisa Detering², Yongjian Liu² and Pamela K Woodard^{2*}

¹Department of Surgery, Section of Vascular Surgery, Washington University School of Medicine, USA and Department of Surgery, Veterans Affairs St. Louis Health Care System, USA

²Mallinckrodt Institute of Radiology, Washington University School of Medicine, USA

³Center for Cardiovascular Research, Department of Internal Medicine, Washington University School of Medicine, USA

⁴Department of Pathology and Immunology, Washington University School of Medicine, USA

*Corresponding author: Pamela K Woodard, Mallinckrodt Institute of Radiology, Washington University School of Medicine, 510 S. Kingshighway Blvd, St. Louis, MO 63110, USA, Tel: (314) 362-7697; Fax: (314) 747-3882; E-mail: woodardp@mir.wustl.edu

Received date: May 23, 2016; Accepted date: June 29, 2016; Published date: July 05, 2016

Copyright: © 2016 Zayed MA, et al. This is an open-access article distributed under the terms of the Creative Commons Attribution License, which permits unrestricted use, distribution, and reproduction in any medium, provided the original author and source are credited.

Abstract

Objective: Natriuretic peptide receptor-C (NPR-C/NPR-3) is a cell surface protein involved in vascular remodelling that is up-regulated in atherosclerosis. NPR-C expression has not been well characterized in human carotid artery occlusive lesions. We hypothesized that NPR-C expression correlates with intimal features of vulnerable atherosclerotic carotid artery plaque.

Methods: To test this hypothesis, we evaluated NPR-C expression by immunohistochemistry (IHC) in carotid endarterectomy (CEA) specimens isolated from 18 patients. The grade, location, and co-localization of NPR-C in CEA specimens were evaluated using two tissue analysis techniques.

Results: Relative to minimally diseased CEA specimens, we observed avid NPR-C tissue staining in the intima of maximally diseased CEA specimens (65%; $p=0.06$). Specifically, maximally diseased CEA specimens demonstrated increased NPR-C expression in the superficial intima (61%, $p=0.17$), and deep intima (138% increase; $p=0.05$). In the superficial intima, NPR-C expression significantly co-localized with vascular smooth muscle cells (VSMCs) and macrophages. The intensity of NPR-C expression was also higher in the superficial intima plaque shoulder and cap regions, and significantly correlated with atheroma and fibroatheroma vulnerable plaque regions ($\beta=1.04$, 95% CI=0.46, 1.64).

Conclusion: These findings demonstrate significant NPR-C expression in the intima of advanced carotid artery plaques. Furthermore, NPR-C expression was higher in vulnerable carotid plaque intimal regions, and correlate with features of advanced disease. Our findings suggest that NPR-C may serve as a potential biomarker for carotid plaque vulnerability and progression, in patients with advanced carotid artery occlusive disease.

Keywords: Natriuretic peptide receptor-C; Carotid; Atherosclerosis; Arterial intima; Plaque biomarker; Plaque vulnerability; Stroke

Introduction

Nearly 20% of all ischemic strokes result from an atherosclerotic embolic source located at the extra-cranial carotid artery bifurcation in the mid-neck region [1]. More than 95% of patients with high-grade atherosclerotic carotid artery stenosis are asymptomatic [2-4]. It is unclear what subset of patients have a vulnerable atherosclerotic carotid lesion that can lead to a stroke [4,5]. This is a significant diagnostic and management dilemma, and to date there are no molecular markers of carotid atherosclerotic disease progression that could help identify higher risk patients that may benefit from early clinical intervention [6].

Natriuretic peptide receptor-C (NPR-C; NPR3), and its ligand C-type natriuretic peptide (CNP), are expressed in the vasculature [7,8], and are involved in cellular proliferation [9,10], migration [11], and vascular remodeling [12]. Following ligand binding, NPR-C activates

cell signal transduction via guanine nucleotide regulatory protein activation and downstream MAP kinase and phospholipase-C signaling [13,14]. These pathways affect a wide variety of cell specific functions such as vascular smooth muscle cell (VSMC) hyperpolarization and relaxation [15], and inhibition of L-type calcium currents in cardiac myocytes [16]. These findings thereby implicate NPR-C in the regulation of vascular homeostatic functions and potentiation of atherosclerotic disease.

Previously, NPR-C was identified to be highly expressed by neointimal VSMCs in fibroatheromatous coronary plaques [17], and VSMCs in coronary atherectomy specimens [12]. In these studies, as well as others, the expression of NPR-C and its ligand CNP appear to correlate with the severity of atherosclerotic disease [8,18,19]. Histopathology and gene expression analysis of coronary artery atheromas further demonstrate that NPR-C expression is highest in the intima and inner media layers of intermediate plaques [9,12,17]. A recent study also observed NPR-C expression in carotid artery media [20]. However, it remains unclear whether NPR-C expression is also altered in the carotid artery intima, and whether its expression pattern

correlates with features of advanced carotid artery atherosclerotic occlusive disease. We hypothesized that similar to the coronary vasculature [8,17], and carotid media [20], NPR-C expression is increased in the carotid intima of advanced atheromas, and correlates with features of plaque vulnerability. To test this, we evaluated NPR-C expression by immunohistochemistry (IHC) in maximally and minimally diseased carotid endarterectomy (CEA) plaque specimens. Masked observation and statistical modeling was used to determine whether NPR-C expression correlates with plaque intima depth, intimal cell-type, and severity and morphology of carotid atheroma.

Methods

Patients

Eighteen patients with high-grade, >70% stenosis, of the proximal internal carotid artery underwent an open surgical CEA procedure at Washington University School of Medicine-affiliated Barnes-Jewish Hospital. Patient demographics are reviewed in Table 1. Patient CEA plaque was removed en-bloc from the extra-cranial carotid artery bifurcation in the operating room. Specimens were obtained for subsequent analysis under an Institutional Review Board-approved vascular surgery tissue banking protocol.

Demographic		% (n)
Age	<50	11 (2)
	50-60	38 (7)
	61-70	16 (3)
	71-80	33 (6)
Gender, Female		11 (2)
Diabetic		33 (6)

Table 1: Basic patient demographics.

CEA tissue processing

CEA specimens were transported immediately following excision to the laboratory for analysis using two different gross sectioning techniques. In five CEA specimens, the plaque was divided into segments of either gross maximal disease (typically the segment of plaque at the carotid bifurcation), and gross minimal disease (the segment of plaque at the distal CEA edge of the internal carotid artery). In the remaining 13 CEA specimens, gross sections were obtained at 2-3 mm transverse intervals, and the segments with the greatest bulk of disease were selected from each patient for further analysis.

All plaque segments harvested for analysis were fixed in 10% formaldehyde/0.1 M PBS (pH 7.4) for 3 hours, and dehydrated in a series of graded alcohol washes. Following standard paraffin embedding, 5 µm tissue sections were cut and several sections were collected in serial 200 µm steps for immunohistochemistry (IHC) as well as staining with hematoxylin and eosin (H&E) or Verhoeff van Gieson (VVG) elastin stain.

CEA plaque IHC for NPR-C

Antigen retrieval was performed by treating CEA sample sections with 1 mM EDTA at 95°C for 10 min followed by 15 min in 1% H₂O₂ in PBS to quench endogenous peroxidase activity. Samples were then blocked with 2% goat serum in PBS for 20 min at room temperature and incubated with a primary anti-human NPR-C antibody (ab97389, Abcam, Cambridge, MA) diluted 1:1000 in PBS containing 0.05% Tween 20 and 1% goat serum overnight at 4°C. Avidin/Biotin blocking was incorporated into the serum block and primary antibody steps following manufacturer instructions (Vector Laboratories, Burlingame, CA). The sections were then incubated with a biotinylated goat anti-rabbit secondary antibody at a 1:200 dilution (Vector Laboratories, Burlingame, CA) in PBS containing 0.05% Tween 20 for 30 min followed by ABC reagent (Vector Laboratories, Burlingame, CA) for 30 min. Vector DAB substrate was used for staining sections for 60 sec. Control sections with only 1% goat serum in place of the primary antibody were run concurrently with the NPR-C stained slides. An additional negative control using polyclonal rabbit IgG antibody diluted to the same concentration as the diluted rabbit anti-human NPR-C primary antibody (1 µg/ml) was also used.

IHC for NPR-C co-localization with VSMCs and macrophages

Co-localization assessments of NPR-C tissue expression and intra-plaque VSMCs and macrophages were performed according to the manufacturer instructions for multiple antigen labeling and staining. Sections were first stained for NPR-C with DAB as described above. In the same tissue sections, VSMCs were then labeled using a 1:750 dilution of anti-α-actin primary antibody (clone 1A4, Sigma-Aldrich, St. Louis, MO) for 30 min at room temperature. Macrophages were labeled using a 1:100 dilution of anti-human macrophage CD68 primary antibody (clone KP1, Abcam, Cambridge, MA). A biotinylated secondary antibody kit containing alkaline phosphatase (Vectastain ABC-AP mouse IgG, AK-5002, Vector Laboratories; Burlingame, CA) was used to counter-stain immuno-labeled VSMCs and macrophages.

CEA specimen histology

Representative H&E and VVG stained sections were obtained from the same CEA specimens that underwent NPR-C IHC. A separate panel of two pathologists and one vascular biologist, blinded to the NPR-C scoring (see below), graded tissue sections according to the American Heart Association (AHA) classification for atherosclerosis, I) intimal thickening, II) fatty streak, III) preatheroma, IV) atheroma, and V) fibroatheroma [21]. AHA grade VI (complicated lesion due to fissure, hemorrhage, or thrombus) was excluded since it was not possible to rule out whether these plaque features resulted from plaque manipulation during the endarterectomy procedure. Features that can influence plaque vulnerability (plaque shoulder inflammation and plaque calcification) were also evaluated [22,23].

Grading of NPR-C IHC

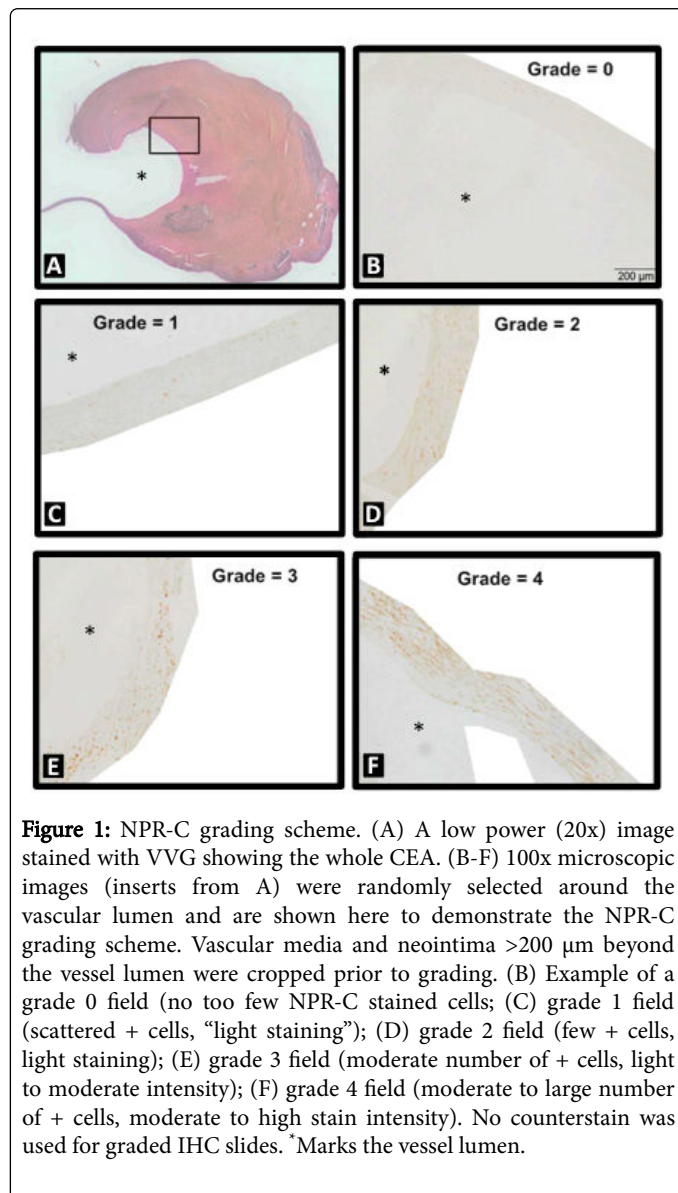
Expression of NPR-C in CEA specimens was analyzed using two IHC grading techniques. For the five CEA specimens stratified by gross maximal and minimal disease, a panel of blinded experts graded NPR-C tissue staining. Five 100X random fields were randomly selected in the superficial intima (intima <200 µm depth from the vessel lumen), deep intima (intima >200 µm depth from the vessel lumen) [24] and

media of the specimens. NPR-C positive cells were counted in each field, and an average was derived for the five fields analyzed.

For the remaining 13 CEA specimens, tissue sections were analyzed in a blinded cross-over fashion with one panel of experts grading NPR-C expression, and a separate panel that is blinded to NPR-C scoring grading the severity of atherosclerosis as described above.

Intima NPR-C tissue-staining intensity was graded from 0 to 4 using a standardized scoring scale (Figure 1). A total of 54 sections were graded from specimens of different AHA grade atheroma's (I=3, II=2, III=8, IV=1 and V=39).

Depending on the CEA lumen size, each plaque section required 4 to 20, 100x images to encircle the entire vessel lumen for a corresponding total of 493 analyzed images. The internal elastic lamina was localized with VVG staining, and was used to guide NPR-C assessments in the CEA superficial and deep intima.



Data and statistical analysis

Mean NPR-C expression scores were derived from the analyses of blinded observers. For plaque atheromas and fibroatheromas (AHA grades IV and V), NPR-C expression scores were derived at the plaque shoulder and cap.

Statistical analyses were performed using SPSS software (Chicago, IL). Linear regression analysis was used to determine the relationship between mean NPR-C grade and plaque pathologic features of interest (presence of atheroma/fibroatheroma, plaque hemorrhage/rupture, shoulder inflammation, calcification within 400 μm of vessel lumen, plaque cellularity, etc.).

Model explanatory power was assessed using adjusted R-squared for both models. We used adjusted Cohen's Kappa to assess the inter-rater reliability of the IHC grading panel. Agreement was defined as ± 1 point on the 0 to 4 grading scheme. An alpha of 0.05 was used for all tests of significance (P<0.05).

Results

Correlation of NPR-C expression with extent of carotid artery disease

We initially evaluated NPR-C expression in maximally and minimally diseased CEA specimens in a cohort of 5 patients (mean age 68.8 years, 4 male) who were non-diabetic and had high-grade asymptomatic carotid artery stenosis.

Consistent with prior findings [20] whole-mount IHC demonstrated avid and diffuse NPR-C staining in maximally diseased CEA specimens (Figures 2A-2D). Relative to minimally diseased segments, maximally diseased segments had an overall 65% increase in NPR-C tissue staining (p=0.06; Figure 2D).

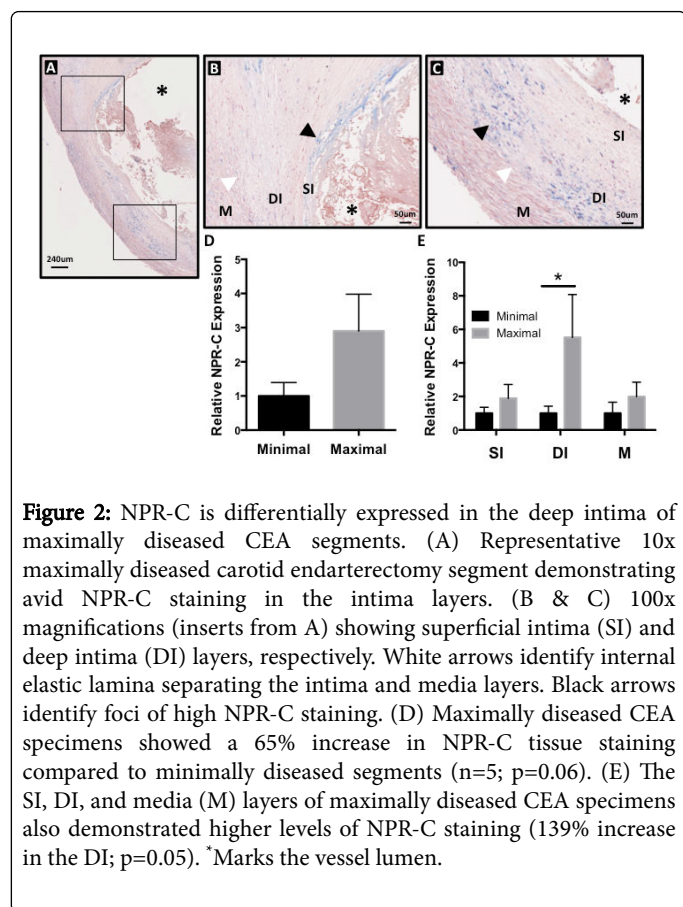
Sub-layer analysis of the juxta-luminal intima demonstrated a 139% increase in NPR-C staining in the deep intima layer of maximally diseased carotid artery segments (p=0.05; Figures 2C and 2E). There were also specific foci of intense NPR-C staining in the superficial intima plaque layers of maximally diseased segments (p=0.17; Figures 2A, 2B and 2D).

Overall, we observed relatively less NPR-C expression in the media (M) layer of maximally and minimally diseased segments, with only a modest increase of NPR-C expression in the maximally diseased segments (66%; p=0.2; Figures 2C and 2E).

Analysis of NPR-C relative to plaque vulnerability features

CEA specimen sections from an additional cohort of 13 patients (mean age 64.5 years, 12 male, and 6 diabetic), were analyzed for NPR-C plaque intima expression relative to plaque pathology, calcification, and cell density.

CEA intima morphologic characteristics revealed a notable incidence of plaque intima high cellularity (75.4%), thickened surface neointima (42.3%), and an intima plaque cap (33.7%; Table 2). Adjusted Cohen's Kappa for inter-rater reliability for the seven-member panel that evaluated carotid plaque histology was 0.82.

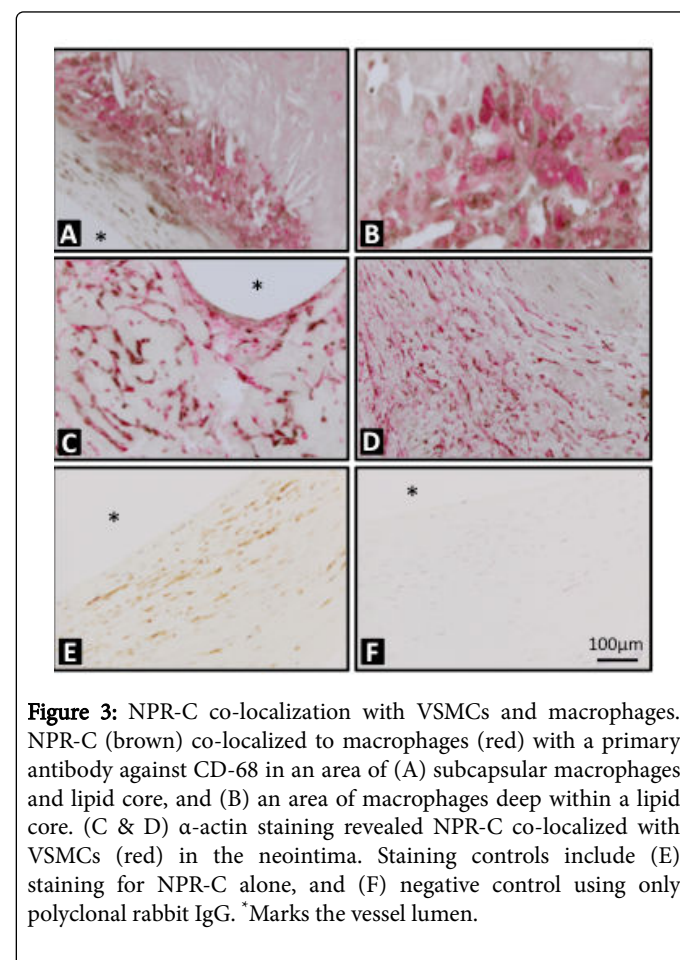


Vessel/lesion Location	% (n)
Normal intima	8.0 (39)
Thickened neointima	42.3 (207)
Plaque shoulder	15.8 (77)
Plaque cap	33.7 (164)
Surgical margin	21.1 (103)
Perpendicular tear	18.9 (92)
High Cellularity	75.4 (367)
Calcification	17.0 (83)
% and n of 493 analyzed images	

Table 2: Basic characteristics observed in 100x images.

A multiple linear regression model demonstrated a statistically significant correlation between plaque severity features and mean NPR-C score within each 100x magnification image (F=10.0, df=337, p<0.001) with an adjusted R-squared of 0.13 (Table 3). Significant predictors of high NPR-C expression included areas of high cell density ($\beta=0.315$, 95% CI=0.35, 0.595) and in plaque shoulder or cap ($\beta=1.41$, 95% CI=1.25, 1.56). Areas of high cell density within plaques also demonstrated increased VSMC density (Figure 3). Areas of increased plaque calcification did not have a higher grade of NPR-C staining (Table 3). Areas in the plaque that were adjacent to the CEA

incision (longitudinal plaque transection perpendicular to the vessel lumen) were also not significant predictors of local NPR-C expression.



Variable	Coef.	S.E.	95% CI	p
Shoulder or cap	1.406	0.079	1.251, 1.561	<0.001
High cellularity	0.315	0.142	0.35, 0.595	0.027
Surgical margin	-0.052	0.131	-0.311, 0.203	0.681
Perpendicular tear	0.143	0.143	-0.138, 0.423	0.319
Nearby calcification	0.307	0.211	-0.108, 0.721	0.146
Constant	1.406	0.079	1.251, 1.561	<0.001

Coef: Coefficient; SE: Standard Error; CI: Confidence Interval

Table 3: Multiple linear regression model of local factors predicting the NPR-C grade in each 100x image.

We further evaluated whether plaque NPR-C staining scores were predictive of plaque AHA grade and other morphologic features. We observed in our analysis model that NPR-C tissue expression scores highly correlated with overall plaque AHA grade (F=3.29, df=53, p=0.012; with an adjusted R-squared of 0.18).

NPR-C expression was increased in the superficial intima of atheromas and fibroatheromas, and was a significant predictor of advanced plaque pathology ($\beta=1.04$, 95% CI=0.46, 1.64; Table 4).

However, the presence of hemorrhage, calcification, and shoulder inflammation in the entire plaque were not significant predictors of NPR-C expression within the superficial intima (at 200 μm depth from the vessel lumen).

Variable	Coef.	S.E.	95% CI	p
AHA grade IV or V	0.990	0.290	0.393, 1.587	0.002
Shoulder inflammation	0.110	0.297	-0.367, 0.586	0.645
Hemorrhage	-0.015	0.221	-0.460, 0.430	0.945
Calcification	-0.159	0.250	-0.661, 0.344	0.529
Constant	1.103	0.230	0.541, 1.564	<0.001

Coef., coefficient; S.E., standard error; CI, confidence interval

Table 4: Multiple linear regression model of histology features predicting the mean NPR-C grade in each section.

Co-localization analysis of NPR-C

The majority of CD68 positive macrophages in analyzed specimens were in the deep intima (>200 μm from the vessel lumen) and demonstrated moderate NPR-C staining (Figures 3A and 3B). We observed high levels of NPR-C tissue staining within the neointima and α -actin positive VSMCs (Figures 3C and 3D). NPR-C expression levels were approximately proportional to the number of VSMCs observed in the intima layers analyzed. NPR-C was not identified in superficial intima endothelial cells at image magnifications analyzed. Areas of intima calcification, identified with H&E staining, were distributed unevenly and showed no cell nuclei and little to no NPR-C staining.

Discussion

The majority of patients with high-grade asymptomatic carotid arterial occlusive disease do not progress to a symptomatic status [2,4]. Despite this, current evidence-based treatment guidelines recommend treatment for all patients with high-grade asymptomatic disease to prevent stroke [1]. Thus, there is a clear management dilemma since there are no methods to identify which high-grade asymptomatic lesions are at higher risk of causing stroke. To answer this issue, efforts are directed to identify carotid plaque biomarkers associated with vulnerable and advanced carotid plaque pathology [6]. This study builds on previous findings that demonstrate differential expression profiles of specific natriuretic peptides and their associated receptors in atherosclerotic lesions [18,19], and in the media of segments of carotid artery stenosis [17]. Here, we specifically observed that NPR-C expression is localized primarily in the carotid plaque intima and highly correlates with advanced carotid atherosclerotic plaque pathology. Furthermore, our findings suggest that NPR-C expression is specifically localized to vulnerable plaque intima regions. Therefore, our study provides further evidence that NPR-C may serve as an important diagnostic biomarker of advanced and increasingly vulnerable carotid artery atherosclerotic disease.

NPR-C is the most abundantly expressed NPR [7,25], and is widely distributed in various cell types such as platelets and vascular smooth

muscle cells (VSMC) [7,25-27]. Functionally, NPR-C is implicated in multiple cardiovascular functions, including vascular permeability [28], cardiac conduction [29], blood pressure [30], vascular remodeling [14], and angiogenesis [31]. In endothelial cells, NPR-C can affect endothelin expression and secretion, which regulates intimal permeability [32,33]. In VSMCs, NPR-C can modulate VEGF production and in turn affect hypoxia-induced tissue remodeling and recovery [34-36]. Whole body *in vivo* knockout of Npr3 (NPR-C gene) in a murine model leads to hypotension and skeletal deformities due to rapid bone turnover [37]. Antisense knockdown of Npr3 attenuates CNP-mediated inhibition of cardiac chronotropic effects [38]. The variety of reported NPR-C cellular functions highlights its multifaceted roles in cardiovascular homeostasis.

Less is known about the role of NPR-C in cardiovascular pathology, particularly in arterial beds affected by advanced atherosclerotic plaque. In human coronary atherosclerotic lesions, NPR-C and NPR-B but not NPR-A, have increased expression in the intima and inner medial layers [7]. Expression levels of NPR-C and its ligands are dependent on the type of lesion, and appear to have the highest intensity expression in intermediate-type plaques [17]. A continuous infusion of the potent NPR-C ligand, CNP, can inhibit intimal proliferation in rat common carotid arteries following an induced intimal injury [18]. NPR-C and CNP expression is up-regulated in the neointima of rat carotid arteries 14 days after balloon angioplasty [39]. In a hypercholesterolemic rabbit model, both NPR-C and its CNP ligand were found to be expressed in intraluminal plaques and in neointimal VSMCs [18].

Kuehnl et al. also demonstrated that NPR-C expression was augmented in histologically unstable carotid artery plaques [20]. That group reported NPR-C, NPR-B, and CNP is mostly expressed in the VSMCs of the media. Our findings uniquely demonstrate that NPR-C is differentially expressed in the vulnerable plaque intimal regions, and in VSMCs that have migrated into the deep and superficial intima layers. Relative to the intima, we observed minimal NPR-C staining in the carotid artery media (Figure 2). Furthermore, in maximally diseased carotid artery plaques we observed higher NPR-C expression in the deep intima layers than in the superficial intima layers (Figure 2C). Our findings support the theory that VSMCs infiltrating into the carotid plaque intima are pathologically unique, and have differential expression of NPR-C relative to plaque severity. We suspect that increased NPR-C expression in progressive atheroma contributes to altered autocrine/paracrine signaling in the plaque microenvironment that affects VSMC migration and function.

We also demonstrate moderate NPR-C co-localization with intima macrophages (Figure 3). Prior studies also observed this in arterial walls undergoing rapid remodeling [40]. For example, Naruko et al. reported increased NPR-C expression in the neointima following intra-arterial balloon angioplasty [12]. In our study, the majority of macrophages that were positive for NPR-C were in the deep intima (>200 μm from the lumen), where we also observed notable VSMC staining and co-localization (Figure 3). This suggests that this deep intima plaque region is a uniquely active layer with variable NPR-C expression and cellular composition. We also observed fewer NPR-C positive macrophages at plaque shoulder regions. This may help explain why plaque shoulder inflammation was not found to be a significant predictor of NPR-C expression in our overall regression analysis. It also demonstrates that not all areas of macrophage accumulation are necessarily associated with high NPR-C expression, and differential expression of NPR-C is not exclusive to macrophage

density. Thus, plaque intima expression of NPR-C is affected by multiple cell types that work in concert with one another to affect plaque progression and vulnerability.

Non-invasive *in vivo* positron emission tomography (PET)-mediated molecular imaging can specifically localize NPR-C expression in the lumen arterial wall [41]. We recently developed a unique multifunctional, PET-compatible ⁶⁴Cu-radiolabeled, core-shell nanoparticle that can specifically bind to NPR-C *in vivo* [42]. This technology is transferable in the diagnosis and management of patients with advanced asymptomatic carotid artery atherosclerosis. Non-invasive molecular imaging of NPR-C and other biomarkers of advanced and vulnerable disease can help identify patients who are at higher risk of a stroke, and can justify earlier and/or more targeted intervention. A feasibility clinical trial is currently underway to evaluate the safety and efficacy of molecular imaging of NPR-C in patients with advanced carotid artery stenosis (PET Imaging of Natriuretic Peptide Receptor C (NPR-C) in Carotid Atherosclerosis; NCT02417688) [43].

In conclusion, we show that NPR-C expression is increased in the intima of human CEA plaques. We further demonstrate that in the intima, NPR-C expression co-localizes to VSMCs and macrophages that reside in the deep plaque intima layer. Our findings suggest that NPR-C expression correlates with advanced disease and vulnerable plaque features. This suggests that NPR-C is a potentially important biomarker of unstable atherosclerotic lesions particularly in the carotid arterial system. Accordingly, NPR-C molecular imaging may be useful in risk-stratification of patients with asymptomatic advanced carotid artery atherosclerotic disease.

Acknowledgements

We would like to thank Dr. Robert Thompson for providing carotid artery plaque tissue. We would like to also thank Batool Arif, Terri Ennis, Corine Gardner, Kathy Graperhaus, Jianping Jin, Pamela Kell, Neha Dahiya, David Muccigrosso, and Dongli Mao for their assistance with blinded staining analysis and grading. We appreciate Dr. Rich Pierce's staining expertise and helpful technical advice. Dr. Mohamed Zayed was supported by the Society for Vascular Surgery Foundation Annual Clinical Seed Grant, the Vascular Cures Foundation Annual Wylie Scholar Award, and the Washington University Diabetes Research Center (P30 DK020579). Dr. Scott Haring was supported by a grant from the Doris Duke Charitable Foundation to Washington University in St. Louis. This research was also supported by NIH NHLBI (HHSN268201000043C, and UL1 RR024992).

Funding

Society for Vascular Surgery Foundation Clinical Research Seed Grant (MAZ), Vascular Cures Foundation Annual Wylie Scholar Award (MAZ), Washington University Diabetes Research Center Pilot & Feasibility Grant (P30 DK020579; MAZ), Doris Duke Charitable Foundation to Washington University in St. Louis (SDH), and NIH NHLBI HHSN268201000043C and UL1 RR024992 (PKW).

References

1. Brott TG, Halperin JL, Abbara S, Bacharach JM, Barr JD, et al. (2011) ASA/ACCF/AHA/AANN/AANS/ACR/ASNR/CNS/SAIP/SCAI/SIR/SNIS/SVM/SVS guideline on the management of patients with extracranial carotid and vertebral artery disease. *Stroke* 42: e464-540.

2. Chambers BR, Donnan GA (2005) Carotid endarterectomy for asymptomatic carotid stenosis. *Cochrane Database Syst Rev* 4: CD001923.
3. Chaturvedi S, Bruno A, Feasby T, Holloway R, Benavente O, et al. (2005) Carotid endarterectomy--an evidence-based review: report of the Therapeutics and Technology Assessment Subcommittee of the American Academy of Neurology. *Neurology* 65: 794-801.
4. Hennerici M, Hulsbomer HB, Heffer H, Lammerts D, Rautenberg W (1987) Natural history of asymptomatic extracranial arterial disease. Results of a long-term prospective study. *Brain* 110: 777-791.
5. Markus HS, King A, Shipley M, Topakian R, Cullinane M, et al. (2010) Asymptomatic embolisation for prediction of stroke in the Asymptomatic Carotid Emboli Study (ACES): a prospective observational study. *Lancet Neurol* 9: 663-671.
6. Sangiorgi G (2007) Pathology may help decision making in asymptomatic carotid disease. *J Interv Cardiol* 20: 231-235.
7. Potter LR, Yoder AR, Flora DR, Antos LK, Dickey DM (2009) Natriuretic peptides: their structures, receptors, physiologic functions and therapeutic applications. *Handb Exp Pharmacol* 191: 341-366.
8. Scotland RS, Ahluwalia A, Hobbs AJ (2005) C-type natriuretic peptide in vascular physiology and disease. *Pharmacol Ther* 105: 85-93.
9. Wei CM, Hu S, Miller VM, Burnett JC (1994) Vascular actions of C-type natriuretic peptide in isolated porcine coronary arteries and coronary vascular smooth muscle cells. *Biochem Biophys Res Commun* 205: 765-771.
10. Khambata RS, Panayiotou CM, Hobbs AJ (2011) Natriuretic peptide receptor-3 underpins the disparate regulation of endothelial and vascular smooth muscle cell proliferation by C-type natriuretic peptide. *Br J Pharmacol* 164: 584-597.
11. Scotland RS, Cohen M, Foster P, Lovell M, Mathur A, et al. (2005) C-type natriuretic peptide inhibits leukocyte recruitment and platelet-leukocyte interactions via suppression of P-selectin expression. *Proc Natl Acad Sci U S A* 102: 14452-14457.
12. Naruko T, Itoh A, Haze K, Ehara S, Fukushima H, et al. (2005) C-Type natriuretic peptide and natriuretic peptide receptors are expressed by smooth muscle cells in the neointima after percutaneous coronary intervention. *Atherosclerosis* 181: 241-250.
13. Anand-Srivastava MB, Srivastava AK, Cantin M (1987) Pertussis toxin attenuates atrial natriuretic factor-mediated inhibition of adenylate cyclase. Involvement of inhibitory guanine nucleotide regulatory protein. *J Biol Chem* 262: 4931-4934.
14. Li Y, Hashim S, Anand-Srivastava MB (2006) Intracellular peptides of natriuretic peptide receptor-C inhibit vascular hypertrophy via Gqalpha/MAP kinase signaling pathways. *Cardiovasc Res* 72: 464-472.
15. Villar IC, Panayiotou CM, Sheraz A, Madhani M, Scotland RS, et al. (2007) Definitive role for natriuretic peptide receptor-C in mediating the vasorelaxant activity of C-type natriuretic peptide and endothelium-derived hyperpolarising factor. *Cardiovasc Res* 74: 515-525.
16. Tamura N, Ogawa Y, Chusho H, Nakamura K, Nakao K, et al. (2000) Cardiac fibrosis in mice lacking brain natriuretic peptide. *Proc Natl Acad Sci U S A* 97: 4239-4244.
17. Casco VH, Veinot JP, Kuroski de Bold ML, Masters RG, Stevenson MM, et al. (2002) Natriuretic peptide system gene expression in human coronary arteries. *J Histochem Cytochem* 50: 799-809.
18. Furuya M, Miyazaki T, Honbou N, Kawashima K, Ohno T, et al. (1995) C-type natriuretic peptide inhibits intimal thickening after vascular injury. *Ann N Y Acad Sci* 748: 517-523.
19. Rollin R, Mediero A, Fernandez-Cruz A, Fernandez-Durango R (2005) Downregulation of the atrial natriuretic peptide/natriuretic peptide receptor-C system in the early stages of diabetic retinopathy in the rat. *Mol Vis* 11: 216-224.
20. Kuehn A, Pelisek J, Pongratz J, Eckstein HH (2012) C-type natriuretic peptide and its receptors in atherosclerotic plaques of the carotid artery of clinically asymptomatic patients. *Eur J Vasc Endovasc Surg* 43: 649-654.

21. Stary HC, Chandler AB, Dinsmore RE, Fuster V, Glagov S, et al. (1995) A definition of advanced types of atherosclerotic lesions and a histological classification of atherosclerosis. A report from the Committee on Vascular Lesions of the Council on Arteriosclerosis, American Heart Association. *Arterioscler Thromb Vasc Biol* 15: 1512-1531.
22. Kriszbacher I, Koppan M, Bodis J (2005) Inflammation, atherosclerosis, and coronary artery disease. *N Engl J Med* 353: 429-430.
23. Ross R (1999) Atherosclerosis--an inflammatory disease. *N Engl J Med* 340: 115-126.
24. Otsuka F, Joner M, Prati F, Virmani R, Narula J (2014) Clinical classification of plaque morphology in coronary disease. *Nat Rev Cardiol* 11: 379-389.
25. Rubattu S, Sciarretta S, Morriello A, Calvieri C, Battistoni A, et al. (2010) NPR-C: a component of the natriuretic peptide family with implications in human diseases. *J Mol Med (Berl)* 88: 889-897.
26. Doi K, Ikeda T, Itoh H, Ueyama K, Hosoda K, et al. (2001) C-type natriuretic peptide induces redifferentiation of vascular smooth muscle cells with accelerated reendothelialization. *Arterioscler Thromb Vasc Biol* 21: 930-936.
27. Anand-Srivastava MB (2005) Natriuretic peptide receptor-C signaling and regulation. *Peptides* 26: 1044-1059.
28. Chauhan SD, Nilsson H, Ahluwalia A, Hobbs AJ (2003) Release of C-type natriuretic peptide accounts for the biological activity of endothelium-derived hyperpolarizing factor. *Proc Natl Acad Sci U S A* 100: 1426-1431.
29. Rose RA, Lomax AE, Kondo CS, Anand-Srivastava MB, Giles WR (2004) Effects of C-type natriuretic peptide on ionic currents in mouse sinoatrial node: a role for the NPR-C receptor. *Am J Physiol Heart Circ Physiol* 286: H1970-1977.
30. Saulnier PJ, Roussel R, Halimi JM, Lebre C, Dardari D, et al. (2011) Impact of natriuretic peptide clearance receptor (NPR3) gene variants on blood pressure in type 2 diabetes. *Diabetes Care* 34: 1199-1204.
31. Kuehn A, Pelisek J, Ring A, Spindler N, Hatz R, et al. (2013) C-type natriuretic peptide slows down wound healing but promotes angiogenesis in SKH1-hr hairless mice. *Int Wound J* 10: 425-430.
32. Kohno M, Yasunari K, Yokokawa K, Murakawa K, Horio T, et al. (1991) Inhibition by atrial and brain natriuretic peptides of endothelin-1 secretion after stimulation with angiotensin II and thrombin of cultured human endothelial cells. *J Clin Invest* 87: 1999-2004.
33. Marala RB, Duda T, Sharma RK (1993) Interaction of atrial natriuretic factor and endothelin-1 signals through receptor guanylate cyclase in pulmonary artery endothelial cells. *Mol Cell Biochem* 120: 69-80.
34. Casals G, Ros J, Sionis A, Davidson MM, Morales-Ruiz M, et al. (2009) Hypoxia induces B-type natriuretic peptide release in cell lines derived from human cardiomyocytes. *Am J Physiol Heart Circ Physiol* 297: H550-555.
35. Casserly B, Mazer JM, Vang A, Harrington EO, Klinger JR, et al. (2011) C-type natriuretic peptide does not attenuate the development of pulmonary hypertension caused by hypoxia and VEGF receptor blockade. *Life Sci* 89: 460-466.
36. Pedram A, Razandi M, Hu RM, Levin ER (1997) Vasoactive peptides modulate vascular endothelial cell growth factor production and endothelial cell proliferation and invasion. *J Biol Chem* 272: 17097-17103.
37. Chusho H, Tamura N, Ogawa Y, Yasoda A, Suda M, et al. (2001) Dwarfism and early death in mice lacking C-type natriuretic peptide. *Proc Natl Acad Sci U S A* 98: 4016-4021.
38. Palaparti A, Li Y, Anand-Srivastava MB (2000) Inhibition of atrial natriuretic peptide (ANP) C receptor expression by antisense oligodeoxynucleotides in A10 vascular smooth-muscle cells is associated with attenuation of ANP-C-receptor-mediated inhibition of adenylyl cyclase. *Biochem J* 346: 313-320.
39. Brown J, Chen Q, Hong G (1997) An autocrine system for C-type natriuretic peptide within rat carotid neointima during arterial repair. *Am J Physiol* 272: H2919-2931.
40. Kiemer AK, Vollmar AM (1997) Effects of different natriuretic peptides on nitric oxide synthesis in macrophages. *Endocrinology* 138: 4282-4290.
41. Liu Y, Abendschein D, Woodard GE, Rossin R, McCommis K, et al. (2010) Molecular imaging of atherosclerotic plaque with (64)Cu-labeled natriuretic peptide and PET. *J Nucl Med* 51: 85-91.
42. Liu Y, Pressly ED, Abendschein DR, Hawker CJ, Woodard GE (2011) Targeting angiogenesis using a C-type atrial natriuretic factor-conjugated nanoprobe and PET. *J Nucl Med* 52: 1956-1963.
43. PET Imaging of Natriuretic Peptide Receptor C (NPR-C) in Carotid Atherosclerosis. Accessed on February 4, 2016.