

Washington University School of Medicine

Digital Commons@Becker

---

Open Access Publications

---

2016

## Treatment with Tumor-Treating Fields therapy and pulse dose bevacizumab in patients with bevacizumab-refractory recurrent glioblastoma: A case series.

George Ansstas

*Washington University School of Medicine in St. Louis*

David D. Tran

*Washington University School of Medicine in St. Louis*

Follow this and additional works at: [https://digitalcommons.wustl.edu/open\\_access\\_pubs](https://digitalcommons.wustl.edu/open_access_pubs)

**Please let us know how this document benefits you.**

---

### Recommended Citation

Ansstas, George and Tran, David D., "Treatment with Tumor-Treating Fields therapy and pulse dose bevacizumab in patients with bevacizumab-refractory recurrent glioblastoma: A case series.." *Case Reports in Neurology*. 8, 1. 1-9. (2016).

[https://digitalcommons.wustl.edu/open\\_access\\_pubs/5782](https://digitalcommons.wustl.edu/open_access_pubs/5782)

This Open Access Publication is brought to you for free and open access by Digital Commons@Becker. It has been accepted for inclusion in Open Access Publications by an authorized administrator of Digital Commons@Becker. For more information, please contact [vanam@wustl.edu](mailto:vanam@wustl.edu).

# Treatment with Tumor-Treating Fields Therapy and Pulse Dose Bevacizumab in Patients with Bevacizumab-Refractory Recurrent Glioblastoma: A Case Series

George Ansstas · David D. Tran

Neuro-Oncology Program, Division of Oncology, Washington University, School of Medicine, St. Louis, Mo., USA

## Key Words

Glioblastoma · Bevacizumab · TTFields · Novocure · Optune™

## Abstract

Patients with bevacizumab-refractory recurrent glioblastoma multiforme (GBM) have a poor prognosis. We propose that instead of continuing on bevacizumab, patients should switch to treatment with Optune™, a novel antimitotic Tumor-Treating Fields (TTFields) therapy approved in the United States for newly diagnosed and recurrent GBM. This would reserve bevacizumab for subsequent disease progression. In this case series, we describe 8 patients with recurrent GBM who had disease progression on bevacizumab, discontinued bevacizumab treatment, and were treated with TTFields therapy alone. After subsequent radiographic or clinical progression, 5 patients were rechallenged with bevacizumab in a 'pulse dose' fashion, an approach not previously described. Following treatment with TTFields therapy, median overall survival (OS) was 216 days (7.2 months). Median OS from last dose of initial bevacizumab was 237 days (7.9 months), twice that of historical controls for bevacizumab failures, and median OS from the first dose of bevacizumab rechallenge was 172 days (5.7 months). TTFields therapy was well tolerated, with a mean adherence rate of 74.2% (range, 48.2–92.9%). These results support the use of TTFields therapy with pulse dose bevacizumab as an option in patients with refractory GBM.

© 2016 The Author(s)  
Published by S. Karger AG, Basel

## Introduction

Glioblastoma (GBM) is the most common primary malignant neoplasm of the central nervous system in adults [1], with a median overall survival (OS) of 14.6 months with standard chemoradiation [2]. Patients with recurrent GBM have limited treatment options [3]. Bevacizumab (Avastin®; Genentech, Inc., South San Francisco, Calif., USA), is an anti-VEGF recombinant humanized monoclonal antibody approved in the United States as a single agent for recurrent GBM [4]. Although radiographic responses are observed on MRI following treatment with bevacizumab [5–7], to date, no direct comparison between bevacizumab and cytotoxic chemotherapy has been conducted, and it remains unclear if bevacizumab improves OS in patients with recurrent GBM [6]. However, while on bevacizumab, patients may derive clinical benefits that include decreased cerebral edema, improved neurologic symptoms, and decreased corticosteroid use [7]. Once refractory to bevacizumab, patients are unlikely to respond to subsequent regimens, whether they contain bevacizumab or not [8], and inevitably relapse [9]. Median OS after bevacizumab failure has ranged from approximately 1.1 to 4.5 months regardless of treatment [10, 11].

Optune™ (Novocure Inc., Portsmouth, N.H., USA), previously known as the NovoTTF-100A System, a portable device delivering low-intensity intermediate-frequency (200 kHz) alternating antimitotic tumor-treating fields (TTFields) via noninvasive transducer arrays, is approved in the United States to treat adults with newly diagnosed as well as recurrent GBM as an alternative to standard medical therapy [3]. A phase 3 study of TTFields therapy versus physicians' choice of chemotherapy in patients with recurrent GBM resulted in a median OS of 6.6 months for TTFields therapy alone versus 6.0 months for chemotherapy (HR 0.86; 95% CI 0.66–1.12;  $p = 0.27$ ), with more responses and fewer adverse events in the TTFields therapy arm [3]. Post-hoc analyses of these data demonstrated that patients with bevacizumab-refractory GBM who were treated with TTFields therapy alone had a median OS of 6.0 months compared with 3.3 months for chemotherapy alone [11].

Rapid tumor regrowth or radiographic tumor-rebound phenomenon has been reported after withdrawal of bevacizumab in patients with recurrent high-grade glioma, leading to an accelerated clinical decline [10]. For this reason, many physicians are reluctant to discontinue bevacizumab even after bevacizumab failure has been well documented, leading to potential overtreatment. However, due to the antimitotic mechanism of action of TTFields therapy [12], it is possible that patients with bevacizumab-refractory recurrent GBM will benefit maximally from TTFields therapy after bevacizumab has been withdrawn and rapid tumor proliferation sets in. Bevacizumab treatment can be resumed for subsequent radiographic progression or worsening symptoms, due to either further disease progression or other inflammatory responses to TTFields-induced cell death. This case series describes the outcomes for 8 patients with bevacizumab-refractory GBM, who were treated with TTFields therapy alone, then with concomitant pulse dose bevacizumab for subsequent radiographic progression in 5 patients.

## Methods

Patients were diagnosed with GBM from August 2011 to May 2013 and ranged in age from 35 to 62 years; 5 were male.

Six of the 8 patients underwent standard treatment for GBM of maximal surgical resection followed by radiotherapy and temozolomide [2, 9]. Baseline demographics and characteristics of the patients are summarized in table 1. All patients received standard conformal

radiation therapy (~60 Gy) with concurrent temozolomide 75 mg/m<sup>2</sup>/day; 6 patients received from 1 to 10 cycles of high-dose maintenance temozolomide. One patient participated in the phase 3 DCVax-L study for newly diagnosed GBM, receiving dendritic cell-based vaccine versus placebo. Another participated in the phase 3 EF-14 study testing TTFields therapy in newly diagnosed GBM, but was randomized to the control arm and received adjuvant temozolomide alone.

Following their first disease recurrence, the patients received a number of different treatments (table 1). Of the 8 patients, 7 had participated in clinical trials for their recurrent GBM; 5 had participated in one clinical trial, and 2, in two trials. All received bevacizumab at 10 mg/kg every 2 weeks in addition to experimental agents where appropriate, which included rindopepimut, the anti-EGFRvIII mutation vaccine; dasatinib, a Src tyrosine kinase inhibitor; and vorinostat, a histone deacetylase inhibitor.

Once unequivocal radiographic evidence of bevacizumab-refractory disease progression using Response Assessment in Neuro-Oncology criteria was confirmed, bevacizumab was discontinued and TTFields therapy was delivered using two pairs of noninvasive insulated disposable arrays applied to the shaved scalp [3, 12]. For 7 patients, TTFields therapy was administered third-line following disease progression on bevacizumab. One patient had surgery at disease recurrence followed by bevacizumab; therefore, TTFields therapy was administered fourth-line. One of the 8 patients received TTFields therapy for disease recurrence on a clinical trial.

Following radiographic progression while on TTFields therapy, 5 patients were rechallenged with bevacizumab 10 mg/kg every 2 weeks. Patients were monitored for radiographic and clinical progression; TTFields therapy and/or bevacizumab were discontinued at the discretion of the treating physicians.

Survival data were collected between several time points: time from first day of TTFields therapy to death, time from last dose of first round of bevacizumab to death, and time from first dose of bevacizumab rechallenge until death. Patient deaths were confirmed by hospital records, death certificate, and/or obituary notice.

## Case Reports

Patient narratives for each of the 8 patients are presented below.

Patient No. 1, a male in his 40s, was diagnosed with a right frontal lobe GBM. He underwent near gross total resection (GTR) and received concomitant radiation therapy and temozolomide. Molecular testing revealed his tumor was MGMT negative. He subsequently declined high-dose maintenance temozolomide and was treated with bevacizumab in a clinical trial. Disease recurrence was detected at month 13, and he subsequently received bevacizumab for 5 months before developing further progression at month 20 after diagnosis. TTFields therapy was subsequently started for 4 months before further disease progression was documented at month 25 after diagnosis, and the patient died at month 28. His adherence rate is not available, as this patient was lost to follow-up.

Patient No. 2, a male in his 40s, was diagnosed with right temporal lobe GBM. He underwent GTR and received radiation therapy and temozolomide. His tumor was MGMT negative and IDH negative. He received only 1 cycle of high-dose maintenance temozolomide due to disease progression on MRI. The patient's tumor recurred at month 5, and he received bevacizumab from months 5 to 11. TTFields therapy was initiated at month 13 and continued until month 14; his adherence rate was 60.2%. Disease progression was detected at

month 14. The patient was not rechallenged with bevacizumab due to an intracerebral hemorrhage, he died at month 14.

Patient No. 3, a female in her 50s, was diagnosed with right frontal lobe secondary recurrent GBM. She had a 30-year history of a prior low-grade glioma. She underwent near-GTR and received radiation therapy and temozolomide; however, due to subsequent myelosuppression, she did not receive high-dose maintenance temozolomide. Her tumor was IDH1 positive, EGFR amplification negative, loss of 10q negative, and 1p,19q co-deletion negative. She was treated with bevacizumab from months 2 to 9, when disease recurrence was detected. TTFields therapy was started at month 9, and she was rechallenged with bevacizumab at month 11. Her last MRI, at month 13, showed no disease progression. Both TTFields therapy and bevacizumab were discontinued at month 14, due to intracerebral hemorrhage resulting from a fall. The patient subsequently declined and died 16 months from her GBM diagnosis. Her adherence rate to TTFields therapy was 84.0%.

Patient No. 4, a female in her 60s, was diagnosed with right frontal lobe GBM. Molecular testing revealed her tumor to be MGMT positive. She underwent partial resection and received concomitant radiation therapy and temozolomide. She was enrolled in the EF-14 phase clinical trial of temozolomide therapy with and without TTFields therapy for newly diagnosed GBM and was randomly assigned to the temozolomide alone arm. At disease progression at month 5, she was treated with bevacizumab in a clinical trial from months 6 to 17, when her tumor progressed. TTFields therapy was initiated at month 18, and the patient's tumor progressed at month 22, when she was maintained on TTFields therapy and rechallenged with bevacizumab. Both treatments were terminated at month 26, and the patient died at month 27. Her adherence rate to TTFields therapy was 92.9%.

Patient No. 5, a male in his 30s, was diagnosed with left frontal lobe secondary GBM. The patient did not receive radiation therapy since he had received radiation therapy for a prior low-grade glioma 5 years prior to the GBM diagnosis. His tumor tested MGMT negative, 1p,19q co-deletion negative, EGFR amplification negative, IDH1 positive, and loss of P16/CDKN 2A positive. He completed 6 cycles of high-dose maintenance temozolomide, which was stopped due to disease progression on MRI. He was then treated with bevacizumab in a clinical trial from months 2 to 10, when his tumor progressed. TTFields was started at month 12. Disease progression was documented at month 14, and he was rechallenged with bevacizumab. Further disease progression was documented at month 17. He continued to receive TTFields treatment and bevacizumab until month 20, when he died. His adherence rate to TTFields therapy was 75.9%.

Patient No. 6, a male in his 50s, was diagnosed with left frontal lobe GBM. He underwent GTR and received radiation and temozolomide and completed 6 cycles of high-dose maintenance temozolomide, which was stopped due to disease progression on MRI. His tumor was MGMT negative, EGFR amplification positive, PTEN negative, and IDH1/2 negative. The patient had disease recurrence diagnosed at month 9. Bevacizumab was administered from months 10 to 13 before disease progression was noted. TTFields therapy was initiated at month 14, and disease progression was detected at month 17. TTFields therapy was stopped at month 18; his adherence rate was 48.2%. The patient was rechallenged with a single dose of bevacizumab shortly prior to stopping TTFields, and died at month 15.

Patient No. 7, a male in his 40s, was diagnosed with left parietal lobe GBM. MGMT status was not run due to an insufficient specimen quantity. He underwent GTR followed by concomitant radiation therapy and temozolomide as well as 10 cycles of high-dose temozolomide until disease progression on MRI. At month 13, the patient had disease progression and he was treated with bevacizumab in a clinical trial from months 14 to 24, when disease progression was documented. TTFields therapy was started at month 24 and con-

tinued until month 35, when it was stopped due to disease progression and a decline in the patient's performance status; his adherence rate was 73.2%. Further disease progression was documented at month 26, and the patient was rechallenged with bevacizumab from this date until month 36. The patient died at month 38.

Patient No. 8, a female in her 60s, was diagnosed with left frontal lobe GBM on December 16, 2011, and underwent GTR followed by concomitant radiation therapy and temozolomide. Her tumor was MGMT negative, EGFR amplification positive, IDH1 negative, and 1p,19q co-deletion negative. She received 6 cycles of high-dose maintenance temozolomide, which was stopped due to disease progression on MRI. She was treated with bevacizumab in a clinical trial. Disease recurrence was detected at month 10, and she received bevacizumab from months 10 until 19. TTFields therapy was initiated at month 16 and stopped at month 21; her adherence rate was 85.3%. The patient died at month 22. At her last MRI at month 20, she had no disease progression.

## Results

Our 8 patients had a median OS of 216 days (7.2 months) from first day of treatment with TTFields therapy. Median OS from last dose of bevacizumab was 237 days (7.9 months; [table 2](#)). Median OS from first dose of bevacizumab rechallenge was 172 days (5.7 months).

Median time on bevacizumab prior to treatment with TTFields therapy was 236.5 days (7.9 months). Median time on TTFields therapy was 155 days (5.2 months), and median time from start of TTFields therapy to radiographic progression was 80.5 days (2.7 months).

In 3 of the 5 patients rechallenged with bevacizumab, TTFields therapy was administered concurrently for up to 9 months, then discontinued prior to bevacizumab. One patient received only a single dose of bevacizumab and 1 patient continued on both TTFields therapy and bevacizumab once bevacizumab was initiated.

Mean patient adherence rate to TTFields therapy was 74.2% (range, 48.2–92.9%), with adherence defined as wearing the device at least 18 h per day. Patients highly adherent to treatment – who were also those who received pulse dose bevacizumab – had the longest OS, consistent with prior data. Patient No. 4 had an adherence rate of 92.9%; her time from first day of TTFields therapy to death was 276 days (9.2 months) and, from first dose of bevacizumab rechallenge until death, 150 days (5.0 months). Patient No. 7, with an adherence rate of 73.2%, had a time from first day of TTFields therapy to death of 406 days (13.5 months) and, from first dose of bevacizumab rechallenge until death, 349 days (11.6 months; see [fig. 1](#)).

## Discussion

This set of cases describes a heavily pretreated population with bevacizumab-refractory recurrent GBM with minimal therapeutic options. Following disease progression on bevacizumab, TTFields therapy alone was administered, stabilizing these patients and allowing them to be rechallenged with bevacizumab once they became symptomatic.

Our 8 patients had a median OS of 7.9 months following progression on bevacizumab and treatment with TTFields. These results compare favorably to what has been observed in other studies for the same population of bevacizumab-refractory GBM. In a retrospective study, patients who presented with bevacizumab-refractory recurrent GBM had a median OS of 47.5 days (1.6 months); of 7 patients not restarted on bevacizumab, the median OS was 32

days (1.1 months), in contrast to a median OS of 149 days (5.0 months) for the 3 patients restarted on bevacizumab [10]. Our results in the 5 patients who were rechallenged with bevacizumab show a similar prolonged OS, a median of 172 days (5.7 months) from the time of bevacizumab rechallenge. In contrast, the 3 patients who were not rechallenged with bevacizumab had a median survival of 11 days.

TTFIELDS therapy is well tolerated with a favorable safety profile [13], and patients in the phase 3 trial reported improved quality of life compared with patients receiving chemotherapy [3]. As a local treatment, the most commonly observed toxicity with TTFIELDS therapy is skin irritation from the transducer arrays [3, 13]. In the phase 3 trial of TTFIELDS therapy in recurrent GBM, higher adherence was found to correspond with greater survival benefit, as did age  $\leq 60$  years [11], both of which we found in this case series.

In this case series, we describe 8 patients with recurrent GBM for whom it was safe to stop treatment with bevacizumab – despite the concern of possible rapid disease progression upon bevacizumab withdrawal –, effectively use TTFIELDS therapy, and then rechallenge with bevacizumab once they became symptomatic and/or had evidence of radiographic progression. This ‘pulse dose’ approach to bevacizumab administration, combined with TTFIELDS therapy, has not previously been described in this population, and its efficacy will need to be investigated further in a prospective clinical study. In the meantime, the results from this limited series suggest that this approach is well tolerated and may be considered an option in these very refractory patients.

### Acknowledgments

The authors of this paper received editorial assistance from Pharma Health Labs.

### Statement of Ethics

The authors have no ethical conflicts to disclose.

### Disclosure Statement

Dr. D.D. Tran has received research funding from Novocure and has served on the advisory board for Novocure.

### References

- 1 National Comprehensive Cancer Network: Central Nervous Systems Cancers. NCCN Guidelines, version 2.2014.
- 2 Stupp R, Mason WP, van den Bent MJ, Weller M, Fisher B, Taphoorn MJ, et al: Radiotherapy plus concomitant and adjuvant temozolomide for glioblastoma. *N Engl J Med* 2005;352:987–996.
- 3 Stupp R, Wong ET, Kanner AA, Steinberg D, Engelhard H, Heidecke V, et al: NovoTTF-100A versus physician’s choice chemotherapy in recurrent glioblastoma: a randomized phase III trial of a novel treatment modality. *Eur J Cancer* 2012;48:2192–2202.
- 4 US Food and Drug Administration: Avastin (bevacizumab). [http://www.accessdata.fda.gov/drugsatfda\\_docs/label/2011/125085s225lbl.pdf](http://www.accessdata.fda.gov/drugsatfda_docs/label/2011/125085s225lbl.pdf). (accessed March 2, 2015).

Ansstas and Tran: Treatment with Tumor-Treating Fields Therapy and Pulse Dose Bevacizumab in Patients with Bevacizumab-Refractory Recurrent Glioblastoma

- 5 Cloughesy T, Prados MD, Mikkelsen T: A phase 2 randomized non-comparative clinical trial of the effect of bevacizumab alone or in combination with irinotecan on 6-month progression free survival in recurrent refractory glioblastoma [abstract]. J Clin Oncol 2008;26(suppl 15):2010b.
- 6 Friedman HS, Prados MD, Wen PY, Mikkelsen T, Schiff D, Abrey LE, et al: Bevacizumab alone and in combination with irinotecan in recurrent glioblastoma. J Clin Oncol 2009;27:4733–4740.
- 7 Kreisl TN, Kim L, Moore K, Duic P, Royce C, Stroud I, et al: Phase II trial of single-agent bevacizumab followed by bevacizumab plus irinotecan at tumor progression in recurrent glioblastoma. J Clin Oncol 2009;27:740–745.
- 8 Quant EC, Norden AD, Drappatz J, Muzikansky A, Doherty L, Lafrankie D, et al: Role of a second chemotherapy in recurrent malignant glioma patients who progress on bevacizumab. Neuro Oncol 2009;11:550–555.
- 9 Anton K, Baehring JM, Mayer T: Glioblastoma multiforme – Overview of current treatment and future perspectives. Hematol Oncol Clin North Am 2012;26:825–853.
- 10 Zuniga RM, Torcuator R, Jain R, Anderson J, Doyle T, Schultz L, et al: Rebound tumour progression after the cessation of bevacizumab therapy in patients with recurrent high-grade glioma. J Neurooncol 2010;99:237–242.
- 11 Kanner AA, Wong ET, Villano JL, Ram Z, on behalf of the EF-11 Investigators: Post hoc analyses of intention-to-treat population in phase III comparison of NovoTTF-100A™ System versus best physician’s choice chemotherapy. Semin Oncol 2014;41(suppl 6):S25–S34.
- 12 Fonkem E, Wong ET: NovoTTF-100A: a new treatment modality for recurrent glioblastoma. Expert Rev Neurother 2012;12:895–899.
- 13 Mrugala MM, Engelhard HH, Tran DD, Kew Y, Cavaliere R, Bota DA, et al: Clinical practice experience with NovoTTF-100A™ System for glioblastoma: the Patient Registry Dataset (PRiDe). Semin Oncol 2014;41(suppl 6):S4–S13.

**Table 1.** Patient baseline demographics and characteristics

	Patient No.							
	1	2	3	4	5	6	7	8
Gender	Male	Male	Female	Female	Male	Male	Male	Female
Age at diagnosis, years	49	48	52	60	35	51	48	62
GBM de novo	Yes	Yes	No <sup>1</sup>	Yes	No <sup>2</sup>	Yes	Yes	Yes
<i>Molecular testing</i>								
MGMT	Negative	Negative		Positive	Negative	Negative	Insufficient specimen	Negative
IDH1 and/or IDH2	Negative	–	Positive	–	Positive	Negative	–	Negative
EGFR amplification	–	–	Negative	–	Negative	Positive	–	Positive
1p,19q co-deletion	–	–	Negative	–	Negative	–	–	Negative
Other	–	–	Loss of 10q negative	–	Loss of P16/CDKN2A positive	PTEN negative	–	–
Tumor location	Right frontal lobe	Right temporal lobe	Right frontal lobe	Right frontal lobe	Left frontal lobe	Left frontal lobe	Left parietal lobe	Left frontal lobe
Resection	Near GTR	GTR	Near GTR	Partial	GTR	GTR	GTR	GTR
XRT	Yes	Yes	Yes	63 Gy	None due to previous XRT for low-grade glioma	60 Gy	63 Gy	60 Gy
Concurrent temozolomide (75 mg/m <sup>2</sup> /day)	Yes	Yes	Yes	Yes	Yes	Yes	Yes	Yes

<sup>1</sup> Prior low-grade glioma in the 1980s. <sup>2</sup> Prior low-grade glioma in 2007. GTR = Gross total resection; TMZ = temozolomide; NCCTG = North Central Cancer Treatment Group.

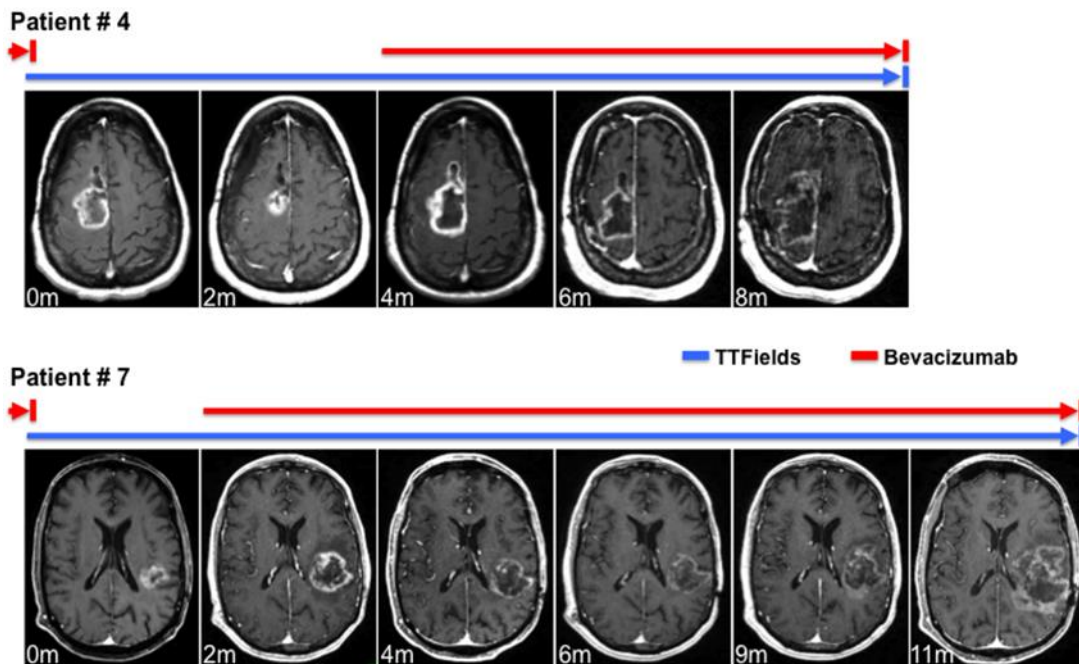


Ansstas and Tran: Treatment with Tumor-Treating Fields Therapy and Pulse Dose Bevacizumab in Patients with Bevacizumab-Refractory Recurrent Glioblastoma

**Table 2.** Duration of bevacizumab and TTFields therapy (TTF) and OS by patient

Treatment duration	Patient No.							
	1	2	3	4	5	6	7	8
Initial duration of bevacizumab treatment, days	154	182	221	315	276	91	322	252
TTF for recurrence on trial	No	Yes <sup>1</sup>	No	No	No	No	No	No
TTF line of therapy	Third	Third	Third	Third	Fourth	Third	Third	Third
Duration on TTF, days	80	60	157	252	235	154	321	153
Time on TTF until radiographic progression, days	112	55	N/A <sup>2</sup>	124	55	105	56	153
TTF adherence, %	N/A <sup>3</sup>	60.2	84.0	92.9	75.9	48.2	73.2	85.3
Time from first day of TTF to death, days	211	61 <sup>4</sup>	221	276	253	169	406	165
Time from last dose of first round of bevacizumab to death, days	246	103	228	304	295	182	411	185
Patients rechallenged with bevacizumab								
Time from first dose until death, days	N/A <sup>5</sup>	N/A <sup>4</sup>	172	150	197	36 <sup>6</sup>	349	N/A <sup>7</sup>
Survival from diagnosis until death, days	-	-	510	810	604	569	1,133	-
Patients not rechallenged with bevacizumab								
Time from survival from last day of TTF until death, days	131	1	-	-	-	-	-	11
Survival from diagnosis until death, days	837	461	-	-	-	-	-	661

<sup>1</sup> Novocure and genomic analysis study. <sup>2</sup> No progression documented on MRI; bevacizumab initiated for functional decline. <sup>3</sup> Patient lost to follow-up. <sup>4</sup> Patient died from intracerebral hemorrhage. <sup>5</sup> Patient left the country. <sup>6</sup> Only 1 dose. <sup>7</sup> Bevacizumab not restarted.



**Fig. 1.** Radiographic appearance of bevacizumab-refractory GBM treated with TTFields and subsequently rechallenged with bevacizumab. Representative pictures of serial gadolinium contrast-enhanced brain MRI scans of patients No. 4 and No. 7 are shown. Colored bars denote time line of TTFields therapy and bevacizumab rechallenge. The time frame is in months, starting from the first documented radiographic diagnosis of bevacizumab-refractory GBM. Patient No. 4 demonstrated an initial response to TTFields at 2 months but progressed radiographically at 4 months. Upon rechallenge with bevacizumab, this patient's GBM demonstrated a radiographic response to bevacizumab again. Patient No. 7 did not demonstrate radiographic response to TTFields in the first 2 months. However, this patient had a durable radiographic response to bevacizumab rechallenge while continuing on with TTFields therapy.