

Washington University School of Medicine

Digital Commons@Becker

Open Access Publications

2018

Clinical and radiographic outcomes after posterior vertebral column resection for severe spinal deformity with five-year follow-up

Max S. Riley

Washington University School of Medicine in St. Louis

Lawrence G. Lenke

Columbia University

Todd M. Chapman Jr

OrthoCarolina

Brenda A. Sides

Washington University School of Medicine in St. Louis

Kathy M. Blanke

Columbia University

See next page for additional authors

Follow this and additional works at: https://digitalcommons.wustl.edu/open_access_pubs

Please let us know how this document benefits you.

Recommended Citation

Riley, Max S.; Lenke, Lawrence G.; Chapman, Todd M. Jr; Sides, Brenda A.; Blanke, Kathy M.; and Kelly, Michael P., "Clinical and radiographic outcomes after posterior vertebral column resection for severe spinal deformity with five-year follow-up." *The Journal of Bone and Joint Surgery*. 100, 5. 396-405. (2018). https://digitalcommons.wustl.edu/open_access_pubs/6742

This Open Access Publication is brought to you for free and open access by Digital Commons@Becker. It has been accepted for inclusion in Open Access Publications by an authorized administrator of Digital Commons@Becker. For more information, please contact vanam@wustl.edu.

Authors

Max S. Riley, Lawrence G. Lenke, Todd M. Chapman Jr, Brenda A. Sides, Kathy M. Blanke, and Michael P. Kelly

Clinical and Radiographic Outcomes After Posterior Vertebral Column Resection for Severe Spinal Deformity with Five-Year Follow-up

Max S. Riley, BA, Lawrence G. Lenke, MD, Todd M. Chapman Jr., MD, Brenda A. Sides, MA, Kathy M. Blanke, RN, and Michael P. Kelly, MD, MSc

Investigation performed at the Department of Orthopaedic Surgery, Washington University, Saint Louis, Missouri

Background: Short-term studies have shown improved outcomes and alignment after posterior vertebral column resection for severe spinal deformity. Our goal was to report long-term changes in radiographic and health-related quality-of-life measures in a consecutive series of pediatric and adult patients undergoing posterior vertebral column resection with a minimum follow-up of 5 years.

Methods: We reviewed all patients undergoing posterior vertebral column resection by a single surgeon prior to January 1, 2010, at a single institution. Standard preoperative and perioperative data were collected, including the Scoliosis Research Society (SRS)-22/24 instrument. Radiographic and health-related quality-of-life measures changes were evaluated at a minimum follow-up of 5 years.

Results: One hundred and nine patients underwent posterior vertebral column resection prior to January 2010, and 54 patients (49.5%) were available for analysis: 31 (57.4%) were pediatric patients, and 23 (42.6%) were adult patients. The mean age (and standard deviation) was 12.5 ± 3 years for the pediatric cohort and 39.3 ± 20 years for the adult cohort. Improvements in the mean major Cobb angle at a minimum follow-up of 5 years were seen: 61.6% correction for the pediatric cohort and 53.9% correction for the adult cohort. The rates of proximal junctional kyphosis, defined as proximal junctional kyphosis of $>10^\circ$, were 16.1% for the pediatric cohort and 34.8% for the adult cohort, but none underwent a revision surgical procedure for symptomatic proximal junctional kyphosis. Of the 54 patients, 30 (55.6%) sustained complications, 5 (9.3%) experienced postoperative neurological deficits, and 7 (13.0%) required a revision by 5 years postoperatively. Significant improvements were observed in the SRS-Self Image with regard to the pediatric cohort at 0.9 ($p = 0.017$) and the adult cohort at 1.3 ($p = 0.002$) and in the SRS-Satisfaction with regard to the pediatric cohort at 1.8 ($p = 0.008$) and the adult cohort at 1.3 ($p = 0.005$).

Conclusions: Posterior vertebral column resection offers substantial, sustained improvements in global radiographic alignment and patient outcome scores at 5 years. The major radiographic deformity was reduced by 61.6% in the pediatric cohort and by 53.9% in the adult cohort. Despite the high rate of complications, patients experienced significant improvement in the SRS-Self Image and SRS-Satisfaction domains.

Level of Evidence: Therapeutic Level IV. See Instructions for Authors for a complete description of levels of evidence.

Posterior vertebral column resection, defined as resection of the dorsal elements and at least 1 complete vertebral body with the caudal and cranial intervertebral discs, has become a powerful technique for the correction of complex spinal deformities¹⁻⁶. Vertebrectomy was introduced by MacLennan in 1922 as an apical resection with

posterior-only approach for severe scoliosis⁷. Over the next 68 years, several authors reported the clinical utility of vertebrectomy, largely for the correction of congenital fixed kyphoscoliosis, severe rigid scoliosis, and fixed lumbosacral deformity⁸⁻¹⁶. In 1997, Bradford and Tribus reported their findings from 24 patients treated with anteroposterior

Disclosure: There was no source of external funding for this work. On the **Disclosure of Potential Conflicts of Interest** forms, which are provided with the online version of the article, one or more of the authors checked "yes" to indicate that the author had a relevant financial relationship in the biomedical arena outside the submitted work (<http://links.lww.com/JBJS/E552>).

vertebral column resection for rigid coronal decompensation¹. This was then modified to allow for vertebral column resection performed from an all-posterior approach (posterior vertebral column resection)⁶.

Much has been published with regard to the radiographic outcomes and complications of vertebral column resection, including posterior vertebral column resection^{3-5,17-19}. However, to our knowledge, few studies have shown health-related quality-of-life outcomes in patients undergoing posterior vertebral column resection and none have reported on a large series with a minimum follow-up of 5 years. A 2016 literature review²⁰ noted that “clinical outcomes... were not available in nearly all studies.” Several large studies have shown health-related quality-of-life outcomes of adult spinal deformity surgical procedures, with some patients undergoing posterior vertebral column resection embedded within the cohorts²¹⁻²⁶. In general, patients appreciate health-related quality-of-life improvement after the surgical procedure, despite high complication rates. None of these studies reviewed clinical outcomes from solely posterior vertebral column resections.

The purpose of this study was to evaluate the radiographic and clinical outcomes of patients undergoing posterior vertebral column resection by a single surgeon with a minimum follow-up of 5 years. Our hypothesis was that posterior vertebral column resection would offer patients both radiographic correction and clinical improvement, despite the technically challenging nature of the procedure and high complication rates.

Materials and Methods

Patient Selection

After institutional review board approval, patients treated with posterior vertebral column resection prior to January 1, 2010, were identified from the surgical registry of an academic medical center and an affiliated Shriners Hospital. All surgical procedures included a Schwab 5 osteotomy (single-level posterior vertebral column resection) or Schwab 6 osteotomy (multilevel posterior vertebral column resection), with resection of a complete vertebral body²⁷. Both pediatric and adult patients were included in the analysis. Patients with a variety of diagnoses were included, such as severe scoliosis, global kyphosis, angular kyphosis, and kyphosing scoliosis. Patients treated with posterior vertebral column resection for acute infection or primary management of a tumor were excluded. Patients were excluded from data analysis if they lacked baseline demographic, radiographic, and perioperative data. Patients were also excluded if they did not reach the threshold of a 5-year follow-up. Demographic and perioperative data on those lost to follow-up were included for comparison with those not lost to follow-up.

All posterior vertebral column resection procedures were performed by a single surgeon. Each procedure was tailored to the specific needs of the patient, at the discretion of the attending surgeon. All cases utilized intraoperative neurophysiologic monitoring with somatosensory evoked potentials,

descending neurogenic evoked potentials, and electromyography when data were available. Intraoperative Stagnara wake-up tests were performed if reliable intraoperative neurophysiologic monitoring data were unavailable. Prior to extubation, all patients underwent a lower-extremity motor examination.

Data Collection

Standardized data collection forms were used to collect demographic, radiographic, perioperative, and health-related quality-of-life data. Demographic variables included age, sex, body mass index (BMI), smoking status, presence of a preexisting neurological deficit, and any history of spine surgical procedures. Posteroanterior and lateral radiographs of the entire spine were obtained at the preoperative, 6-week, 2-year, and 5-year follow-up appointments. Standard coronal and sagittal plane measurements were taken, including the proximal junctional kyphosis angle, measured between the upper instrumented vertebra (UIV) and 2 segments proximal (UIV + 2). Health-related quality-of-life data were collected via the Scoliosis Research Society (SRS)-22/24 questionnaire at the preoperative, 2-year, and 5-year time points. All operative records and clinical notes were reviewed for postoperative complications or reoperations occurring within the study period. Complications were classified as prior to the 6-week follow-up, between the 6-week and 2-year follow-ups, between the 2-year and 5-year follow-ups, or after the 5-year follow-up. All untoward events were deemed complications. All new neurological deficits and complications requiring intervention with an invasive procedure (e.g., revision surgical procedures or thoracentesis) were considered major complications with the exception of iliac screw removal. Intraoperative neurological events were categorized by loss of motor evoked potentials, somatosensory evoked potentials, descending neurogenic evoked potentials, or failed wake-up tests occurring during the posterior vertebral column resection procedure. Postoperative neurological deficits were assessed immediately after the surgical procedure and any recovery was documented in follow-up visits.

Statistical Analysis

Frequency distributions and summary statistics were calculated for all variables. Pediatric and adult cohorts were analyzed independently. Pearson chi-square tests were used to compare demographic and perioperative distributions between the cohort and those lost to follow-up. Independent samples *t* tests compared continuous data between included and lost-to-follow-up groups. Paired samples *t* tests compared preoperative and postoperative radiographic parameters. Paired preoperative and postoperative health-related quality-of-life outcomes were analyzed using the Wilcoxon signed-rank test. Significance was defined as *p* < 0.05. SPSS version 24 software (IBM) was used for all analyses.

Results

One hundred and nine patients underwent posterior vertebral column resection from November 11, 1996, to

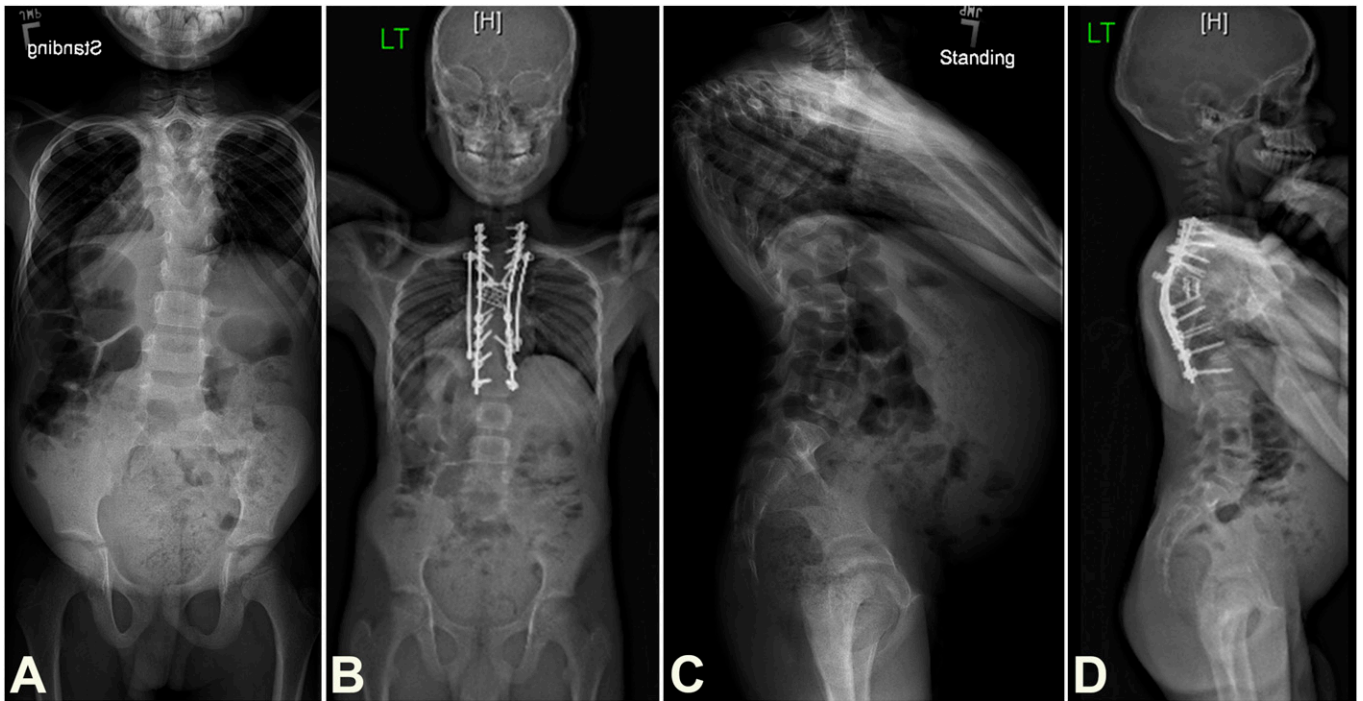


Fig. 1

Radiographs of a 9-year-old boy treated for a rigid kyphosis with myelopathy: preoperative (**Fig. 1-A**) and 5-year follow-up (**Fig. 1-B**) anteroposterior radiographs and preoperative (**Fig. 1-C**) and 5-year follow-up (**Fig. 1-D**) lateral radiographs. A single-stage, 3-level (T6, T7, T8) posterior vertebral column resection was performed.

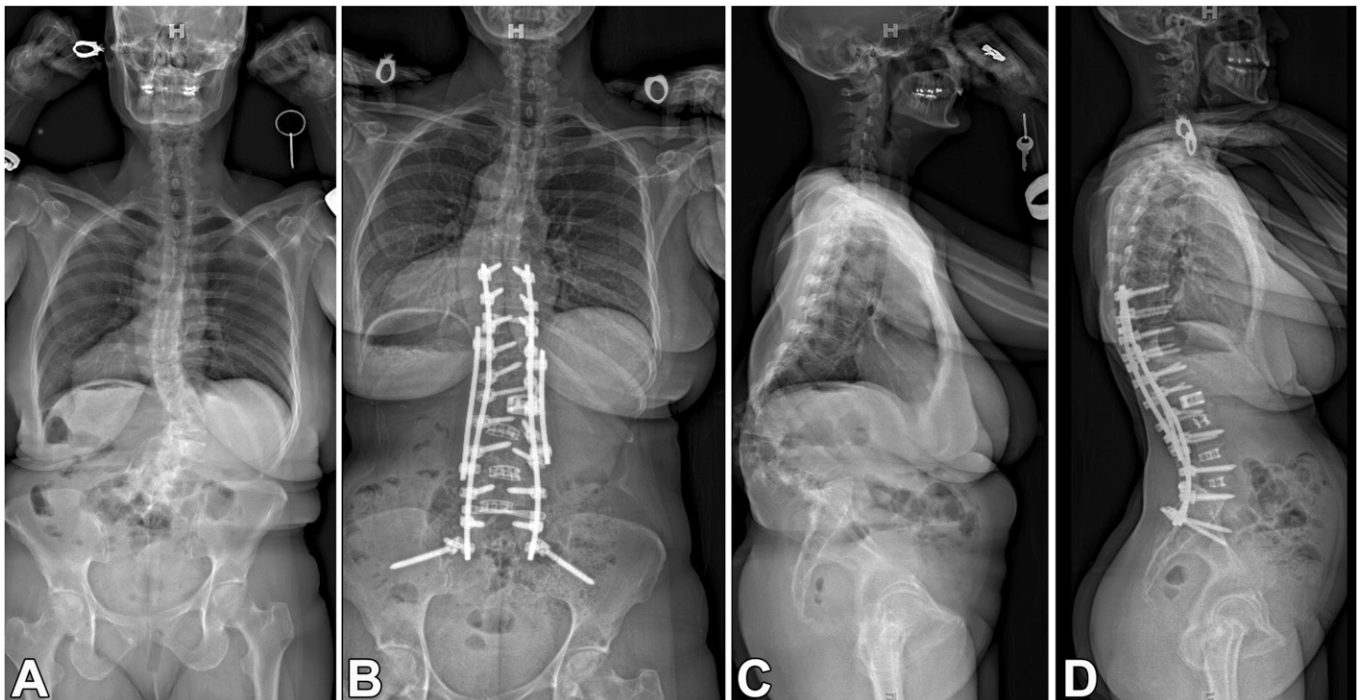


Fig. 2

Radiographs of a 54-year-old woman treated for a rigid, postlaminectomy kyphosis: preoperative (**Fig. 2-A**) and 5-year follow-up (**Fig. 2-B**) anteroposterior radiographs and preoperative (**Fig. 2-C**) and 5-year follow-up (**Fig. 2-D**) lateral radiographs. A single-stage L2 posterior vertebral column resection was performed.

TABLE I Preoperative Pediatric Demographic Data

Variable	Included (N = 31)	Excluded (N = 29)	P Value
Age* (yr)	12.5 ± 3	13.5 ± 3	0.214
Sex†			0.782
Female	15 (48.4%)	16 (55.2%)	
Male	16 (51.6%)	13 (44.8%)	
BMI* (kg/m ²)	20.9 ± 4.3	19.6 ± 5.1	0.360
Preoperative neurological deficit†			0.164
No	19 (61.3%)	13 (44.8%)	
Yes	7 (22.6%)	11 (37.9%)	
NA‡	5 (16.1%)	5 (17.2%)	
Revision procedure†			0.645
No	10 (32.3%)	11 (37.9%)	
Yes	21 (67.7%)	18 (62.1%)	

*The values are given as the mean and the standard deviation. †The values are given as the number of patients, with the percentage in parentheses. ‡NA = not available.

January 1, 2010, and 54 (49.5%) were available with a minimum follow-up of 5 years (Figs. 1 and 2). Of the 54 patients, 31 (57.4%) were pediatric patients and 23 (42.6%) were adult patients. Preoperative demographic data for included and excluded patients are summarized in Tables I and II. The mean patient age (and standard deviation) at the time of the surgical procedure was 12.5 ± 3 years (range, 5.8 to 17.1 years) for the

pediatric cohort and 39.3 ± 20 years (range, 18.1 to 79.6 years) for the adult cohort. The pediatric cohort had a nearly even sex distribution: 15 patients were female, and 16 patients were male. The adult cohort's sex distribution favored female patients: 16 female patients and 7 male patients. In both cohorts, the majority of patients underwent a revision procedure: 67.7% in the pediatric cohort and 78.3% in the adult cohort.

TABLE II Preoperative Adult Demographic Data*

Variable	Included (N = 23)	Excluded (N = 26)	P Value
Age* (yr)	39.3 ± 20	38.6 ± 19	0.903
Sex†			0.056
Female	16 (69.6%)	15 (57.7%)	
Male	7 (30.4%)	11 (42.3%)	
BMI* (kg/m ²)	24.5 ± 5.6	24.1 ± 6.4	0.824
Smoker†			0.045
No	18 (78.3%)	14 (53.8%)	
Yes	2 (8.7%)	8 (30.8%)	
NA‡	3 (13.0%)	4 (15.4%)	
Preoperative neurological deficit†			0.084
No	18 (78.3%)	14 (53.8%)	
Yes	4 (17.4%)	10 (38.5%)	
NA‡	1 (4.3%)	2 (7.7%)	
Revision procedure†			0.041
No	5 (21.7%)	13 (50.0%)	
Yes	18 (78.3%)	13 (50.0%)	

*The values are given as the mean and the standard deviation. †The values are given as the number of patients, with the percentage in parentheses. ‡NA = not available.

TABLE III Operative Data: Pediatric and Adult

Variable	Pediatric			Adult		
	Included (N = 31)	Excluded (N = 29)	P Value	Included (N = 23)	Excluded (N = 26)	P Value
No. of levels fused*	9.8 ± 3.7	11.6 ± 3.3	0.073	9.8 ± 4.9	9.1 ± 5.5	0.644
No. of instrumented vertebra*	11.3 ± 3.6	12.8 ± 3.2	0.123	12.6 ± 4.9	12.3 ± 5.1	0.875
Vertebral column resection levels*	1.7 ± 0.76	1.64 ± 0.68	0.900	1.1 ± 0.29	1.44 ± 0.65	0.025
No. of stages in a staged procedure†			0.193			0.539
1	29 (93.5%)	24 (82.8%)		14 (60.9%)	18 (69.2%)	
2	2 (6.5%)	5 (17.2%)		9 (39.1%)	8 (30.8%)	
Stage 1						
No. of patients	31	29		23	26	
Operative time* (min)	571.5 ± 119.8	618.6 ± 110.7	0.207	548.7 ± 99.7	552.1 ± 122.3	0.926
Estimated blood loss* (mL)	812.9 ± 64.7	757.4 ± 86	0.608	1,580.9 ± 294.4	1,791 ± 199.2	0.548
Stage 2						
No. of patients	2	5		9	8	
Operative time* (min)	600 ± 42.4	485 ± 120.2	0.390	420.6 ± 90.7	440 ± 112.9	0.772
Estimated blood loss* (mL)	1,350 ± 150	710 ± 146.9	0.053	950 ± 275.4	1,580 ± 344	0.070
Follow-up* (yr)	5.5 ± 1			5.4 ± 1		

*The values are given as the mean and the standard deviation. †The values are given as the number of patients, with the percentage in parentheses.

Preoperative halo traction was used in 39% (12 of 31) of pediatric cases and 35% (8 of 23) of adult cases. Of the included adult patients, 8.7% reported nicotine use, compared with 30.8% of excluded adult patients ($p = 0.041$).

Table III presents the operative data for the pediatric and adult cohorts. In both cohorts, the majority of patients underwent a single-stage procedure: 93.5% for the pediatric cohort and 60.9% for the adult cohort. The mean follow-up for both cohorts was similar: 5.5 ± 1 years for the pediatric cohort and 5.4 ± 1 years for the adult cohort. A mean number of 1.7 ± 0.76 vertebrae were resected in the pediatric cohort, compared with 1.1 ± 0.29 vertebrae in the adult cohort.

Complication data are summarized in Table IV. A total of 57 complications were identified. Twenty-six complications occurred in 15 pediatric patients. Thirty-one complications occurred in 15 adult patients. Major complications were common: 54% (14 of 26) of the complications in the pediatric cohort and 50% (10 of 20) of the complications in the adult cohort. The most common pediatric complication encountered was an intraoperative neurological event at 16.1% (5 of 31 patients). Pleural effusion and postoperative anemia occurred most commonly in the adult cohort at 21.7% (5 of 23 patients). The overall complication rate was 48.4% (15 of 31) in the pediatric cohort, compared with 65.2% (15 of 23) in the adult cohort. Intraoperative neurological events occurred in 16.1% (5 of 31: 4 transient losses of intraoperative neurophysiologic monitoring, 1 failed wake-up test) of pediatric cases and 8.7%

(2 of 23: 2 transient losses of intraoperative neurophysiologic monitoring) of adult cases. Only 2 cases, both pediatric, had new neurological deficits at the conclusion of a case complicated by intraoperative neurophysiologic monitoring changes. Postoperative neurological deficits were sustained by 12.9% (4 of 31) of pediatric patients, compared with 4.3% (1 of 23) of adult patients. The pediatric cohort sustained 2 transient nerve root injuries, 1 transient spinal cord injury, and 1 unexplained neurological sequela (nondermatomal sensory loss during follow-up). The adult cohort sustained 1 transient nerve root injury. The majority of postoperative neurological deficits (4 [80%] of 5) were resolved by the 2-year visit, and all were resolved by the time of the 5-year visit. Of the 54 patients, 13.0% (7 patients: 4 pediatric and 3 adult) of patients required a revision procedure by 5 years postoperatively. Revisions between the 2-year and 5-year time points were most commonly due to prominent instrumentation (2 involving prominent iliac instrumentation) or infection (2). Of the patients lacking 5-year follow-up, 13.8% (4 of 29) of pediatric patients and 11.5% (3 of 26) of adult patients sustained postoperative neurological deficits. Thus, the rate of new neurological deficits was 13.3% (8 of 60) in the pediatric cohort and 8.2% (4 of 49) in the adult cohort.

Radiographic results are shown in Table V. In both cohorts, there were improvements in major Cobb angle and coronal Cobb angle magnitudes as well as sagittal vertical axis. In the pediatric cohort, the mean major Cobb angle improved

TABLE IV Incidence and Outcomes of Complications by Time Point

Time Point	Pediatric	Adult	Total	Outcome
Perioperative (0 to 6 weeks)	19	20	39	
Deep wound infection*	1	0	1	Irrigation and debridement without removal of instrumentation
Excessive bleeding	0	4	4	Resolved
Hemodynamic insufficiency	1	1	2	Resolved
Prolonged intubation	1	0	1	Resolved
Fixation failure	0	1	1	Required extension of fusion
Intraoperative neurological deficit*	5	2	7	2 with postoperative sequelae, 5 resolved with intraoperative correction
Motor deficit*	1	0	1	1 flaccid paralysis, resolved with pedicle excision
Pleural effusion*	2	5	7	Resolved with thoracentesis or chest tube placement
Pneumothorax*	1	0	1	Resolved with chest tube placement
Postoperative anemia	3	5	8	Resolved
Respiratory insufficiency	2	1	3	Resolved
Urinary tract infection	1	0	1	Resolved
Wound dehiscence (superficial)	0	1	1	Resolved with local wound care
Wound necrosis	1	0	1	Resolved with local wound care
Short term (6 weeks to 2 years)	2	6	8	
Compression fracture	0	2	2	Observed
Deep wound infection*	0	1	1	Irrigation and debridement with removal of instrumentation
Fixation failure*	0	1	1	Required extension of fusion to sacrum
Gastroparesis*	1	0	1	Placement of percutaneous gastrostomy tube
Motor deficit*	1	0	1	Observed, mild
Pleural effusion*	0	1	1	Required thoracentesis
Sensory deficit	0	1	1	Observed, right L4/5 dermatomes, resolved
Intermediate term (2 to 5 years)	4	4	8	
Deep wound infection*	1	0	1	Irrigation and debridement with removal of instrumentation
Global malalignment*	1	0	1	Required pedicle subtraction osteotomy
Pressure ulcer*	0	1	1	Irrigation and debridement
Prominent iliac instrumentation	0	2	2	1 required removal of instrumentation, 1 observed
Pseudarthrosis (rod fracture)	0	1	1	Observed
Sensory deficit	1	0	1	Observed; nondermatomal, resolved
Weight loss*	1	0	1	Placement of percutaneous gastrostomy tube
Long-term (>5 years)	0	1	1	
Pseudarthrosis (rod fracture)	0	1	1	Observed

*This was a major complication.

from 71.9° to 27.6° (−44.3°) at the time of the latest follow-up, a 61.6% correction. The adult mean major Cobb angle improved from 69.4° to 32.0° at the time of the final follow-up, a 53.9% correction. The corrections were maintained throughout follow-up. Proximal junctional kyphosis, defined as the kyphosis from the UIV to UIV+2, remained stable from the 6-week visit to the final follow-up in both cohorts. No patients in

the present study underwent a revision for symptomatic proximal junctional kyphosis as a result of posterior vertebral column resection. Proximal junctional kyphosis measurements were similar among patients with and without preoperative halo-gravity traction. In the pediatric cohort, the measurements were 1.5° ± 6.2° for patients with preoperative halo-gravity traction and 6.0° ± 14.9° for patients without such

TABLE V Radiographic Data*

Variable	Preoperative	6 Weeks	2 Years	5 Years	P Value†
Pediatric					
Major Cobb angle (deg)	71.9 ± 53.6	31.1 ± 32.3	27.2 ± 29.5	27.6 ± 29.1	<0.001
Coronal Cobb angle (deg)	65.6 ± 40.1	31.3 ± 19.4	29.9 ± 17.8	29.3 ± 17.5	<0.001
Coronal vertical axis (mm)	1.0 ± 23.9	-3.3 ± 23.3	-5.7 ± 24.6	-5.4 ± 20.9	0.647
T5-T12 kyphosis (deg)	51.2 ± 45.9	36.8 ± 23.5	34.3 ± 24.8	35.4 ± 23.2	<0.001
T12-S1 lordosis (deg)	-41.3 ± 55.5	-40.5 ± 34.6	-45.6 ± 30.0	-39.5 ± 34.6	0.080
Sagittal vertical axis (mm)	17.8 ± 57.3	11.2 ± 61.9	-5.7 ± 71.3	-5.0 ± 48.3	0.003
Pelvic incidence (deg)	43.4 ± 12.8	41.4 ± 12.1	44.1 ± 13.1	40.4 ± 11.0	—
Lumbar lordosis-pelvic incidence mismatch (deg)	29.7 ± 16.9	16.3 ± 14.0	20.8 ± 12.8	18.6 ± 11.9	0.165
Proximal junctional kyphosis angle (deg)	—	4.8 ± 10.2	5.9 ± 12.5	5.4 ± 11.8	—
Adult					
Major Cobb angle (deg)	69.4 ± 45.9	26.5 ± 34.5	27.3 ± 34.7	32.0 ± 25.1	<0.001
Coronal Cobb angle (deg)	47.7 ± 43.4	20.9 ± 19.5	21.4 ± 21.6	22.8 ± 20.8	<0.001
Coronal vertical axis (mm)	-5.2 ± 25.7	-3.2 ± 14.7	1.7 ± 18.2	-1.6 ± 19.9	0.005
T5-T12 kyphosis (deg)	62.1 ± 31.6	38.2 ± 12.3	35.9 ± 14.8	35.3 ± 12.1	0.558
T12-S1 lordosis (deg)	-45.6 ± 49.8	-50.4 ± 13.5	-45.6 ± 28.8	-34.3 ± 12.1	<0.001
Sagittal vertical axis (mm)	30.2 ± 72.7	25.9 ± 72.7	29.5 ± 76.6	18.5 ± 64.1	<0.001
Pelvic incidence	45.9 ± 17.4	48.7 ± 14.3	54.6 ± 15.1	54.7 ± 14.4	—
Lumbar lordosis-pelvic incidence mismatch	27.5 ± 27.2	16.1 ± 9.8	17.1 ± 14.1	18.4 ± 10.2	0.741
Proximal junctional kyphosis angle (deg)	—	5.7 ± 9.7	6.4 ± 11.6	8.5 ± 10.4	—

*The values are given as the mean and the standard deviation. †The p value compares the 5-year data with preoperative data.

traction ($p = 0.354$); in the adult cohort, the measurements were $8.5^\circ \pm 6.0^\circ$ for patients with preoperative halo-gravity traction and $9.5^\circ \pm 12.8^\circ$ for patients without such traction ($p = 0.848$).

Table VI summarizes health-related quality-of-life data. For both cohorts, significant improvements in SRS-22/24 scores were observed in the SRS-Self Image and SRS-Satisfaction domains at both the 2-year follow-up and a

TABLE VI Comparison of Preoperative, 2-Year Follow-up, and 5-Year Follow-up Health-Related Quality-of-Life Parameters*

	Pain	Self-Image	Function	Satisfaction	Mental Health
Pediatric					
Preoperative	4.4 ± 0.5	3.3 ± 0.8	4.0 ± 0.3	2.9 ± 1.4	4.3 ± 0.5
2-year follow-up	4.4 ± 0.7	4.2 ± 0.6	4.3 ± 0.4	4.6 ± 0.5	4.5 ± 0.4
Change from preoperative	0.1 ± 0.4	0.8 ± 1.1†	0.2 ± 0.4	1.5 ± 1.9†	0.1 ± 0.6
5-year follow-up	4.4 ± 0.6	4.2 ± 0.5	3.9 ± 0.7	4.4 ± 0.8	4.3 ± 0.7
Change from preoperative	0.03 ± 0.7	0.9 ± 0.9†	-0.1 ± 0.5	1.8 ± 1.7†	0.2 ± 0.7
Adult					
Preoperative	3.2 ± 1.4	2.3 ± 0.7	3.0 ± 1.0	2.9 ± 1.6	3.4 ± 0.8
2-year follow-up	3.4 ± 1.3	3.7 ± 0.9	3.2 ± 1.0	4.1 ± 0.8	2.6 ± 0.8
Change from preoperative	0.2 ± 0.7	1.3 ± 1.1†	0.1 ± 0.6	1.0 ± 1.7†	0.2 ± 0.4
5-year follow-up	3.5 ± 1.1	3.6 ± 0.9	3.2 ± 0.9	4.3 ± 0.8	3.7 ± 0.8
Change from preoperative	0.3 ± 0.9	1.3 ± 1.0†	0.1 ± 0.4	1.3 ± 1.7†	0.3 ± 0.3†

*The values are given as the mean and the standard deviation, in points. †Significant change.

minimum 5-year follow-up. SRS-Self Image and SRS-Satisfaction scores showed the greatest absolute improvement at the 5-year follow-up: 0.9 for the pediatric cohort ($p = 0.017$) and 1.3 for the adult cohort ($p = 0.002$) with regard to the SRS-Self Image domain and 1.8 for the pediatric cohort ($p = 0.008$) and 1.3 for the adult cohort ($p = 0.005$) with regard to the SRS-Satisfaction domain. No significant improvements in SRS-Pain or SRS-Function domains were observed in either cohort. Unlike the pediatric cohort, a significant improvement in mental health was appreciated in the adult cohort at 0.3 ($p = 0.013$). Of the 55 patients lost to follow-up, 54.5% (30 patients total: 12 pediatric patients and 18 adult patients) had baseline health-related quality-of-life data and 41.8% (23 patients total: 11 pediatric patients and 12 adult patients) had available 2-year health-related quality-of-life data. The pediatric patients who were lost to follow-up had significantly lower baseline SRS-Pain scores at 3.6 ± 1.2 points ($p = 0.045$) and SRS-Mental Health scores at 3.5 ± 0.92 points ($p = 0.033$) compared with included patients. No significant difference in baseline or 2-year health-related quality-of-life scores were observed between included and lost-to-follow-up adult patients.

Discussion

Posterior vertebral column resection is a powerful tool used in the treatment of complex spinal deformities^{1,3-6,17-20}. Much has been published with regard to the radiographic outcomes and complications of vertebral column resection, including posterior vertebral column resection^{3-5,17-20}. However, few studies have shown long-term patient-reported outcomes following these complex procedures. As the population ages, the rate of surgical procedures to correct spinal deformity will increase^{28,29}. With the risk associated with posterior vertebral column resection, the benefits of these procedures must be defined. The purpose of this study was to evaluate the radiographic and clinical outcomes of patients undergoing posterior vertebral column resection by a single surgeon with a minimum follow-up of 5 years. We hypothesized that posterior vertebral column resection would offer patients both substantial radiographic correction and clinical improvement, despite the technically challenging nature of the procedure.

One hundred and nine patients underwent posterior vertebral column resection by a single surgeon and 54 patients (31 pediatric patients and 23 adult patients) underwent the procedure with a minimum follow-up of 5 years. As expected, significant corrections in major Cobb angles were obtained in both the pediatric cohort (61.6%) and the adult cohort (53.9%). Significant improvement in sagittal plane alignment was also obtained. Proximal junction kyphosis was not uncommon, with 16.1% of pediatric patients and 34.8% of adult patients sustaining proximal junctional kyphosis, developing proximal junctional kyphosis angles of at least 10° . No patients underwent a revision procedure for symptomatic proximal junctional kyphosis. Significant improvement in SRS-Self Image (pediatric: 0.9, $p = 0.017$; adult: 1.3; $p = 0.002$) and SRS-Satisfaction (pediatric: 1.8, $p = 0.008$, adult: 1.3; $p = 0.005$) were observed. No significant improvements were found

in SRS-Function or SRS-Pain in either cohort at 5 years postoperatively.

To our knowledge, little data exist in the literature with regard to patient-reported outcomes for posterior vertebral column resection. However, existing data suggest that patients appreciate clinical improvement postoperatively^{19,30,31}. Lenke et al. noted significant improvements in the SRS-30 Self Image, Function, Mental Health, and Satisfaction domains at a 1-year follow-up of pediatric posterior vertebral column resection³⁰. Papadopoulos et al. reviewed short-term data from 45 patients who underwent posterior vertebral column resection³¹. They reported significant improvement in total SRS-22 scores and SRS-Self Image scores at a mean time of 27 months postoperatively. Similar to our findings, there were no changes in either SRS-Pain or SRS-Function domains. Wang et al. reported significant improvement across all SRS-24 domains at 2-year follow-up for patients undergoing a modified posterior vertebral column resection technique including transpedicular eggshell osteotomies¹⁹. We observed significant increases in SRS-Self Image and SRS-Satisfaction scores at both the 2-year and 5-year time points. To our knowledge, this is the first study to demonstrate long-term clinical outcome durability following posterior vertebral column resection in both pediatric and adult patients.

That SRS-Self Image and SRS-Satisfaction scores tend to increase following posterior vertebral column resection likely reflects the degree of externally apparent disease associated with these severe deformities and the large amount of correction achieved with this procedure. These large corrections of rigid deformities have been consistent across prior reports^{4,5,18,32}. A review of pediatric patients with 10-year radiographic follow-up has shown these corrections to be durable³². The extensive fusions required to reconstruct these complex deformities may limit the ability of surgical procedures to improve function. A comparative cohort of nonoperative patients may show that preservation of function is the benefit of the surgical procedure and would not have been otherwise expected.

Posterior vertebral column resection is a technically challenging procedure reserved for the most severe spinal deformities. We found an overall complication rate of 55.6% (48.4% pediatric, 65.2% adult). Intraoperative neurological events (defined by a change in intraoperative neurophysiologic monitoring) occurred in 12.9% (16.1% pediatric and 8.7% adult), and 12.9% of pediatric patients and 4.3% of adult patients sustained new neurological deficits. In a multicenter cohort of 147 pediatric patients undergoing posterior vertebral column resection, Lenke et al.³⁰ reported a 59% complication rate, as well as a 27% rate of intraoperative neurological events, rates higher than those reported in earlier studies of posterior vertebral column resection with smaller cohorts. This is likely due to the inclusion of intraoperative neurophysiologic monitoring events as well as our definition of excessive blood loss (>2 L). All neurological deficits resolved by 5 years postoperatively for both the pediatric and adult cohorts in those patients with 5-year follow-up. Neurological deficits, including spinal

cord injury resulting in complete paraplegia, are the most important and feared complications of the posterior vertebral column resection procedure. Our findings suggest that appropriate attention to intraoperative neurophysiologic monitoring changes and new neurological deficits may render them transient rather than permanent.

This study had several limitations. Although procedures were performed at 2 medical centers, 1 surgeon performed all posterior vertebral column resections. As such, our findings may be specific to the particular technique of the surgeon and not generalizable. We had a large loss-to-follow-up rate (50.5% overall, 48.3% pediatric, and 53.1% adult) at 5 years postoperatively, due in part to the amount of medical tourism associated with the practice. In the pediatric cohort, the demographic and perioperative characteristics of those lost to follow-up largely mirrored the included patients. In the adult cohort, the excluded patients were significantly more likely to be tobacco users. Studies have shown that nicotine may predispose patients to higher complication rates, a higher risk of nonunion, and poorer outcomes^{33,34}. As only 2 included patients had a history of smoking and 5-year health-related quality-of-life data were not available for those lost to follow-up, we are unable to draw conclusions with regard to this effect. We report a complication rate of 55.6% (48.4% for the pediatric cohort and 65.2% for the adult cohort). Although these rates are supported by previous literature, they likely underestimate the true complication rate due to incomplete data retrieval. We encountered new neurological deficit rates (12.9% for the pediatric cohort and 4.3% for the adult cohort) that were lower than those in previous studies. Retrospective studies likely underestimate new neurological deficit rates, as a result of incomplete medical records and the lack of standardized motor examinations³⁵. Because of the breadth of complications encountered, no analysis of health-related quality-of-life change stratified by complication type is possible. Such a comparison would likely require the creation of a composite variable for complications. Any composite variable

would then misrepresent the associations between patient data and the likelihood of complications.

Despite the technically challenging nature of the procedure, our results suggest that patients can achieve substantial correction of spinal deformity with posterior vertebral column resection. We observed a major Cobb angle correction of 61.6% in our pediatric cohort and 53.9% in our adult cohort at a minimum follow-up of 5 years. Patients undergoing posterior vertebral column resection achieved significant improvements in SRS-Self Image and SRS-Satisfaction scores. Confirmation bias and cognitive dissonance may affect the improvements reported by patients. These are large surgical procedures with frequent complications, and patients may be unable or unwilling to find that the surgical procedure had no effect. We observed a 55.6% complication rate overall. Despite the complications associated with posterior vertebral column resection, patients may appreciate radiographic and clinical improvement that is durable at ≥ 5 years postoperatively. ■

Max S. Riley, BA¹
Lawrence G. Lenke, MD²
Todd M. Chapman Jr., MD³
Brenda A. Sides, MA¹
Kathy M. Blanke, RN²
Michael P. Kelly, MD, MSc¹

¹Department of Orthopaedic Surgery, Washington University School of Medicine, Saint Louis, Missouri

²Department of Orthopaedic Surgery, Columbia University College of Physicians and Surgeons, New York, NY

³OrthoCarolina, Charlotte, North Carolina

ORCID iD for M.P. Kelly: [0000-0001-6221-7406](https://orcid.org/0000-0001-6221-7406)

References

- Bradford DS, Tribus CB. Vertebral column resection for the treatment of rigid coronal decompensation. *Spine (Phila Pa 1976)*. 1997 Jul 15;22(14):1590-9.
- Lenke LG, O'Leary PT, Bridwell KH, Sides BA, Koester LA, Blanke KM. Posterior vertebral column resection for severe pediatric deformity: minimum two-year follow-up of thirty-five consecutive patients. *Spine*. 2009;34:2213-21.
- Lenke LG, Sides BA, Koester LA, Hensley M, Blanke KM. Vertebral column resection for the treatment of severe spinal deformity. *Clin Orthop Relat Res*. 2010 Mar;468(3):687-99. Epub 2009 Sep 1.
- Suk SI, Chung ER, Kim JH, Kim SS, Lee JS, Choi WK. Posterior vertebral column resection for severe rigid scoliosis. *Spine (Phila Pa 1976)*. 2005 Jul 15;30(14):1682-7.
- Suk SI, Chung ER, Lee SM, Lee JH, Kim SS, Kim JH. Posterior vertebral column resection in fixed lumbosacral deformity. *Spine (Phila Pa 1976)*. 2005 Dec 1;30(23):E703-10.
- Suk SI, Kim JH, Kim WJ, Lee SM, Chung ER, Nah KH. Posterior vertebral column resection for severe spinal deformities. *Spine (Phila Pa 1976)*. 2002 Nov 1;27(21):2374-82.
- MacLennan A. Nineteenth Annual Meeting of the British Medical Association: Scoliosis. *BMJ*. 1922;2:864-6.
- Bradford DS, Boachie-Adjei O. One-stage anterior and posterior hemivertebra resection and arthrodesis for congenital scoliosis. *J Bone Joint Surg Am*. 1990 Apr;72(4):536-40.
- Compere E. Excision of hemivertebrae for correction of congenital scoliosis. *J Bone Joint Surg Am*. 1932;14:555-62.
- Floman Y, Penny JN, Micheli LJ, Riseborough EJ, Hall JE. Osteotomy of the fusion mass in scoliosis. *J Bone Joint Surg Am*. 1982 Dec;64(9):1307-16.
- Leatherman KD. Resection of vertebral bodies. *J Bone Joint Surg Am*. 1969;51:206.
- Leatherman KD, Dickson RA. Two-stage corrective surgery for congenital deformities of the spine. *J Bone Joint Surg Br*. 1979 Aug;61-B(3):324-8.
- Luque E. Vertebral column transposition. *Orthop Trans*. 1983;7:29.
- Michele AA, Krueger FJ. Surgical approach to the vertebral body. *J Bone Joint Surg Am*. 1949 Oct;31(4):873-8.
- Royle N. The operative removal of an accessory vertebra. *Med J Aust*. 1928;1:467-8.
- Wiles P. Resection of dorsal vertebrae in congenital scoliosis. *J Bone Joint Surg Am*. 1951 Jan;33(1):151-4.
- Bakaloudis G, Lolli F, Di Silvestre M, Greggi T, Astolfi S, Martikos K, Vommario F, Barbanti-Brodano G, Cioni A, Giacomini S. Thoracic pedicle subtraction osteotomy in the treatment of severe pediatric deformities. *Eur Spine J*. 2011 May;20(Suppl 1):S95-104. Epub 2011 Apr 6.
- Ozturk C, Alanay A, Ganiyusufoglu K, Karadereler S, Ulusoy L, Hamzaoglu A. Short-term X-ray results of posterior vertebral column resection in severe congenital

kyphosis, scoliosis, and kyphoscoliosis. *Spine (Phila Pa 1976)*. 2012 May 20;37(12):1054-7.

19. Wang Y, Zhang Y, Zhang X, Huang P, Xiao S, Wang Z, Liu Z, Liu B, Lu N, Mao K. A single posterior approach for multilevel modified vertebral column resection in adults with severe rigid congenital kyphoscoliosis: a retrospective study of 13 cases. *Eur Spine J*. 2008 Mar;17(3):361-72. Epub 2008 Jan 3.

20. Yang C, Zheng Z, Liu H, Wang J, Kim YJ, Cho S. Posterior vertebral column resection in spinal deformity: a systematic review. *Eur Spine J*. 2016 Aug;25(8):2368-75. Epub 2015 Jan 20.

21. Bridwell KH, Baldus C, Berven S, Edwards C 2nd, Glassman S, Hamill C, Horton W, Lenke LG, Ondra S, Schwab F, Shaffrey C, Wooten D. Changes in radiographic and clinical outcomes with primary treatment adult spinal deformity surgeries from 2 years to 3- to 5-years follow-up. *Spine (Phila Pa 1976)*. 2010 Sep 15;35(20):1849-54.

22. Bridwell KH, Glassman S, Horton W, Shaffrey C, Schwab F, Zebala LP, Lenke LG, Hilton JF, Shainline M, Baldus C, Wooten D. Does treatment (nonoperative and operative) improve the two-year quality of life in patients with adult symptomatic lumbar scoliosis: a prospective multicenter evidence-based medicine study. *Spine (Phila Pa 1976)*. 2009 Sep 15;34(20):2171-8.

23. Kelly MP, Lenke LG, Bridwell KH, Agarwal R, Godzik J, Koester L. Fate of the adult revision spinal deformity patient: a single institution experience. *Spine (Phila Pa 1976)*. 2013 Sep 1;38(19):E1196-200.

24. Smith JS, Klineberg E, Lafage V, Shaffrey CI, Schwab F, Lafage R, Hostin R, Mundis GM Jr, Errico TJ, Kim HJ, Protopsaltis TS, Hamilton DK, Scheer JK, Soroceanu A, Kelly MP, Line B, Gupta M, Deviren V, Hart R, Burton DC, Bess S, Ames CP; International Spine Study Group. Prospective multicenter assessment of perioperative and minimum 2-year postoperative complication rates associated with adult spinal deformity surgery. *J Neurosurg Spine*. 2016 Jul;25(1):1-14. Epub 2016 Feb 26.

25. Smith JS, Shaffrey CI, Berven S, Glassman S, Hamill C, Horton W, Ondra S, Schwab F, Shainline M, Fu KM, Bridwell K; Spinal Deformity Study Group. Operative versus nonoperative treatment of leg pain in adults with scoliosis: a retrospective review of a prospective multicenter database with two-year follow-up. *Spine (Phila Pa 1976)*. 2009 Jul 15;34(16):1693-8.

26. Smith JS, Shaffrey CI, Berven S, Glassman S, Hamill C, Horton W, Ondra S, Schwab F, Shainline M, Fu KM, Bridwell K; Spinal Deformity Study Group. Improve-

ment of back pain with operative and nonoperative treatment in adults with scoliosis. *Neurosurgery*. 2009 Jul;65(1):86-93; discussion 93-4.

27. Schwab F, Blondel B, Chay E, Demakakos J, Lenke L, Tropiano P, Ames C, Smith JS, Shaffrey CI, Glassman S, Farcy JP, Lafage V. The comprehensive anatomical spinal osteotomy classification. *Neurosurgery*. 2014 Jan;74(1):112-20; discussion: 120.

28. Deyo RA, Gray DT, Kreuter W, Mirza S, Martin BI. United States trends in lumbar fusion surgery for degenerative conditions. *Spine (Phila Pa 1976)*. 2005 Jun 15;30(12):1441-5; discussion 1446-7.

29. Deyo RA, Mirza SK, Martin BI, Kreuter W, Goodman DC, Jarvik JG. Trends, major medical complications, and charges associated with surgery for lumbar spinal stenosis in older adults. *JAMA*. 2010 Apr 7;303(13):1259-65.

30. Lenke LG, Newton PO, Sucato DJ, Shufflebarger HL, Emans JB, Sponseller PD, Shah SA, Sides BA, Blanke KM. Complications after 147 consecutive vertebral column resections for severe pediatric spinal deformity: a multicenter analysis. *Spine (Phila Pa 1976)*. 2013 Jan 15;38(2):119-32.

31. Papadopoulos EC, Boachie-Adjei O, Hess WF, Sanchez Perez-Gruoso FJ, Pellisé F, Gupta M, Lonner B, Paonessa K, Faloony M, Cunningham ME, Kim HJ, Mendelow M, Sacramento C, Yazici M; Foundation of Orthopedics and Complex Spine, New York, NY. Early outcomes and complications of posterior vertebral column resection. *Spine J*. 2015 May 1;15(5):983-91. Epub 2013 Apr 25.

32. Chang DG, Yang JH, Lee JH, Kim JH, Suh SW, Kim YH, Ha KY, Suk SI. Pediatric posterior vertebral column resection (PVCR): before and after ten years of age: greater than 10-year follow-up. *Spine (Phila Pa 1976)*. 2016 Nov 1;41(21):E1271-8.

33. Glassman SD, Anagnost SC, Parker A, Burke D, Johnson JR, Dimar JR. The effect of cigarette smoking and smoking cessation on spinal fusion. *Spine (Phila Pa 1976)*. 2000 Oct 15;25(20):2608-15.

34. Vogt MT, Hanscom B, Lauerma WC, Kang JD. Influence of smoking on the health status of spinal patients: the National Spine Network database. *Spine (Phila Pa 1976)*. 2002 Feb 1;27(3):313-9.

35. Kelly MP, Lenke LG, Godzik J, Pellise F, Shaffrey CI, Smith JS, Lewis SJ, Ames CP, Carreon LY, Fehlings MG, Schwab F, Shimer AL. Retrospective analysis underestimates neurological deficits in complex spinal deformity surgery: a Scoliosis-RISK-1 Study. *J Neurosurg Spine*. 2017 Jul;27(1):68-73. Epub 2017 May 5.