

Washington University School of Medicine

Digital Commons@Becker

Open Access Publications

2018

Lenalidomide results in a durable complete remission in acute myeloid leukemia accompanied by persistence of somatic mutations and a T-cell infiltrate in the bone marrow

Dhruv Bansal

Washington University School of Medicine in St. Louis

Kiran Vij

Washington University School of Medicine in St. Louis

Gue Su Chang

Washington University School of Medicine in St. Louis

Christopher A. Miller

Washington University School of Medicine in St. Louis

John F. DiPersio

Washington University School of Medicine in St. Louis

See next page for additional authors

Follow this and additional works at: https://digitalcommons.wustl.edu/open_access_pubs

Please let us know how this document benefits you.

Recommended Citation

Bansal, Dhruv; Vij, Kiran; Chang, Gue Su; Miller, Christopher A.; DiPersio, John F.; Vij, Ravi; Heath, Sharon E.; Westervelt, Peter; Welch, John S.; and Fehniger, Todd A., "Lenalidomide results in a durable complete remission in acute myeloid leukemia accompanied by persistence of somatic mutations and a T-cell infiltrate in the bone marrow." *Haematologica*. 103, 6. e270-e273. (2018).
https://digitalcommons.wustl.edu/open_access_pubs/7252

This Open Access Publication is brought to you for free and open access by Digital Commons@Becker. It has been accepted for inclusion in Open Access Publications by an authorized administrator of Digital Commons@Becker. For more information, please contact vanam@wustl.edu.

Authors

Dhruv Bansal, Kiran Vij, Gue Su Chang, Christopher A. Miller, John F. DiPersio, Ravi Vij, Sharon E. Heath, Peter Westervelt, John S. Welch, and Todd A. Fehniger

Lenalidomide results in a durable complete remission in acute myeloid leukemia accompanied by persistence of somatic mutations and a T-cell infiltrate in the bone marrow

Mechanisms of *in vivo* AML response and resistance to chemotherapy remain poorly characterized. To determine whether response to lenalidomide might share features with response to other forms of chemotherapy, we applied immunohistochemistry and gene panel sequencing to serial samples from a patient with a remarkable 21 month clinical response. Unlike other forms of chemotherapy, lenalidomide response was not associated with transition through an aplastic phase, but was accompanied by a CD8⁺ T-cell infiltration in the bone marrow (BM). However, like cytarabine and decitabine responses, we observed differential sensitivity within one subclone and resistance within another subclone, suggesting that important determinants of lenalidomide-sensitivity may be cell intrinsic. These findings could be recapitulated in a small series of additional lenalidomide treated patients, although larger patient cohorts will be required to determine the precise mechanistic differences between subclones that are sensitive to lenalidomide and those that are resistant to lenalidomide.

Lenalidomide has been shown to induce complete remissions in patients with AML.¹⁻³ A wide range of mechanisms have been proposed, including direct effects on AML blasts,⁴ anti-angiogenic properties, altered signal transduction, immunomodulatory effects that affect cytokine production, T-cell activation, and augmentation of NK cell function.⁵ To better understand mechanisms of lenalidomide response, we carefully examined the response of the patient with the longest morphologic complete remission in our study.

Patient S058-034 was a 76-year-old female who presented with cytopenias (white blood cell count $3.6 \times 10^3/\mu\text{L}$, hemoglobin 6.7 g/dL, platelets $21 \times 10^3/\mu\text{L}$) and 16% circulating myeloblasts in the peripheral blood (PB). Her BM biopsy revealed 50% cellularity with myeloid dysplasia affecting neutrophils and megakaryocytes, 26% myeloblasts by morphology, and 21% myeloblasts via flow cytometry with an immunophenotype of CD34-CD33-CD117-CD56⁺, supporting the diagnosis of AML with MDS-related features. Cytogenetics revealed a clonal abnormality: 46,XX,der(3)t(1;3)(q25;q29) [14]/46,XX[6]. FISH studies were negative for *PML-RARA*, *MLL*, *AML1-ETO*, and *CBFB* gene rearrangements. *FLT3* and *NPM1* mutation testing was negative.

The patient was treated with a course of high-dose

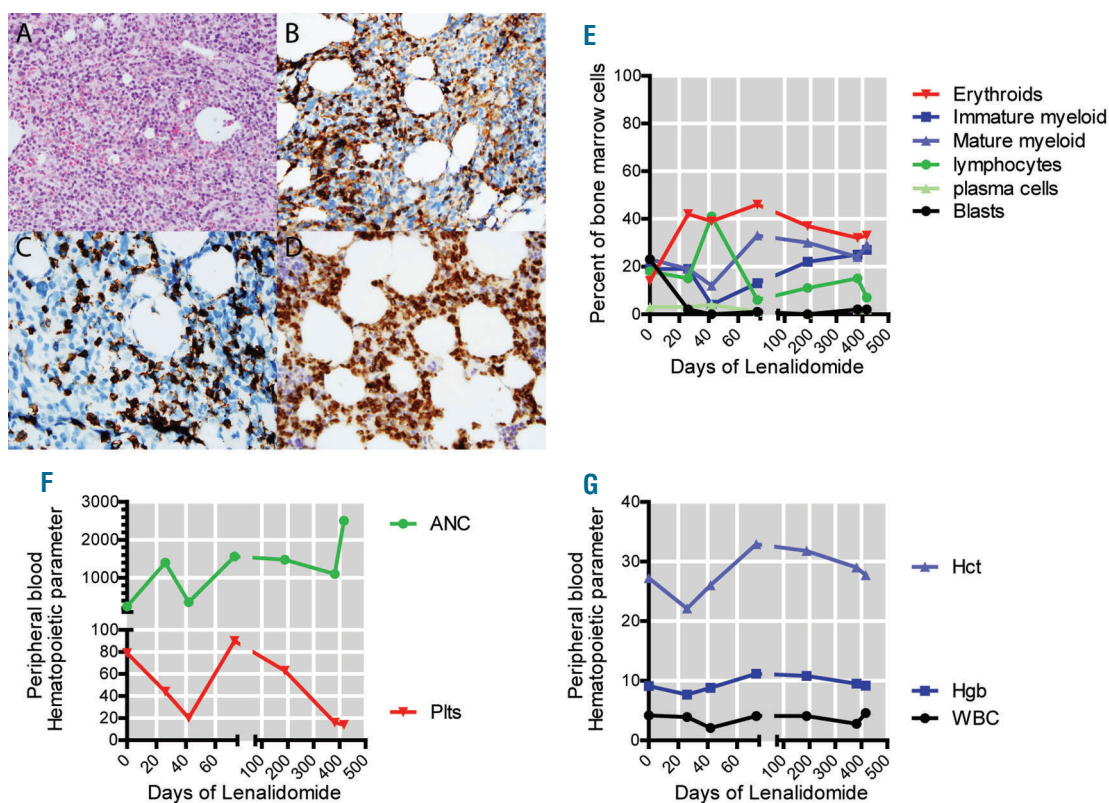


Figure 1. T-cell infiltration present in the BM at the time of CR and BM morphology over time. (A-D) Pathology of BM core biopsy at time of CR (Day 30 after initiating lenalidomide). (A) Hematoxylin & eosin stained core biopsy that was hypercellular with increased lymphocytes. Immunohistochemistry analysis using CD8 (B), CD4 (C) and TIA-1, a marker of cytotoxic T cells (D) demonstrates decreased CD4 to CD8 ratio in T cells with increased co-expression of TIA-1 in the CD8⁺ T-cells. Original magnification X 20 objective (Panels A-D). (E) BM morphology during lenalidomide treatment determined by a 200-differential cell count. Immature myeloid cells include promyelocytes, myelocytes, and metamyelocytes. Mature myeloid cells include bands, neutrophils, eosinophils, basophils, and monocytes. (F-G) Peripheral blood absolute neutrophil counts (ANC), platelet counts (Plts), hematocrit (Hct), hemoglobin (Hgb), and white blood cell counts (WBC) observed during lenalidomide therapy.

induction lenalidomide (50 mg PO daily for 28 days) on a clinical protocol (*clinicaltrials.gov* identifier 00546897). Leukemia blasts rapidly cleared from her PB, and a day 15 BM biopsy revealed a morphologic leukemia free state (MLFS) with 70% cellularity, confirmed at day 28 with a normal karyotype, and at day 61 her PB neutrophil count normalized (absolute neutrophil count: 1,558/ μ L). The patient was then treated with twelve cycles of low dose lenalidomide (10 mg/day PO on days 1-28 of 28-day cycles). She remained in CRi for 21 months, which was confirmed by BM biopsies performed at 2, 6, 9, and 12 months. During this period, the patient had persistent thrombocytopenia (platelets 14-90 \times 10³/ μ L) and anemia (Hgb 8.2-12.4 g/dL) attributed to ongoing lenalidomide

therapy, and the lenalidomide was discontinued after 12 months of therapy per protocol. She remained in remission for an additional 9 months, and then had an extramedullary relapse involving the scalp. A concurrent BM biopsy revealed 90% cellularity with multilineage dysplasia and no excess blasts. She was reinitiated on 10 mg/day of lenalidomide, but experienced disease progression with circulating peripheral blood blasts and was transitioned to palliative care.

Like other patients achieving response to lenalidomide on this study,¹ this patient did not experience a period of BM aplasia, suggesting that the mechanism of action of high-dose lenalidomide is not direct myeloablation. In this patient, clearance of blasts on day 15 was followed

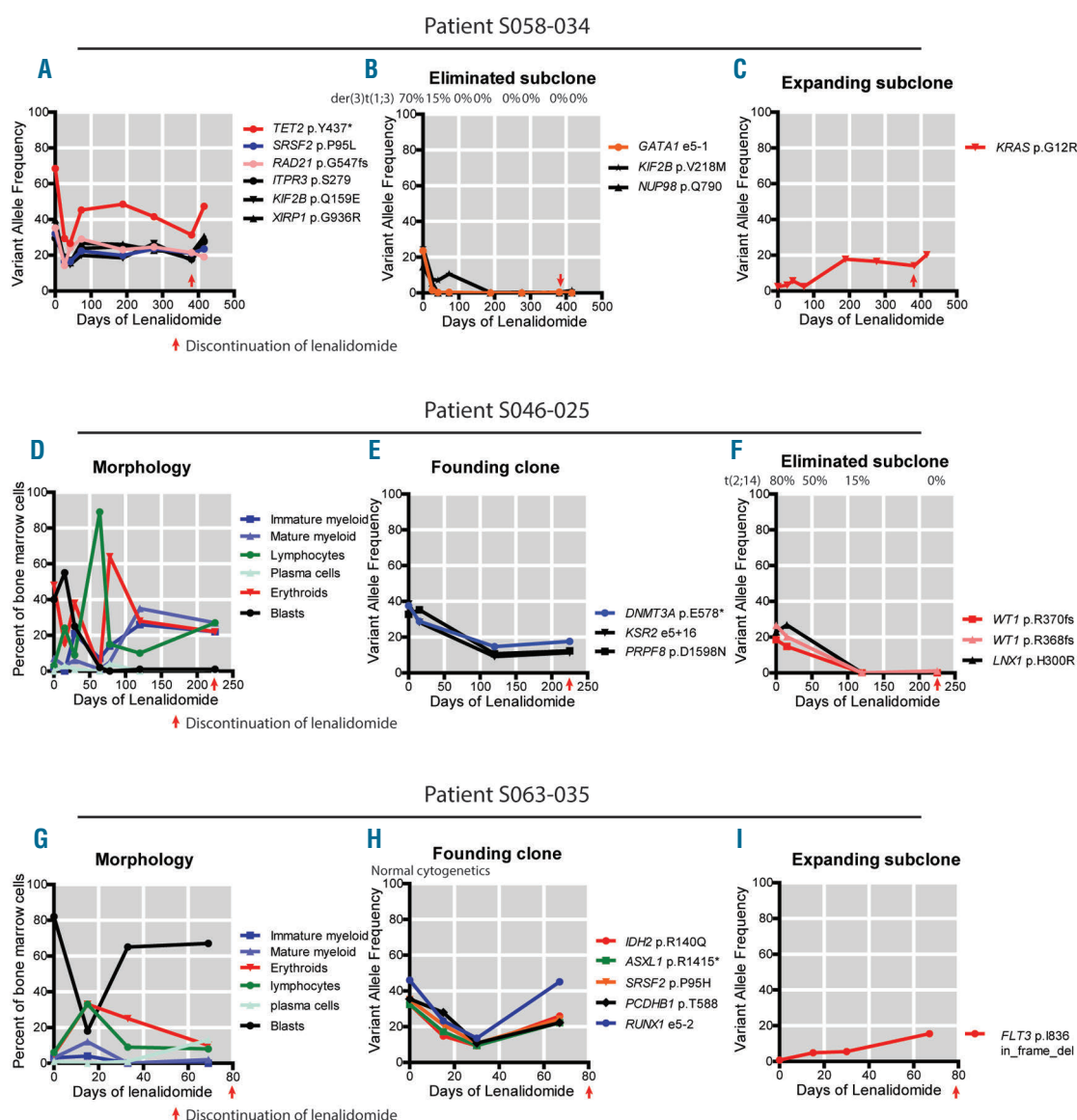


Figure 2. Differential sensitivity to lenalidomide within subclones of three patients. (A-C) The variant allele frequencies of mutations identified in patient S058-034 could be separated into a founding clone (A), an eliminated clone (B), and an expanding clone (C). The eliminated clone and the expanding clone are imputed to be subclones of the founding clone. (D) BM morphology observed in patient S046-025, who achieved CRc. (E-F) The variant allele frequencies of mutations observed in patient S046-025 could be separated into a founding clone (E) and an eliminated clone (F). The eliminated clone is imputed to be a subclone of the founding clone. (G) BM morphology observed in patient S063-035, who maintained stable disease, although they did experience a transient reduction in bone marrow blasts on day 15. (H-I) The variant allele frequencies of mutations observed in patient S063-035 could be separated into a founding clone (H) and an expanding clone (I). The expanding clone is imputed to be a subclone of the founding clone. For all cases, clinical cytogenetic results are indicated above the panel corresponding to the patient and the appropriate founding clone or subclone, and the end of lenalidomide indicated with a red arrow.

by an unusual lymphoid infiltrate on day 30 (41% lymphocytes by morphologic review). Immunohistochemistry studies were performed on the BM core biopsy, which revealed an increased number of CD3⁺ T cells with a decreased CD4 to CD8 ratio (30% CD4⁺, 70% CD8⁺ quantified by IHC), and the CD8⁺ T cells co-expressed TIA-1 and granzyme B suggesting activated, cytotoxic effector cells (Figure 1A–D). The CD8⁺ bias in BM T cells persisted for 12 months, although the proportion of BM lymphocytes normalized. T-cell receptor gamma (TCRG) gene rearrangement studies on day 348 showed a population of T cells with a clonal TCR, but on a subsequent BM 2 weeks later was no clonal TCR population was detected. This marked, persistent T-cell infiltration in the BM raises the possibility that a T-cell mediated immune response may have contributed to this patient's blast clearance and CRi.

The patient's mutation profile was assessed at eight separate time points using a previously described methodology and 264 gene panel.⁶⁷ Ten somatic variants were detected at one or more time points (8 single nucleotide variants, one dinucleotide variant, and one deletion, Figure 2A–C). Six variants formed a founding clone that persisted throughout treatment (*TET2*, *RAD21*, *SRSF2*, *XIRP1*, *KIF2B*, *ITPR3*). Three variants formed a subclone that was eliminated by lenalidomide (*GATA1*, *KIF2B*, *NUP98*). One variant was associated with a subclone that expanded during lenalidomide treatment (*KRAS* G12R) (Figure 2A–C).

Two important themes emerged from this single case. First, lenalidomide-associated morphologic responses are not associated with complete clearance of driver mutations. Instead, blast clearance correlated with elimination of the *GATA1* subclone, while the founding clone variants persisted during prolonged morphologic remission. Secondly, response and resistance to lenalidomide may be cell intrinsic, since differential sensitivity was observed between the *GATA1* subclone (sensitive, Figure 2B) and the *KRAS* subclone (resistant, Figure 2C).

Serial BM samples were available for sequencing from 5 additional cases of AML patients treated with lenalidomide, who also had provided written, informed consent for genome sequencing via a secondary banking protocol (only this subset of patients had adequate samples for analysis and had provided adequate consent for genomic analysis). These additional cases were examined to determine whether these features were common to lenalidomide responders (2 with morphologic complete remission and 3 with stable disease). Case S046-025 achieved a CRc that also was associated with blast clearance followed by a lymphocyte infiltrate with increased granzyme B⁺ CD8⁺ T-cells, the persistence of the founding clone, and elimination of a subclone (Figure 2D–E). Case S063-035 maintained stable disease, but this was associated with a transient blast decrease, a wave of CD3⁺/CD8⁺ T-cell infiltration, and then subsequent expansion of a *FLT3* mutated subclone. The other three cases were all associated with stable clonal architecture (Online Supplementary Figure S1).

Five of the cases had clinically-available MHC I haplotype characterization. Using pVACseq,⁸ we found that in three of these cases, somatic variants created tumor-specific neoepitopes with high-quality predicted binding (IC₅₀ < 500 nM, mutant IC₅₀ > wild-type IC₅₀) to patient-specific MHC class I complexes (Online Supplementary Table S4). In one case, S046-025 (Figure 2F) the variants with predicted neo-epitopes were eliminated during lenalidomide treatment, suggesting the possibility of subclone-specific immunologic response. Samples necessary

to adequately evaluate for functional T-cell responses to these neo-epitopes were not available.

Collectively, this small case series, focused on a remarkable responder who achieved and maintained remission for 21 months with single agent lenalidomide, demonstrates three main findings. First, lenalidomide response was not associated with an aplastic phase, but was associated with an infiltration of activated CD8⁺ T cells into the BM, suggesting that immune stimulation and surveillance may play an important role in response determination. Secondly, founding clone mutations may persist during morphologic remission. We have previously observed similar findings following cytarabine-based therapy,⁷ which suggests that both forms of therapy may eliminate clones that emerged late during leukemic development, but may permit the persistence of clones that emerged early during clonal evolution. Finally, we observed evidence of differential therapy-sensitivity among subclones derived from the same founding clone, which we have also observed in patients treated with cytarabine^{7,9} and decitabine,¹⁰ suggesting that important determinants of response to all three forms of chemotherapy is cell intrinsic. Similar findings have been recently observed in patients with non-del(5q) transfusion-dependent low/intermediate-1 MDS on low dose (10 mg) lenalidomide.¹¹ Additional studies will be required to better understand the differential sensitivity and resistance that may occur within different subclones.

Dhruv Bansal,¹ Kiran Vij,¹ Gue Su Chang,²
Christopher A. Miller,² John F. DiPersio,¹ Ravi Vij,¹
Sharon E. Heath,¹ Peter Westervelt,¹ John S. Welch¹
and Todd A. Fehniger¹

¹Department of Medicine, Division of Oncology, BMT and Leukemia Program, Washington University School of Medicine, Saint Louis, MO and ²McDonnell Genome Institute, Washington University School of Medicine, Saint Louis, MO, USA

*JSW and TAF contributed equally to this work

Acknowledgments: these patients were treated, and samples were collected, as part of the investigator-initiated phase 2 clinical trial NCT00546897, supported by Celgene.

Funding: support was also provided by NCI Leukemia SPOR (P50 CA171963) and the Genomics of AML Program Project grant (P01 CA101937). TAF is supported by R01CA205239. We thank Greg Malnassy, Nichole Helton, and the Washington University Tissue Procurement Core for sample storage and sample preparation. We thank Timothy Schappe for assistance with sample collection. We thank all BMT/Leukemia treatment teams and all patients who elected to participate in this clinical trial.

Correspondence: tfehnige@wustl.edu/jwelch@wustl.edu
doi:10.3324/haematol.2017.184168

Information on authorship, contributions, and financial & other disclosures was provided by the authors and is available with the online version of this article at www.haematologica.org.

References

1. Fehniger TA, Uy GL, Trinkaus K, et al. A phase 2 study of high-dose lenalidomide as initial therapy for older patients with acute myeloid leukemia. *Blood*. 2011;117(6):1828-1833.
2. Fehniger TA, Byrd JC, Marcucci G, et al. Brief report Single-agent lenalidomide induces complete remission of acute myeloid leukemia in patients with isolated trisomy 13 Case reports. *Blood*. 2009; 113(5):1002-1005.
3. Blum W, Klisovic RB, Becker H, et al. Dose escalation of lenalidomide in relapsed or refractory acute leukemias. *J Clin Oncol*. 2010; 28(33):4919-4925.
4. Hickey CJ, Schwind S, Radomska HS, et al. Lenalidomide-mediated enhanced translation of C/EBPα-p30 protein up-regulates expression

- of the antileukemic microRNA-181a in acute myeloid leukemia. *Blood*. 2013;121(1):159-169.
5. Kotla V, Goel S, Nischal S, et al. Mechanism of action of lenalidomide in hematological malignancies. *J Hematol Oncol*. 2009;2:36.
 6. Welch JS, Westervelt P, Ding L, et al. Use of whole-genome sequencing to diagnose a cryptic fusion oncogene. *JAMA*. 2011;305(15):1577-1584.
 7. Klotz JM, Miller CA, Griffith M, et al. Association between mutation clearance after induction therapy and outcomes in acute myeloid leukemia. *JAMA*. 2015;314(8):811.
 8. Hundal J, Carreno BM, Petti AA, et al. pVAC-Seq: A genome-guided in silico approach to identifying tumor neoantigens. *Genome Med*. 2016;8(1):11.
 9. Ding L, Ley TJ, Larson DE, et al. Clonal evolution in relapsed acute myeloid leukaemia revealed by whole-genome sequencing. *Nature*. 2012;481(7382):506-510.
 10. Welch JS, Petti AA, Miller CA, et al. TP53 and decitabine in acute myeloid leukemia and myelodysplastic syndromes. *N Engl J Med*. 2016;375(21):2023-2036.
 11. Chesnais V, Renneville A, Toma A, et al. Effect of lenalidomide treatment on clonal architecture of myelodysplastic syndromes without 5q deletion. *Blood*. 2016;127(6):749-760.