

Washington University School of Medicine

Digital Commons@Becker

---

Open Access Publications

---

2018

## Extragenital condyloma acuminatum in the left axillary vault

Tina Hsu

*Washington University School of Medicine in St. Louis*

Zachary P. Nahmias

*Washington University School of Medicine in St. Louis*

Ilana S. Rosman

*Washington University School of Medicine in St. Louis*

David Sheinbein

*Washington University School of Medicine in St. Louis*

Follow this and additional works at: [https://digitalcommons.wustl.edu/open\\_access\\_pubs](https://digitalcommons.wustl.edu/open_access_pubs)

Please let us know how this document benefits you.

---

### Recommended Citation

Hsu, Tina; Nahmias, Zachary P.; Rosman, Ilana S.; and Sheinbein, David, "Extragenital condyloma acuminatum in the left axillary vault." *JAAD Case Reports*. 4, 9. 947-949. (2018).

[https://digitalcommons.wustl.edu/open\\_access\\_pubs/7261](https://digitalcommons.wustl.edu/open_access_pubs/7261)

This Open Access Publication is brought to you for free and open access by Digital Commons@Becker. It has been accepted for inclusion in Open Access Publications by an authorized administrator of Digital Commons@Becker. For more information, please contact [vanam@wustl.edu](mailto:vanam@wustl.edu).

# Extragenital condyloma acuminatum in the left axillary vault



Tina Hsu, BA,<sup>a</sup> Zachary P. Nahmias, MD,<sup>b</sup> Ilana S. Rosman, MD,<sup>b</sup> and David Sheinbein, MD<sup>b</sup>  
St Louis, Missouri

**Key words:** axillary condyloma; condyloma acuminatum; extragenital condyloma.

## INTRODUCTION

Condyloma acuminatum is a benign epithelial proliferation attributed to the epidermotropic human papillomavirus (HPV) and generally associated with sexual transmission. More than 100 types of HPV have been discovered, but strains 6 and 11 are found to cause approximately 90% of condyloma acuminatum. Lesions occur most frequently on the mucous membranes of the anogenital region, but also may occur in the conjunctiva and oral mucosa. Extragenital condyloma acuminatum not associated with sexual activity is rare, having previously only been described in the groin and inframammary fold.<sup>1</sup> We report a patient with condyloma acuminatum occurring on the skin of the axilla.

## REPORT OF A CASE

A 30-year-old African-American man presented with a 3-year history of growths in the left axilla. The lesions were painful, especially when caught on clothing, and were increasing in size. On examination, there were numerous cerebriform and verrucous pedunculated papules in the left axilla coalescing into a 2-cm plaque (Fig 1). The patient denied a history of oral or genital lesions, and there were no lesions at the time of examination. The clinical differential diagnosis included epidermal nevus, acrochordon, and condyloma acuminatum. A shave biopsy was performed. On histopathology, there was papillated epidermal hyperplasia with hyperkeratosis, hypergranulosis, and dilated blood vessels at the tips of the dermal papillae and koilocytic changes within the superficial spinous layers, compatible with a diagnosis of condyloma acuminatum (Fig 2). At higher power, there was koilocytic change within the keratinocytes of the

### Abbreviation used:

HPV: human papillomavirus

superficial spinous layers (Fig 3). Additional in situ hybridization studies for human papillomavirus were performed; the lesion was positive for low-risk strains (6 and 11) but negative for high-risk strains (16 and 18) (Fig 4). The patient did not return to the clinic after the diagnosis.

## DISCUSSION

To our knowledge, this is the first report in the literature of axillary condyloma acuminatum without a history of genital warts. The lesion is defined both by its exophytic, verrucous appearance of condyloma acuminatum and its findings on pathology, including koilocytotic change, hypergranulosis, and papillated epidermal hyperplasia. The differential diagnosis includes fibroepithelial polyp, verruca vulgaris, and squamous papilloma. Fibroepithelial polyps usually lack the complex exophytic features of condyloma acuminatum. Squamous papillomas do not have koilocytic changes or acanthosis. Condyloma acuminatum has been reported intraorally and within intertriginous areas, such as the groin and the inframammary fold, but it is rare to see lesions in other areas of the body without their presence in the anogenital area.<sup>2</sup>

The patient could have acquired condyloma acuminatum through several mechanisms. He may have been immunocompromised, which would have produced a favorable environment for infection by HPV with subsequent epidermal transformation. Testing for HIV was not performed

From Washington University School of Medicine<sup>a</sup> and Division of Dermatology, Washington University School of Medicine.<sup>b</sup>

Funding sources: None.

Conflicts of interest: None disclosed.

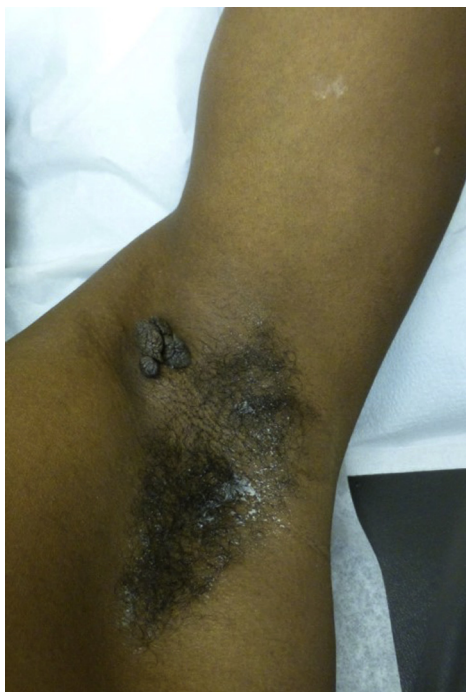Correspondence to: Zachary P. Nahmias, MD, Division of Dermatology, Washington University School of Medicine, 660 S Euclid Ave, Campus Box 8123, St Louis, MO 63110. E-mail: [nahmias@wustl.edu](mailto:nahmias@wustl.edu).

JAAD Case Reports 2018;4:947-9.

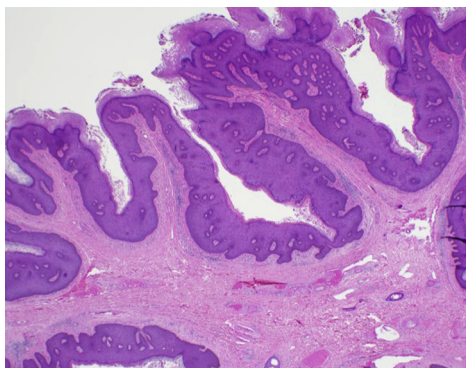
2352-5126

© 2018 by the American Academy of Dermatology, Inc. Published by Elsevier, Inc. This is an open access article under the CC BY-NC-ND license (<http://creativecommons.org/licenses/by-nc-nd/4.0/>).

<https://doi.org/10.1016/j.jdcrr.2018.07.022>

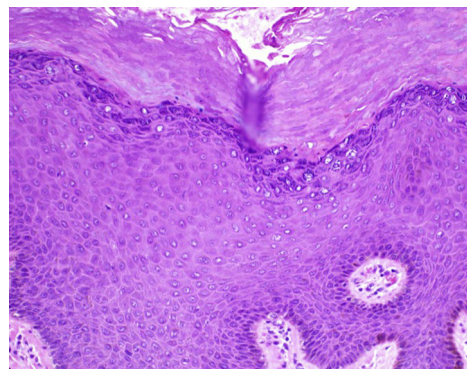


**Fig 1.** Clinical presentation of extragenital condyloma acuminatum. There are verrucous pedunculated papules coalescing into a 2-cm plaque in the left axilla.

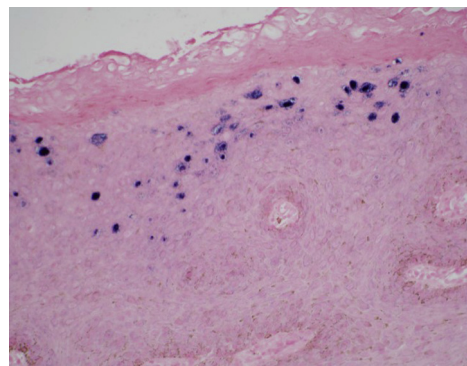


**Fig 2.** Histopathology of extragenital condyloma acuminatum. There is hyperkeratosis, hypergranulosis, and papillated epidermal hyperplasia. (Hematoxylin-eosin stain; original magnification:  $\times 20$ .)

in this patient, given the lack of follow-up, but would be a reasonable next step in evaluating a patient with extragenital condyloma acuminatum. Another possibility is viral transmission from the genital region to the axilla by a contaminated object, such as a razor used for shaving both areas. Although unusual, maschalagnia, or armpit fetishism, may sometimes lead to armpit intercourse, which could provide a means of transmission of the HPV virus.<sup>3</sup> No specific antiviral treatment is currently recommended for condyloma acuminatum, but some successful



**Fig 3.** Histopathology of extragenital condyloma acuminatum. At higher power, there is koilocytic change within the keratinocytes of the superficial spinous layers. (Hematoxylin-eosin stain; original magnification:  $\times 200$ .)



**Fig 4.** HPV in situ hybridization testing. Keratinocytes show positivity with low-risk HPV strains (6 and 11) in situ hybridization. (Original magnification:  $\times 200$ .)

treatments include intralesional interferon, topical imiquimod, and electrocoagulation.<sup>4</sup>

HPV is a ubiquitous virus. Strains of HPV are causative in various verruca with some site-specific tendencies. For example, HPV types 2 and 4 cause verruca vulgaris, which occurs primarily on the hands and feet but can be seen on other areas of the body. Verruca plantaris is typically caused by HPV type 1. It is thought that each HPV type is only able to infect a few specific areas on the body. However, given the vast number and diversity of HPV subtypes, some which have only been detected by preliminary data and have yet to be fully described, and the virus's ability to establish long-term latent infections in stem cells, it is possible that HPV types 6 and 11 could spontaneously infect extragenital areas such as the axilla, as viral strains could be more promiscuous in sites of infection than classically thought.

Given the rarity of extragenital condyloma acuminatum, it is imperative that clinicians be aware

of, and inquire about, a patient's medical and surgical history, including HIV status, transplant status, sexual practices, and other factors that may predispose to the condition. Additionally, because high-risk strains of HPV (16, 18, 31, and 33) are associated with malignant transformation in condyloma acuminatum in the anogenital area, HPV testing in suspected extragenital condyloma acuminatum is warranted to guide treatment and prognosis.

#### REFERENCES

1. Ashiru JO, Ogunbanjo BO, Rotowa NA, Adeyemi-Doro FA, Osoba AO. Intraoral condylomata acuminata: a case report. *Sex Transm Infect.* 1983;59(5):325-326.
2. Googe PB, Chung SJ, Simmons J, King R. Giant-sized condyloma of the breast with focal acantholytic changes. *J Cutan Pathol.* 2000;27(6):319-322.
3. Aggrawal A. References to the paraphilias and sexual crimes in the Bible. *J Forensic Leg Med.* 2009;16(3):109-114.
4. Centers for Disease Control and Prevention. *Sexually Transmitted Diseases Treatment Guidelines, 2015.* Vol 64; 2015. <https://doi.org/10.1097/00008480-200308000-00006>.