

2017

Epidemiology and outcomes of vertebral artery injury in 16582 cervical spine surgery patients: An AOSpine North America multicenter study

Wilson Z. Ray

et al.

Epidemiology and Outcomes of Vertebral Artery Injury in 16 582 Cervical Spine Surgery Patients: An AOSpine North America Multicenter Study

Global Spine Journal
2017, Vol. 7(1S) 21S-27S
© The Author(s) 2017
Reprints and permission:
sagepub.com/journalsPermissions.nav
DOI: 10.1177/2192568216686753
journals.sagepub.com/home/gsj



Wellington K. Hsu, MD¹, Abhishek Kannan, BS², Harry T. Mai, BS, BA³, Michael G. Fehlings, MD, PhD⁴, Zachary A. Smith, MD¹, Vincent C. Traynelis, MD⁵, Ziya L. Gokaslan, MD, FAANS, FACS^{6,7,8,9}, Alan S. Hilibrand, MD¹⁰, Ahmad Nassr, MD¹¹, Paul M. Arnold, MD, FACS¹², Thomas E. Mroz, MD¹³, Mohamad Bydon, MD¹¹, Eric M. Massicotte, MD, MSc, FRCSC^{4,14}, Wilson Z. Ray, MD¹⁵, Michael P. Steinmetz, MD¹⁶, Gabriel A. Smith, MD¹⁷, Jonathan Pace, MD¹⁷, Mark Corriveau, MD¹⁷, Sungho Lee, MD, PhD¹⁷, Robert E. Isaacs, MD¹⁸, Jeffrey C. Wang, MD¹⁹, Elizabeth L. Lord, MD³, Zorica Buser, PhD²⁰, and K. Daniel Riew, MD^{21,22}

Abstract

Study Design: A multicenter retrospective case series was compiled involving 21 medical institutions. Inclusion criteria included patients who underwent cervical spine surgery between 2005 and 2011 and who sustained a vertebral artery injury (VAI).

Objective: To report the frequency, risk factors, outcomes, and management goals of VAI in patients who have undergone cervical spine surgery.

Methods: Patients were evaluated on the basis of condition-specific functional status using the Neck Disability Index (NDI), modified Japanese Orthopaedic Association (mJOA) score, the Nurick scale, and the 36-Item Short-Form Health Survey (SF-36).

Results: VAIs were identified in a total of 14 of 16 582 patients screened (8.4 per 10 000). The mean age of patients with VAI was 59 years (± 10) with a female predominance (78.6%). Patient diagnoses included myelopathy, radiculopathy, cervical instability, and metastatic disease. VAI was associated with substantial blood loss (770 mL), although only 3 cases required transfusion. Of the 14 cases, 7 occurred with an anterior-only approach, 3 cases with posterior-only approach, and 4 during circumferential approach. Fifty percent of cases of VAI with available preoperative imaging revealed anomalous vessel anatomy during post-operative review. Average length of hospital stay was 10 days (± 8). Notably, 13 of the 14 (92.86%) cases resolved without residual deficits. Compared to preoperative baseline NDI, Nurick, mJOA, and SF-36 scores for these patients, there were no observed changes after surgery ($P = .20-.94$).

Conclusions: Vertebral artery injuries are potentially catastrophic complications that can be sustained from anterior or posterior cervical spine approaches. The data from this study suggest that with proper steps to ensure hemostasis, patients recover function at a high rate and do not exhibit residual deficits.

¹ Northwestern University, Feinberg School of Medicine, Chicago, IL, USA

² Northwestern Memorial Hospital, Chicago, IL, USA

³ University of California Los Angeles, CA, USA

⁴ Toronto Western Hospital, Toronto, Ontario, Canada

⁵ Rush University Medical Center, Chicago, IL, USA

⁶ Brown University, Providence, RI, USA

⁷ Rhode Island Hospital, Providence, RI, USA

⁸ The Miriam Hospital, Providence, RI, USA

⁹ Norman Prince Neurosciences Institute, Providence, RI, USA

¹⁰ Jefferson Medical College, The Rothman Institute, Philadelphia, PA, USA

¹¹ Mayo Clinic, Rochester, MN, USA

¹² Kansas University Medical Center, Kansas City, KS, USA

¹³ Cleveland Clinic, Cleveland, OH, USA

¹⁴ University of Toronto, Toronto, Ontario, Canada

¹⁵ Washington University, St Louis, MO, USA

¹⁶ Cleveland Clinic Foundation, Cleveland, OH, USA

¹⁷ University Hospitals Case Medical Center, Cleveland, OH, USA

¹⁸ Duke University Medical Center, Durham, NC, USA

¹⁹ USC Spine Center, Los Angeles, CA, USA

²⁰ University of Southern California, Los Angeles, CA, USA

²¹ Columbia University, New York, NY, USA

²² New York-Presbyterian/The Allen Hospital, New York, NY, USA

Corresponding Author:

Abhishek Kannan, Northwestern Memorial Hospital, 676 N St, Clair St, #1350, Chicago, IL 60611, USA.

Email: akannan89@gmail.com



This article is distributed under the terms of the Creative Commons Attribution-NonCommercial-NoDerivs 4.0 License (<http://www.creativecommons.org/licenses/by-nc-nd/4.0/>) which permits non-commercial use, reproduction and distribution of the work as published without adaptation or alteration, without further permission provided the original work is attributed as specified on the SAGE and Open Access pages (<https://us.sagepub.com/en-us/nam/open-access-at-sage>).

Keywords

vertebral, artery, cervical, spine, injury, complication, management

Introduction

While complications during cervical spine surgery are infrequent, the repercussions of such events can be catastrophic. Choice of surgical approach poses varying risks, making anatomic considerations essential to preoperative planning, intraoperative decision making, and postoperative care. An anterior approach to the cervical spine is associated with potential complications such as dysphagia, recurrent laryngeal nerve palsy, Horner's syndrome, and esophageal perforation.^{1,2} Posterior approaches are also associated with significant adverse events such as epidural hematomas, dural tear, nerve root injuries, and spinal cord infarcts.²

An iatrogenic vertebral artery injury (VAI) is a potentially devastating complication. The vertebral artery arises as the first branch of the subclavian artery and is divided into 4 segments—V1 through V4 (Figure 1). It most commonly begins its transforaminal cephalad ascent at the C6 transverse foramen (87% to 89%), with other variations entering one level above or below. The VA is most vulnerable to injury anterior to C7, laterally along C3 to C7, and posteriorly at C1 and C2.³ There can be substantial vascular and skeletal variations in the upper cervical spine.^{4,5} The 2 vertebral arteries in the human body, each one originating from bilateral subclavian arteries, conjoin to form the basilar artery cephalad to the foramen magnum. The basilar artery supplies the posterior portion of the Circle of Willis and is a major contributor to posterior cerebral circulation.

Advanced imaging is an essential part of the preoperative assessment in cervical spine surgery and may aid in the identification of a tortuous or anomalous VA. The incidence of anomalous VA ranges from 2.7% in cadaveric studies⁶ to 5.4% in imaging studies.⁷ Assessment with computed tomography angiography (CTA) or magnetic resonance angiography (MRA) highlights anatomic features including interforaminal distance, spinal canal width, and vessel course. These parameters may affect procedural strategy and surgeon preference with regard to approach, dissection, and decompression.

Clinical sequelae of VAI include pseudoaneurysm, late-onset hemorrhage, thrombosis, embolism, and cerebral ischemia. VAI can result in permanent neurologic impairment, catastrophic bleeding, and mortality.⁸⁻¹⁰ In the event of VAI, management goals include controlling local hemorrhage, preventing vertebrobasilar ischemia, and preventing cerebrovascular embolic complications.¹¹ Treatment considerations, however, differ in the event of VAI during surgical as compared to the trauma setting.

A number of techniques to manage a VAI exist, including hemostatic tamponade, microvascular repair, or ligation. Intraoperative endovascular procedures (including stenting, VA occlusion, coil embolization), clipping, and ligation may be considered if tamponade fails, but carry the risk of associated neurologic complications.⁸ Direct vascular repair restores

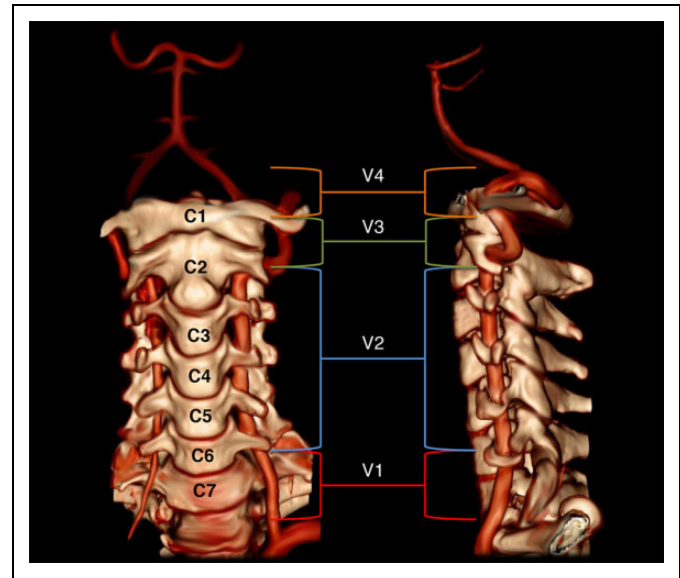


Figure 1. Vertebral artery segments V1 through V4. (Case courtesy of Dr Robert Jones, Radiopaedia.org).

blood flow while decreasing the risk of subsequent neurologic impairment secondary to ischemic or embolic events.

The true incidence of VAI remains unclear, as evidence-based figures including those from single- and multicenter studies have reported an incidence ranging from 0.07%¹² to 1.4%.¹³ The majority of the literature regarding this particular complication includes single-surgeon or small multicenter studies. Some studies have attempted to report incidence rates based on physician surveys and are thus subject to recall and reporting bias.¹² Others have even delineated varying incidences of VAI between spine surgeons and nonspine orthopedists.¹⁴ Reported rates vary depending on surgical approach (0.3% to 0.5% for anterior and 4.1% to 8.2% for posterior).^{9-11,15} This current multicenter study spanning 21 institutions attempts to present a more accurate representation of the true incidence of VAI, elucidate risk factors for iatrogenic vessel injury, and highlight management strategies used for this potentially devastating complication.¹²

Methods

We have conducted a retrospective multicenter case series study involving 21 high-volume surgical centers from the AOSpine North America Clinical Research Network, selected for their excellence in spine care and clinical research infrastructure and experience. This study was ethically approved by the institutional ethics committees at all participating sites. Data were sent to a private research organization that collected and collated all of the data. Medical records for 16 582 patients who received cervical spine surgery (levels from C2 to C7)

Table 1. Location and Repair Methods of Various Cases of Vertebral Artery Injury.

	Level	Location	When Injury Occurred	Method of Repair
1	C2	Right transverse foramen	Tapping C1 pilot hole	Angioplasty with stenting
2	C2	Right side	Blunt dissection	Indirect
3	C3		Burr	Ligation
4	C4	Left	Burr	Packing with gelfoam
5	C4		Burr	Packing and serial angiography
6	C4-C5	Left approach	Electrocautery	Coiling
7	C5	Right		
8	C5-C6	Right	Unknown	Indirect
9	C6	Left	Blunt dissection	Direct
10	C7	Longus colli	Dissection	Clipping
11	C7	Left	Unknown	Indirect
12	Unknown	Left approach		Ligation
13	Unknown	Unknown		
14	Unknown	Unknown		

between January 1, 2005, and December 31, 2011, inclusive, were reviewed to identify occurrence of 21 predefined treatment complications. The complications included reintubation requiring evacuation, esophageal perforation, epidural hematoma, C5 palsy, recurrent laryngeal nerve palsy, superior laryngeal nerve palsy, hypoglossal or glossopharyngeal nerve palsy, dural tear, brachial plexopathy, blindness, graft extrusion, misplaced screws requiring reoperation, anterior cervical infection, carotid artery injury or cerebrovascular accident, vertebral artery injuries, Horner's syndrome, thoracic duct injury, tetraplegia, intraoperative death, revision of arthroplasty and, pseudomeningocele. Patients were evaluated on the basis of condition-specific functional status using the Neck Disability Index (NDI), modified Japanese Orthopaedic Association (mJOA) score, the Nurick scale, and the 36-Item Short-Form Health Survey (SF-36).

Trained research staff at each site abstracted the data from medical records, surgical charts, radiology imaging, narratives, and other source documents for the patients who experienced one or more of the complications from the list. Data were transcribed into study-specific paper case report forms (CRFs). Copies of CRF forms were transferred to the AOSpine North America Clinical Research Network Methodological Core for processing, cleaning, and data entry. Descriptive statistics were provided for baseline patient characteristics. Paired *t* test was used to analyze changes in clinical outcomes at follow-up compared to preoperative status.

Results

Of the 16 582 patients in this database, a total of 14 (0.08%) cases of VAI were identified (8.4 per 10 000). The incidence of VAI during cervical spine surgery at each of the 21 surgical centers surveyed ranged from 0% to 1.2%. The mean age of patients with VAI was 58.8 years (SD of 10.4 years), with a female predominance (78.6%).

Table 2. Comparison of NDI, Nurick, and SF-36 Scores Before and After Surgery.

	NDI	Nurick	SF-36 Physical	SF-36 Mental
Preoperative	35.1	2.9	37.7	47.5
Postoperative	43.6	1.9	35.6	45.5
<i>P</i>	.216	.203	.944	.416

Abbreviation: NDI, Neck Disability Index; mJOA, modified Japanese Orthopaedic Association score; Nurick, the Nurick scale; SF-36, 36-item Short-Form Health Survey.

Indications for surgery included myelopathy ($n = 7$), radiculopathy ($n = 3$), cervical instability ($n = 1$), and metastatic disease ($n = 2$). The mean duration of operative time for cases was 4.7 (± 1.8) hours. VAI was associated with substantial blood loss (770 mL), although only 3 cases (23.1%) required transfusion. An anterior-only approach was utilized in 7 of the 14 cases with VAI, while 3 cases involved a posterior approach, and 4 involved a circumferential approach. For cases utilizing a circumferential approach, it was not specified at which portion of the case vascular injury occurred.

Surgical procedures associated with VAI included multilevel procedures involving C1 through T2 vertebrae. With the information provided, the location of injury as it relates to operative level is known for 11 of the 14 cases of VAI (Table 1). Of the 7 anterior cases involving VAI, 5 (71.4%) utilized a left-sided approach. The procedural stages during which VAI occurred included dissection ($n = 3$), burring ($n = 3$), electrocautery ($n = 1$), and instrumentation (tapping; $n = 1$; Table 1).

Notably, postoperative review of preoperative imaging identified vertebral artery anomalies in 4 of 8 cases (50%) involving VAI. Two of these 4 cases did not employ the use of magnetic resonance imaging (MRI) and were diagnosed with computed tomography (CT). Among the 8 cases of VAI with preoperative imaging that was reviewed postoperatively, 7/8 used CT or CTA while 6/8 used MRI (5/8 cases used both CT/CTA and MRI).

Mean length of hospital stay for VAI patients was 10.2 (± 8.7) days. Of the 14 patients with VAI, 4 (28.6%) received no remedial therapy (which included anticoagulants and physical therapy) while 4 underwent an additional unspecified surgical procedure for VA repair. Only 1 patient (7.1%) required subsequent hospitalization for remedial therapy postinjury, although the nature of the hospitalization or therapy was not detailed. Notably, 13 of the 14 (92.86%) cases resolved without residual deficits. Compared to preoperative baseline NDI, Nurick, and SF-36 physical and mental component scores for these patients, there were no observed changes after surgery ($P = .20-.94$; Table 2), suggesting that patients did not demonstrate symptomatic improvement postoperatively.

Discussion

Vertebral artery injuries are potentially catastrophic complications that can be sustained from either anterior or posterior approaches of the cervical spine. Outcomes can range from

asymptomatic to more serious sequelae including pseudoaneurysm, neurologic deficit, late-onset hemorrhage, infarction, and death.¹⁶⁻¹⁹ Etiologies of iatrogenic VAI include unrecognized anatomical variations and vascular anomalies, choice of approach, and technical error. Risk factors contributing to VAI include a dissection course straying from midline, pathologic softening of bone near the lateral region of the spinal canal, excessive removal of bone and/or disc material, and anomalous VA.^{9,20}

Cadaveric studies demonstrate a 2.7% incidence of an anomalous VA course.⁶ In CT angiogram studies of more than 1000 patients, Hong et al identified 5.4% of study subjects with anomalous V3 segment course⁷ (the *extraspinal segment*; Figure 1). In a retrospective review of 250 MRI scans, Eskander et al describe 3 main groups of VA anomalies: intraforaminal, extraforaminal, and arterial (Table 2).²⁰ The intraforaminal classification describes midline migration of the VA, which the authors suggest may be secondary to degenerative osteoarthritic changes resulting in loss of cervical height and alignment.⁹ In extraforaminal anomaly, the VA does not enter the transverse foramen of C6 and is therefore unprotected, creating potential risk during longus colli retraction or dissection. The third class of VA anomalies include arterial abnormalities such as fenestrated, duplicated, or hypoplastic arteries. A fourth class of VA anomaly involves abnormal bone architecture surrounding the vessel. Ye et al identified an “abnormally large gap” in the proximity of the C1-C2 facet joint, which resulted in inadvertent VA injury during fibrous tissue separation with a pituitary rongeur.²¹ Imaging studies have identified up to 7% of cases of VA injury with observed duplicate transverse foramen.⁴

CTA or MRA may be used to highlight anatomic features including interforaminal distance, spinal canal width, and vessel course. Recent literature has described the use of 3D-CTA for preoperative evaluation of VA blood flow, describing advantages over MRA that include shorter recording time, fewer instrumentation artifacts, less influence of body movements, and the ability to simultaneously visualize the VAs and surrounding osseous structures.^{7,22}

In this multicenter retrospective review, 50% of cases of VAI with available preoperative imaging revealed anomalous variations in the VA during postoperative review. This finding emphasizes the need for vigilant preoperative assessment, especially with regard to vascular anatomy. The value in preoperative identification of arterial anatomic variations cannot be overstated, as knowledge of VA course may alter intraoperative considerations and decision making based on procedural stage and operative level.

Aberrancies of vertebral artery course, if not recognized on preoperative assessment, may present inadvertent intraoperative risk. While definitive clinical protocol may be difficult to establish secondary to the rarity of VAI, a sound understanding of VA anatomy prior to surgery may help prevent injury. Thorough evaluation with CT, MRI, or even advanced 3D CT angiography would be essential during preoperative assessment. Preoperative angiography may prove especially valuable in the context of a displaced, tortuous, or dilated VA.⁹

While VAI resulting from an anterior approach is less common, it most commonly occurs during decompression procedures. In this study, 7 of the 14 cases involving VAI were associated with an anterior-only surgical approach, while in 4, the patients underwent a circumferential surgery. The reported incidence during anterior cervical decompression ranges from 0.3% to 0.5%.^{9,11,15} In a retrospective survey of more than 5600 operations, Neo et al demonstrated an overall VAI incidence of 0.18% associated with anterior cervical decompression.¹⁴ In a cross-sectional study comprising more than 160 000 cervical spine cases performed by members of the Cervical Spine Research Society, Lunardini et al reported the overall incidence of VAI to be 0.07% via a physician survey. Anterior corpectomy comprised 23.4% of cases involving VAIs, while anterior discectomy accounted for 9.0% and 7.2%, respectively.¹²

Instrumented posterior surgery of the upper cervical spine (C3 to occiput) may pose the greatest risk of VAI.^{3,12,23,24} In this study, 3 of the 14 cases involving VAI utilized a posterior surgical approach, although it is not known if instrumentation was used and at which levels. The incidence of VAI during posterior atlantoaxial transarticular screw fixation (Magerl fixation) ranges from 0% to 8.2%.^{9,14,24} In a retrospective survey of 213 members of the American Association of Neurologic Surgeons, Wright and Laurysen reported a 4.1% risk of VAI during C1-2 transarticular screw fixation per patient, or 2.2% risk of injury per inserted screw including both known and suspected cases of VAI.²⁴ These figures underscore the value of preoperative CT of the cervical spine to track the course of vascular structures at this level, and the presence of an anomalous VA would preclude the use of cannulated or noncannulated screws.²⁵ Lunardini et al concluded that posterior instrumentation was the single most common cause of VAI (34.2%) with posterior exposure and posterior foraminotomy accounting for 11.7% and 1.8%, respectively.¹² Circumferential cervical fusions have also been associated with an increased risk of vascular injury.²⁶

In the event of VAI during a cervical procedure, a surgeon must act expeditiously to achieve control of hemorrhage, prevent ischemia and/or infarction, and minimize postoperative risk for embolic complications.^{1,3,27} Park and Jho recommended a regimented list of VA injury management: (1) tamponade with hemostatic agent, (2) direct repair, and (3) postoperative endovascular procedures to prevent delayed complications.⁸ Hemostatic tamponade remains the most important and common definitive management selection initially, using digital pressure followed by hemostatic agents such as Gelfoam (Pfizer), Surgicel (Ethicon), or bone wax.³ Inflatable balloon catheters in the transverse foramen have been used as well to provide an external compression force. However, risks including delayed hemorrhage and fistula formation associated with packing have been reported.⁹ Some studies have described covering the site of vessel injury with a covered stent, which may control hemorrhage while simultaneously preserving vessel patency and cerebral blood supply.^{28,29} Prior limitations of covered stents were attributed

to stiffness and poor navigability of stents that were available for clinical use. Microvascular repair may salvage normal blood flow while minimizing risk of ischemia and impending infarction. Endovascular coiling may be an effective means of hemorrhage control after VAI, but literature regarding its use in the immediate postinjury setting is limited.²⁷ VA ligation, a last resort, is associated with catastrophic morbidities including cerebellar infarction, hemiplegia, and death, especially in the context of a hypoplastic contralateral vessel that is unable to maintain perfusion. Intraoperative angiography can be used for urgent evaluation of an injury site while also highlighting the contralateral VA status.³⁰

Additional treatment options include close observation in asymptomatic patients, heparin anticoagulation, antiplatelet agents, thrombolytics, and endovascular repair. Such therapies should, in theory, reduce the risk of neurologic sequelae from thrombotic phenomena including transient ischemic attacks, lateral medullary syndrome infarcts, and brainstem or posterior cerebral ischemia. However, literature on the efficacy of anticoagulation and antiplatelet therapy is controversial. Biffi et al report a 3-fold increased risk for posterior circulation stroke and 10-fold risk of poor neurologic outcome in VAI patients not treated with heparin.³¹ However, Fasset et al identified significant selection bias and study limitations based on a small subanalysis of patients.¹⁷ Cothren et al reported antithrombotic therapies including systemic heparin, antiplatelet, or low-molecular-weight heparin reduced the risk for ischemic neurologic sequelae following VAI from 21% to 0.05%.³²

This study has several limitations. Based on the reporting inconsistencies between centers, there were a number of data fields that were incomplete such as the exact spinal level, location, and point in the procedure (approach, retraction, instrumentation) in which the VAI occurred (unspecified in some cases). While 1 of the 14 cases incurred residual deficits, information regarding the nature of the deficit and consequent prognosis was not available. With regard to parameters including operative time, estimated blood loss, and length of hospital stay, there were no comparisons via statistical analysis to control patients, thereby posing another limitation. Furthermore, because the threshold for reporting a VAI may differ between institutions, the true incidence offered by this study may be subject to bias.

Conclusion

This work reports the findings of the AOSpine North America Clinical Research Network and its participating institutions in one of the largest multicenter retrospective studies to date involving VAI in cervical spine surgery. This study demonstrates a 0.08% incidence of VAI during cervical spine surgery in 16 582 patients. The data presented are consistent with and further bolsters the consensus that anterior cervical spine surgery is associated with the highest rates of VAI. Advanced imaging techniques are an indispensable part of the preoperative assessment for identifying anatomical risk factors including

anomalous vertebral artery, tortuous vessel course, and medial migration of the artery.

The mean age of patients with VAI was 58.8 years, with a female predominance approaching 80%. Given an aging population with an increasing prevalence of osteoporosis (nearly 54 million men and women in the United States alone), bone quality and anatomic changes related to degenerative disease may predispose a considerable fraction of the population, particularly candidates for cervical spine surgery, to VAI. An awareness and accurate measure of the incidence of VAI may certainly hold value when considering the aforementioned demographic of the population. While the health status of a considerable fraction of patients presenting for cervical spine surgery may preclude invasive imaging techniques, such resources should be utilized when considered appropriate by the vigilant practitioner.

Although VAI outcomes are highly variable, the data from this study suggest that the overwhelming majority of patients recovered without permanent neurologic deficits. Despite this, with a VAI, there remains significant risk of neurologic sequelae and death, and the surgical team must have regimented catastrophic planning in place should this injury occur.

Authors' Note

This study was ethically approved by the institutional ethics committees at all participating sites.

Declaration of Conflicting Interests

The author(s) declared the following potential conflicts of interest with respect to the research, authorship, and/or publication of this article: Wellington K. Hsu reports grants from AOSpine North America, during the conduct of the study, personal fees from Medtronic, personal fees from Stryker, personal fees from Bacterin, personal fees from Graftys, personal fees from Ceramtec, personal fees from Relievent, personal fees from Bioventus, personal fees from Globus, personal fees from SpineSmith, outside the submitted work; Abhishek Kannan, reports grants from AOSpine North America, during the conduct of the study; Michael G. Fehlings reports grants from AOSpine North America, during the conduct of the study; Vincent C. Traynelis reports grants from AOSpine North America during the conduct of the study, Medtronic - Royalties, Consultant Globus - Institutional Fellowship Support; Ziya L. Gokaslan reports grants from AOSpine North America, personal fees from AO Foundation, grants from AOSpine, outside the submitted work; Alan S. Hilibrand reports grants from AOSpine North America during the conduct of the study, other from Amedica, Vertiflex, Benvenue, Lifespine, Paradigm Spine, PSD, Spinal Ventures, outside the submitted work, and in addition, Dr. Hilibrand has a patent Aesculap, Amedica, Biomet, Stryker, Alphatec, with royalties paid; Thomas E. Mroz reports other from AOSpine, during the conduct of the study, personal fees from Stryker, personal fees from Ceramtec, other from Pearl Diver, outside the submitted work; Eric M. Massicotte reports grants from AOSpine North America during the conduct of the study, grants from Medtronic, Depuy-Synthes Spine Canada, personal fees from Watermark Consulting, grants from AOSpine North America, nonfinancial support from AOSpine North America, outside the submitted work; Wilson Z. Ray reports grants from NIH/NINDS, grants from Department of Defense, grants from DARPA, other from Depuy/Synthes,

other from Ulrich, other from Harvest Technologies, outside the submitted work; Michael P. Steinmetz reports grants from AOSpine North America during the conduct of the study; Gabriel A. Smith reports grants from AOSpine North America during the conduct of the study; Jonathan Pace reports grants from AOSpine North America during the conduct of the study; Robert E. Isaacs reports grants from AOSpine North America during the conduct of the study, grants and personal fees from NuVasive, Inc., personal fees from Association for Collaborative Spine research, outside the submitted work; Jeffrey C. Wang reports grants from AOSpine North America during the conduct of the study; Elizabeth L. Lord reports grants from AOSpine North America during the conduct of the study; Zorica Buser reports grants from AOSpine North America during the conduct of the study; and K. Daniel Riew reports personal fees from AOSpine International, other from Global Spine Journal, other from Spine Journal, other from Neurosurgery, personal fees from Multiple Entities for defense, plaintiff, grants from AOSpine, grants from Cerapedics, grants from Medtronic, personal fees from AOSpine, personal fees from NASS, personal fees from Biomet, personal fees from Medtronic, nonfinancial support from Broadwater, outside the submitted work; Paul M. Arnold reports grants from AOSpine North America, during the conduct of the study; other from Z-Plasty, other from Medtronic Sofamore Danek, other from Stryker Spine, other from FzioMed, other from AOSpine North America, other from Life Spine, other from Integra Life, other from Spine Wave, other from MIEMS, other from Cerapedics, other from AOSpine North America, outside the submitted work; Mohamad Bydon reports grants from AOSpine North America during the conduct of the study; Mark Corriveau reports grants from AOSNA during the conduct of the study; Harry T. Mai reports grants from AOSpine North America during the conduct of the study; Ahmad Nassr reports grants from AOSNA from null, during the conduct of the study; Sungho Lee reports grants from AOSpine North America, during the conduct of the study.

Funding

The author(s) disclosed receipt of the following financial support for the research, authorship, and/or publication of this article: This study was sponsored by AOSpine North America Inc, a 501(c)3 nonprofit corporation.

References

- Daniels AH, Riew KD, Yoo JU, et al. Adverse events associated with anterior cervical spine surgery. *J Am Acad Orthop Surg*. 2008;16:729-738.
- Belin EJ, Gelb DE, Koh EY. Complications in cervical spine surgeries. *Semin Spine Surg*. 2014;26:106-113.
- Peng CW, Chou BT, Bendo JA, Spivak JM. Vertebral artery injury in cervical spine surgery: anatomical considerations, management, and preventive measures. *Spine J*. 2009;9:70-76.
- Hong JT, Lee SW, Son BC, et al. Analysis of anatomical variations of bone and vascular structures around the posterior atlantal arch using three-dimensional computed tomography angiography. *J Neurosurg Spine*. 2008;8:230-236.
- Yamazaki M, Okawa A, Furuya T, et al. Anomalous vertebral arteries in the extra- and intraosseous regions of the craniovertebral junction visualized by 3-dimensional computed tomographic angiography: analysis of 100 consecutive surgical cases and review of the literature. *Spine (Phila Pa 1976)*. 2012;37:E1389-E1397.
- Curylo LJ, Mason HC, Bohlman HH, Yoo JU. Tortuous course of the vertebral artery and anterior cervical decompression: a cadaveric and clinical case study. *Spine (Phila Pa 1976)*. 2000;25:2860-2864.
- Hong JT, Park DK, Lee MJ, Kim SW, An HS. Anatomical variations of the vertebral artery segment in the lower cervical spine: analysis by three-dimensional computed tomography angiography. *Spine (Phila Pa 1976)*. 2008;33:2422-2426.
- Park HK, Jho HD. The management of vertebral artery injury in anterior cervical spine operation: a systematic review of published cases. *Eur Spine J*. 2012;21:2475-2485.
- Smith MD, Emery SE, Dudley A, Murray KJ, Leventhal M. Vertebral artery injury during anterior decompression of the cervical spine. A retrospective review of ten patients. *J Bone Joint Surg Br*. 1993;75:410-415.
- Daentzer D, Deinsberger W, Boker DK. Vertebral artery complications in anterior approaches to the cervical spine: report of two cases and review of literature. *Surg Neurol*. 2003;59:300-309.
- Golfinos JG, Dickman CA, Zabramski JM, Sonntag VKH, Spetzler RF. Repair of vertebral artery injury during anterior cervical decompression. *Spine*. 1994;19:2552-2556.
- Lunardini DJ, Eskander MS, Even JL, et al. Vertebral artery injuries in cervical spine surgery. *Spine J*. 2014;14:1520-1525.
- Rampersaud YR, Moro ER, Neary MA, et al. Intraoperative adverse events and related postoperative complications in spine surgery: implications for enhancing patient safety founded on evidence-based protocols. *Spine (Phila Pa 1976)*. 2006;31:1503-1510.
- Neo M, Fujibayashi S, Miyata M, Takemoto M, Nakamura T. Vertebral artery injury during cervical spine surgery: a survey of more than 5600 operations. *Spine (Phila Pa 1976)*. 2008;33:779-785.
- Burke JP, Gerszten PC, Welch WC. Iatrogenic vertebral artery injury during anterior cervical spine surgery. *Spine J*. 2005;5:508-514.
- Tsai YF, Doufas AG, Huang CS, Liou FC, Lin CM. Postoperative coma in a patient with complete basilar syndrome after anterior cervical discectomy. *Can J Anaesth*. 2006;53:202-207.
- Fassett DR, Dailey AT, Vaccaro AR. Vertebral artery injuries associated with cervical spine injuries: a review of the literature. *J Spinal Disord Tech*. 2008;21:252-258.
- Méndez J, González-Llanos F. Endovascular treatment of a vertebral artery pseudoaneurysm following posterior C1-C2 transarticular screw fixation. *Cardiovasc Intervent Radiol*. 2005;28:107-109.
- Cho KH, Shin YS, Yoon SH, Kim SH, Ahn YH, Cho KG. Poor surgical technique in cervical plating leading to vertebral artery injury and brain stem infarction—case report. *Surg Neurol*. 2005;64:221-225.
- Eskander MS, Drew JM, Aubin ME, et al. Vertebral artery anatomy: a review of two hundred fifty magnetic resonance imaging scans. *Spine (Phila Pa 1976)*. 2010;35:2035-2040.
- Ye JY, Ayyash OM, Eskander MS, Kang JD. Control of the vertebral artery from a posterior approach: a technical report. *Spine J*. 2014;14:e37-e41.

22. Sano A, Hirano T, Watanabe K, et al. Preoperative evaluation of the vertebral arteries and posterior portion of the circle of Willis for cervical spine surgery using 3-dimensional computed tomography angiography. *Spine (Phila Pa 1976)*. 2013;38:E960-E967.
23. Cole T, Veeravagu A, Zhang M, Azad TD, Desai A, Ratliff JK. Anterior versus posterior approach for multilevel degenerative cervical disease: a retrospective propensity score-matched study of the MarketScan database. *Spine (Phila Pa 1976)*. 2015;40:1033-1038.
24. Wright NM, Laurysen C. Vertebral artery injury in C1-2 transarticular screw fixation: results of a survey of the AANS/CNS Section on Disorders of the Spine and Peripheral Nerves. American Association of Neurological Surgeons/Congress of Neurological Surgeons. *J Neurosurg*. 1998;88:634-640.
25. Hsu WK. Advanced techniques in cervical spine surgery. *Instr Course Lect*. 2012;61:441-450.
26. Marquez-Lara A, Nandyala SV, Hassanzadeh H, Noureldin M, Sankaranarayanan S, Singh K. Sentinel events in cervical spine surgery. *Spine (Phila Pa 1976)*. 2014;39:715-720.
27. Schroeder GD, Hsu WK. Vertebral artery injuries in cervical spine surgery. *Surg Neurol Int*. 2013;4:S362-S367.
28. Waldman DL, Barquist E, Poynton FG, Numaguchi Y. Stent graft of a traumatic vertebral artery injury: case report. *J Trauma*. 1998;44:1094-1097.
29. Katsaridis V, Papagiannaki C, Violaris C. Treatment of an iatrogenic vertebral artery laceration with the Symbiot self-expandable covered stent. *Clin Neurol Neurosurg*. 2007;109:512-515.
30. Jung HJ, Kim DM, Kim SW, Lee SM. Emergent endovascular embolization for iatrogenic vertebral artery injury during cervical discectomy and fusion. *J Korean Neurosurg Soc*. 2011;50:520-522.
31. Biffi WL, Moore EE, Elliott JP, et al. The devastating potential of blunt vertebral arterial injuries. *Ann Surg*. 2000;231:672-681.
32. Cothren CC, Moore EE, Ray CE Jr, et al. Screening for blunt cerebrovascular injuries is cost-effective. *Am J Surg*. 2005;190:845-849.