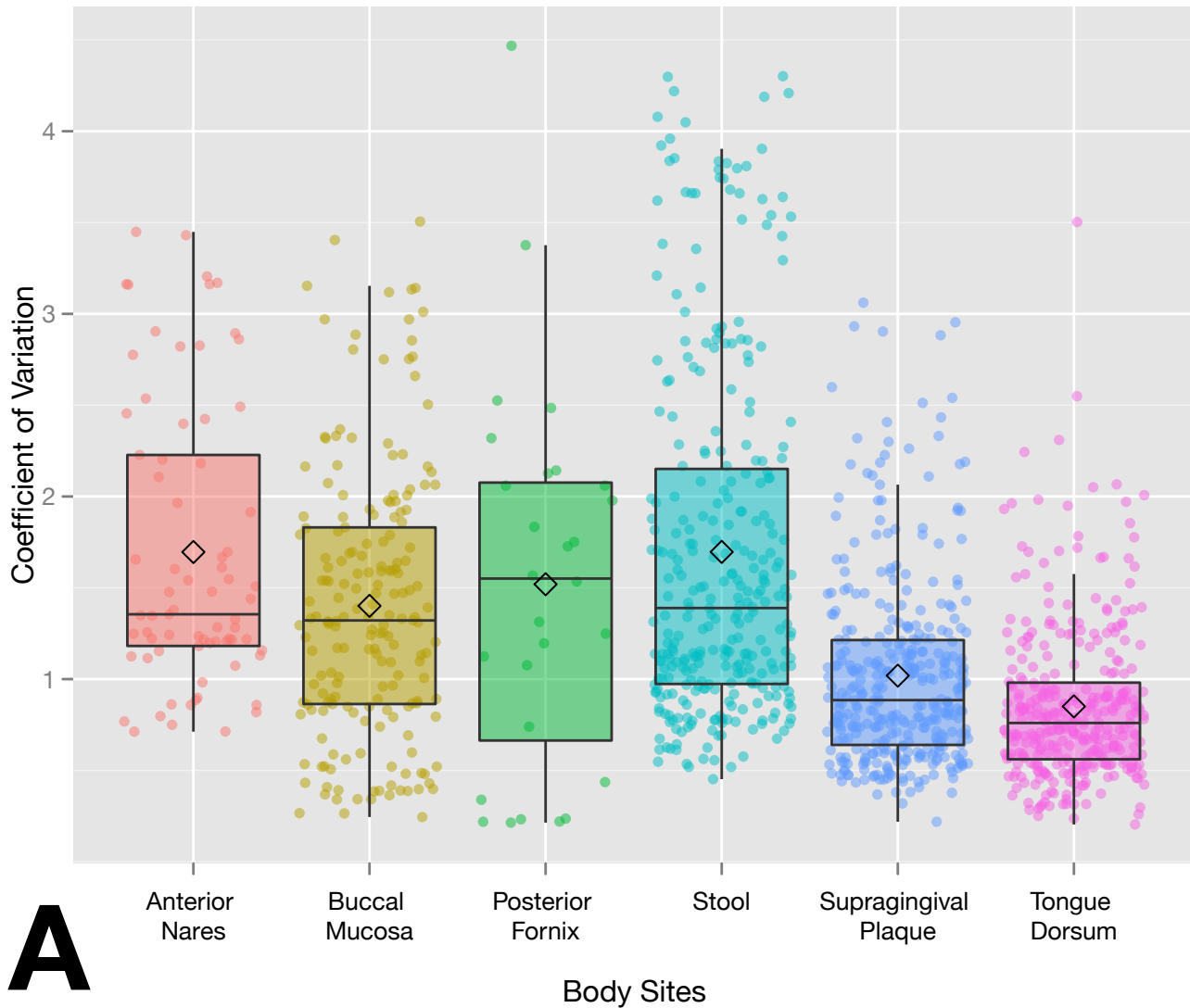


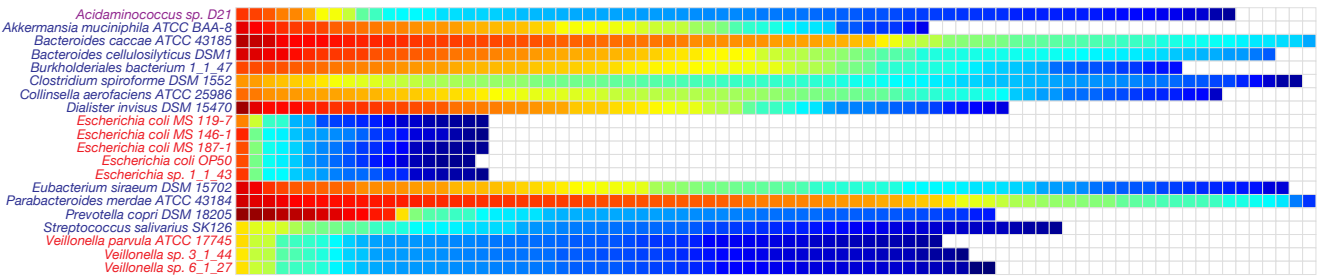
Buccal Mucosa



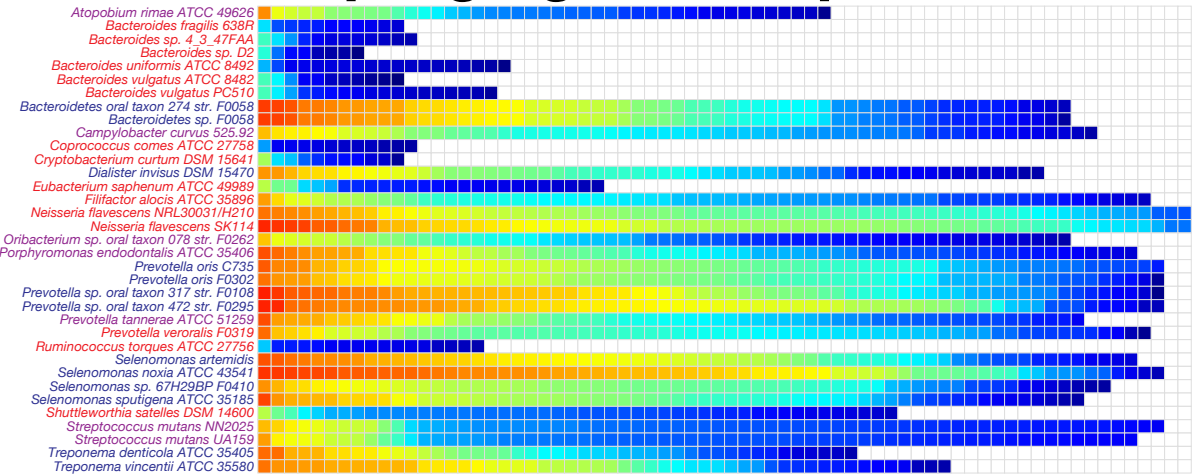
Posterior Fornix



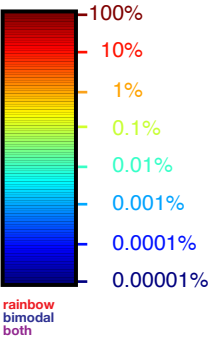
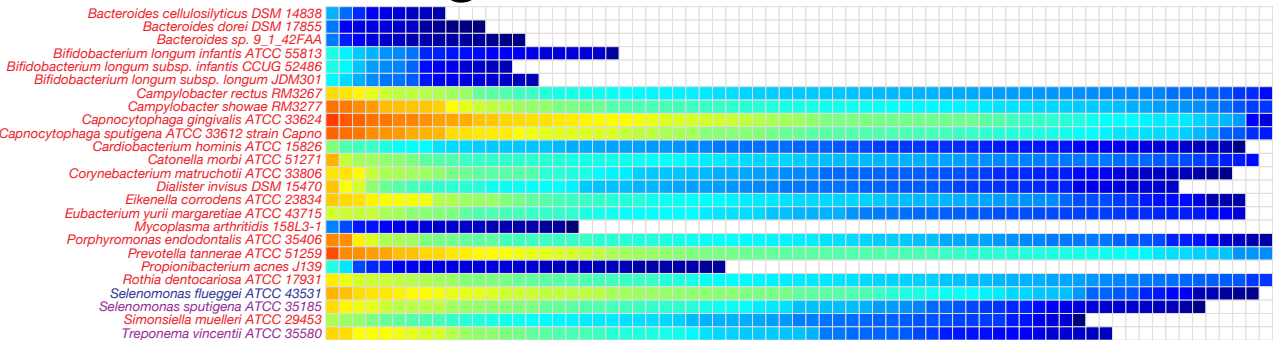
Stool



Supragingival Plaque



Tongue Dorsum



B